

Treating acute sinusitis

Peter John Wormald, Professor and Head, Department of Otolaryngology Head and Neck Surgery, University of Adelaide and Flinders University, Adelaide

SYNOPSIS

Infections in the nose involve the sinuses because the lining of the nose and the paranasal sinuses is continuous. The major sinuses drain through a common tract – the ostiomeatal complex, which is located under the middle turbinate. Acute sinusitis usually follows a cold and presents with nasal obstruction, facial pain, dental pain, purulent rhinorrhoea, sinus tenderness and in some cases fever and malaise. The diagnosis is made on the history, the patient's lack of response to topical decongestants and on finding pus in the nose with associated sinus tenderness. Treatment consists of combining topical or systemic decongestants with saline irrigations and an antibiotic, usually amoxicillin. Referral to a specialist should be considered if patients fail to respond to second line antibiotic therapy and for those who get recurrent episodes of sinusitis.

Index words: decongestants, rhinitis, rhinosinusitis.

(*Aust Prescr* 2000;23:39–42)

Introduction

The lining of the nose and the paranasal sinuses is continuous and inflammation which affects the lining of the nose will spread, to a variable extent, into the sinuses (Fig. 1). An inflammatory process that is primarily sited in the sinuses will in turn extend to the nasal cavity and result in a variable amount of rhinitis. Most conditions in the nose therefore affect both the nasal cavity and the sinuses (rhinosinusitis). Acute sinusitis is defined as an infection of the nose which has spread to the paranasal sinuses, with a duration of between one day and three weeks. Chronic sinusitis is defined as a patient having two or more of the symptoms of nasal obstruction, rhinorrhoea, facial pain or headache or anosmia for longer than three months. The treatment of chronic sinusitis is different from that of acute sinusitis.

Anatomy

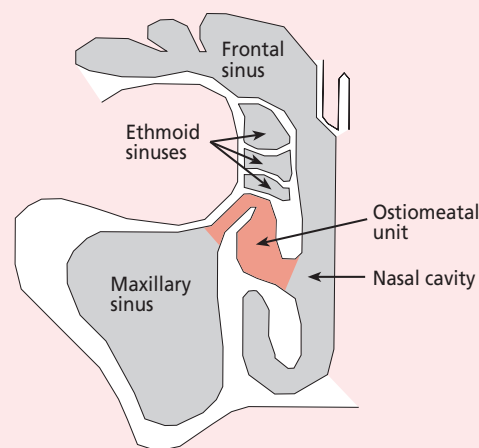
The paranasal sinuses consist of four pairs of sinuses. These are the maxillary, frontal, ethmoid and sphenoid sinuses (Fig. 1). The maxillary, frontal and anterior ethmoid sinuses open into the ostiomeatal unit under the middle turbinate while the posterior ethmoid and sphenoid sinuses open into the superior meatus above the middle turbinate.

The nose and sinuses are lined by pseudostratified columnar epithelium similar to that in the lower respiratory tract. This epithelium is covered by a mucous blanket which is made up of two layers: the liquid layer in which the cilia move (the sol layer) and a thin more viscous layer (the gel layer)

Fig. 1

The epithelium lining the nasal cavity and the sinuses is continuous. Infections of the nose will usually affect the sinuses to some degree and infections of the sinuses will affect the nose. (The sphenoid sinus is not shown.)

The ostiomeatal unit is the final common pathway for muco-ciliary drainage of the maxillary, frontal and anterior ethmoid sinuses.



which is moved by the cilia. Inhaled particles normally adhere to the gel layer and are moved out of the sinuses and nose to the nasopharynx before being swallowed. The health of the nose and paranasal sinuses is primarily dependent on this self-cleaning action of the mucociliary pathways. In the sinuses these pathways always lead towards the ostiomeatal unit. Blockage of the ostia results in sinus disease.

Prevalence

Symptoms of rhinosinusitis are prevalent in 16% of the general population.^{1,2} Acute sinusitis accounts for up to 4.6% of consultations with young adults.³ Approximately 0.5% of common colds are complicated by sinusitis and the average number of colds for an adult per year is 2–3, so many patients will present with signs and symptoms of sinusitis.

Pathogenesis of acute sinusitis

Acute sinusitis usually follows an acute upper respiratory tract infection (common cold). As the viral infection spreads in the nasal mucosa, swelling and oedema of the mucosa results. As the mucosal surfaces of the ostiomeatal unit are in close proximity to one another (Fig. 1), obstruction of the sinus ostia results. In addition, the viral infection may reduce normal

ciliary motility. This prevents normal mucociliary clearance resulting in an accumulation of mucus in the sinuses and the development of the symptoms of sinusitis. If this mucus becomes secondarily infected by bacteria, acute bacterial sinusitis develops.

Diagnosis

The symptoms and signs of acute sinusitis are nasal obstruction, facial pain, dental pain, purulent rhinorrhoea, sinus tenderness and in some cases systemic manifestations such as fever and malaise. A review of the literature found that the most sensitive symptoms and signs for the diagnosis of acute sinusitis were maxillary toothache, a poor response to decongestants, a coloured nasal discharge (symptoms), purulent nasal discharge and abnormal maxillary sinus transillumination (signs).⁴ One of the common problems facing the doctor is differentiating an acute upper respiratory tract infection (the common cold) from acute sinusitis as there is considerable overlap of the symptoms and signs (Table 1).

The gold standard for the diagnosis of acute bacterial sinusitis remains aspiration of pus from one of the major sinuses. As the maxillary sinuses are the most accessible to aspiration and also the most commonly involved sinus in acute sinusitis, they were the most commonly aspirated sinuses. Nowadays maxillary sinus puncture and aspiration is seldom performed as the procedure can be painful.

Examination

After taking the history, the next step is to perform anterior rhinoscopy. In the normal nasal cavity, a patent nasal airway and the normal inferior and middle turbinates can be seen (Fig. 2). Note the lining of the nose is not inflamed or oedematous and there is no intranasal discharge. In the case of the common cold, the lining of the nose is erythematous and oedematous and there are clear or pale yellow nasal secretions (Fig. 3). In patients with acute sinusitis, often all that can be seen is copious yellow or green nasal discharge (Fig. 4). If this is cleared, the underlying nasal mucosa is erythematous and oedematous.

Frontal sinus or maxillary sinus tenderness is checked by tapping over the forehead just above the eyebrows or on the cheeks below the eyes. Pressure can also be applied in the roof of the orbit, which is the floor of the frontal sinus. The other sinuses are inaccessible for the examination of tenderness.

Maxillary sinus transillumination is not commonly used as it requires experienced personnel and a completely darkened room. Only a negative finding (i.e. normal transillumination) is useful. The light is held on the lower rim of the orbit and the palate examined through the patient's open mouth. The palate lights up with normal transillumination.

Fig. 2

Normal inferior turbinate with middle turbinate just visible in the distance

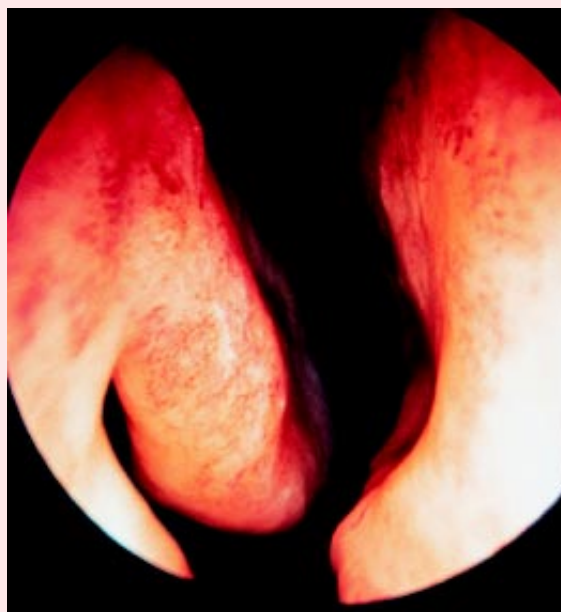


Fig. 3

Mucus coming from the ostiomeatal unit under the middle turbinate

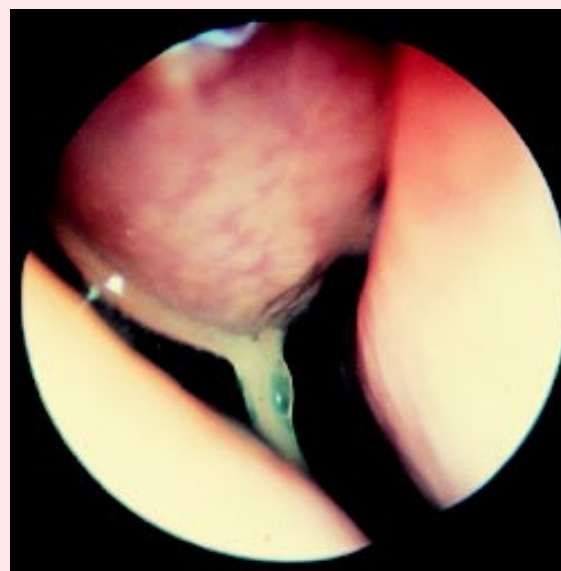


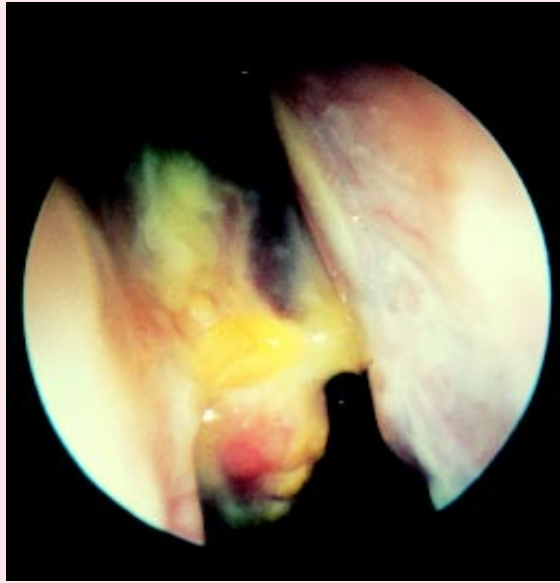
Table 1

Similarities and differences between the common cold and acute sinusitis

Symptoms & signs	Common cold	Acute sinusitis
Nasal obstruction	+++	+++
Rhinorrhoea (clear or pale yellow)	++++	±
Facial pressure	++	++++ (especially when bending forward)
Poor response to topical decongestants	-	++
Purulent rhinorrhoea (yellow/green)	-	+++
Facial pain	-	+++
Dental pain	-	+
Sinus tenderness	-	++
Fever	-	+

Fig. 4

Thick mucopus from the ostiomeatal unit lying on the anterior end of the middle turbinate



Investigation

When the patient has all the clinical features the diagnosis of acute sinusitis is clear. It is also usually quite clear when the patient does not have acute sinusitis if only one symptom or sign, or none, is present. However, the difficulty in the diagnosis of acute sinusitis comes when there are two or three symptoms and signs present. In these patients plain x-rays of the sinuses can be useful. A Waters (straight anteroposterior) view of the skull will allow the maxillary sinuses to be evaluated while a Caldwell (occipitomeatal) view will allow evaluation of the frontal sinuses. Lateral x-rays can help evaluate the sphenoid sinuses. The patient should be upright in all radiographs so that air-fluid levels can be seen. As the maxillary sinuses are involved in nearly 90% of patients with acute sinusitis, a single Waters view may be all that is required to confirm the diagnosis of acute sinusitis.⁴ If this is inconclusive the other views may be added.

Microbiology

Acute sinusitis is thought to be caused by the secondary bacterial invasion of inflamed sinuses that can occur in an acute viral upper respiratory tract infection. However, the presence of bacteria in the sinuses can only be confirmed by direct aspiration of the sinus. This is only possible in the maxillary sinus and can only be done with some discomfort to the patient.

The most commonly involved organisms are *Haemophilus influenzae* and *Streptococcus pneumoniae*. Other organisms involved include other streptococci, anaerobes, *Moraxella catarrhalis* and *Staphylococcus aureus*.⁵ Beta-lactamase production by *Haemophilus influenzae* has dramatically increased over the last 15 years and is found in up to 50% of organisms in certain areas of the world.⁵

Treatment

There are no good data on the treatment of sinusitis. Common practice includes decongestants which shrink the nasal mucosal oedema and help open the natural ostia of the sinuses and allow re-aeration and muco-ciliary drainage. For example oxymetazoline 0.5% in the form of a nasal spray gives good nasal mucosal decongestion with symptomatic relief. In addition, irrigation of the nose with normal saline nasal spray has also been found to improve symptomatology and outcome. Antihistamines, topical and systemic steroids have not been shown to give any additional benefit.

The use of antibiotics to treat all suspected cases of acute sinusitis is controversial. Many of the studies have had conflicting results. In general practice it can be difficult to be certain that the patient's symptoms are caused by sinusitis. If the diagnostic criteria are strict, acute bacterial sinusitis should be treated with antibiotics as they are significantly more effective than placebo alone.⁶ Amoxicillin is still considered first-line treatment. The adult dose is amoxicillin 500 mg three times a day for a period of between 10 and 14 days.⁷ Patients allergic to penicillin should be treated with either trimethoprim-sulfamethoxazole or cefaclor. Should the patient fail to respond to this regimen, second line therapy should be selected from an amoxicillin-clavulanate combination, cefaclor, cefuroxime axetil, loracarbef or cefixime.

Surgical intervention

This is usually only considered if complications of acute sinusitis develop. These include periorbital cellulitis, intra-orbital abscesses, osteitis or intracranial sepsis. Surgery would include drainage of affected sinuses plus management of the complication.

Specialist referral

Most cases of acute sinusitis can be managed by the general practitioner. However, referral should occur if complications develop or if the patient fails to respond to second-line therapy. Referral should also be made for patients with recurrent acute sinusitis.

The specialist will perform nasal endoscopy with a rigid nasal telescope to confirm the presence of pus in the middle meatus and/or sphenoidal recess. An endoscopically guided pus swab will be taken for culture and sensitivity. This will guide further antibiotic therapy. In addition to the antibiotics, a history of possible contributing factors such as allergy will be sought. If tests confirm the presence of an allergy, additional therapy will be needed. If the patient still fails to respond, a CT scan of the sinuses will be performed and endoscopic sinus surgery may be offered to the patient.

REFERENCES

1. Jones NS. Rhinosinusitis. British Association of Otorhinolaryngologists Head and Neck Surgeons; Aug 1998. <http://www.orl-baohns.org/members/clinframe.html>
2. Sibbald B, Rink E. Epidemiology of seasonal and perennial rhinitis: clinical presentation and medical history. *Thorax* 1991;46:895-901.
3. Norrby R. Clinical aspects on bacterial infections in the upper respiratory tract. *Scand J Infect Dis* 1983;39(Suppl):14-8.

- Stafford CT. The clinician's view of sinusitis. *Otolaryngol Head Neck Surg* 1990;103:870-4.
- Gwaltney JM Jr, Scheld WM, Sande MA, Sydnor A. The microbial etiology and antimicrobial therapy of adults with acute community-acquired sinusitis: a fifteen-year experience at the University of Virginia and review of other selected studies (review). *J Allergy Clin Immunol* 1992;90:457-61.
- Lindbaek M, Hjortdahl P, Johnsen UL-H. Randomised, double blind, placebo controlled trial of penicillin V and amoxicillin in treatment of acute sinus infections in adults. *Br Med J* 1996;313:325-9.
- Casiano RR. Azithromycin and amoxicillin in the treatment of acute maxillary sinusitis. *Am J Med* 1991;91(suppl):27S-30S.

Self-test questions

The following statements are either true or false (answers on page 47)

- Amoxicillin is the drug of first choice for patients with sinusitis who are not sensitive to penicillin.
- Antihistamines have a significant effect on the symptoms of acute bacterial sinusitis.

Book review

Cancer facts: a concise oncology text
Edited by James F. Bishop. London: Harwood Academic Publishers; 1999. 411 pages.
Price \$65.00 soft cover; \$120.00 hard cover

Ian Kerridge, Hunter Haematology Unit, Mater Misericordiae Hospital, Newcastle, NSW

Approximately 25–30% of the Australian population will die from cancer or its various complications and one in four will be diagnosed with cancer by age 75. An understanding of the basics of clinical oncology and of the impact of the major scientific advances in oncology is therefore of critical importance to all practising clinicians. For not only must clinicians suspect, investigate, diagnose and manage cancer – they must also transmit accurate information to patients and their carers in a respectful, empathic and collaborative manner.

Cancer facts is a concise text written by 55 experts in the field, collated and edited by an international authority in clinical and academic oncology. The stated objective of the text is to provide a concise but comprehensive summary of the essentials of oncology and cancer management.

In general terms the text succeeds admirably in achieving its stated aim and provides an accessible, clinically relevant overview of clinical oncology and the related sciences. The book comprises 62 chapters divided into 14 parts covering symptom control and quality of life, lung cancer, breast cancer, gastrointestinal cancer, urogenital cancers, gynaecological cancers, head and neck cancers, melanoma, haematological malignancies, miscellaneous cancers, complications in cancer patients and psychosocial issues in cancer. Each chapter provides an evidence-based synopsis of the field and includes a reading list designed to allow wider, more detailed reading on the essential elements of each chapter.

Cancer facts provides an overview of an extremely broad and complex area of medicine and as such is more likely to be of benefit to the non-oncologist than the specialist oncologist. The structure of the text is generally clear and consistent, but at times seems to be determined more by the organisation of medical specialties than by the need to provide a precise,

coherent integration of cancer management. One must wonder whether having separate chapters on the surgical, radiation and chemotherapy management of non-small cell lung cancer would be more ambiguous or confusing to the non-oncologist than a single chapter on non-small cell lung cancer written collaboratively by a radiation oncologist, medical oncologist and surgeon.

The book concludes with nine colour plates of skin cancers, an essential part of any substantive review of cutaneous malignancies. However, aside from a single mammogram, there are no colour illustrations, reproductions of medical imaging or diagrams to help readers gain an understanding of anatomy, pathology or staging. As with all similar multi-authored texts, there is some unevenness in the quality and referencing of the chapters, and inevitably there will be questions raised about those topics omitted from the text. Research and clinical ethics, patient education resources, evidence-based medicine, decision-analysis, oncology on the internet and environmental/occupational oncology could all arguably be included within an expanded text.

For the most part, however, these are minor objections and *Cancer facts* is likely to find a valued place in many doctors' library or desk. James Bishop has taken on an ambitious task and his text is highly recommended for all oncologists and non-oncologists, be they students, trainees or practising clinicians.

Australian Prescriber web site news

The full text of each issue is now available in PDF format as well as in HTML. This means you can now read and print *Australian Prescriber* exactly as it appears in the printed copy. Click on 'print version' for individual articles or the full issue. PDF format is not available for issues prior to December 1999.