



AN EVALUATION OF ELASTIC AND OXYTALAN STAINING FIBRES  
IN THE TEMPOROMANDIBULAR JOINT AND KNEE JOINT  
OF THE RABBIT

LESTER MILTON DUTHY, B.D.S., F.R.A.C.D.S.

Department of Dental Health  
The University of Adelaide,  
Adelaide, South Australia, 5001.

November 1972

## CONTENTS

	<u>Page</u>
Summary	i
Signed statement	iii
Acknowledgements	iv
Introduction	v
Aims of the investigation	vii
I      LITERATURE REVIEW	1
oxytalan fibres	1
elastic fibres	8
temporomandibular and other synovial joints	11
articular surfaces	12
articular disc	17
joint capsule	22
ligaments, tendons and muscles related to joints	24
II     MATERIAL AND METHODS	28
selection of animals	28
removal of joints	28
fixation	29
decalcification	29
processing	29
blocking	29
cutting	30
staining	30
photomicrography	32
criteria for calling a fibre oxytalan	33

	<u>Page</u>
III      RESULTS.....TEMPOROMANDIBULAR JOINT	37
gross (static) anatomy	37
functional anatomy	43
histologic anatomy	45
bony surfaces	52
articular disc	70
joint capsule	78
IV      RESULTS.....KNEE JOINT	101
bony articular surfaces	106
articular discs	112
joint capsule	121
intra-articular ligaments	129
extra-articular ligaments	135
tendons	143
periosteum	147
patella	152
V      RESULTS.....ENZYMATIC HYDROLYSIS	157
temporomandibular joint	157
condyle surface	158
articular disc	160
joint capsule	162
knee joint	164
intra-articular ligament	164
extra-articular ligament	166
tendon	168

	<u>Page</u>
VI DISCUSSION	171
temporomandibular joint	171
movements of the joint	171
structural importance of the articular disc	172
the significance of oxytalan fibres	176
knee joint	178
elastic fibres	178
oxytalan fibres	179
comparison of the fibres from the temporo- mandibular and knee joints	180
 APPENDIX	
VII.1 Decalcification solution	182
VII.2 Method of processing tissue	183
VII.3 Staining with Aldehyde Fuchsin	184
VII.4 Staining with Orcein	185
VII.5 Method of Enzymatic Digestion	186
 REFERENCES	187

SUMMARY

The temporomandibular and knee joints of five rabbits were examined for the presence and distribution of elastic and oxytalan connective tissue fibres.

Histochemical staining methods and enzyme hydrolysis reactions were used to identify each fibre type.

Elastic fibres were found in the loose connective tissue structures of both types of articulation. In these locations they are associated with tissues which undergo a controlled reversible deformation when subjected to functional forces. Elastic fibres were also located in certain dense connective tissues of the knee joint. In these structures, however, their numbers were generally minimal.

Oxytalan fibres occurred in the tissues of both the temporomandibular and knee joints. Large numbers of the fibres were located in dense, poorly vascularised, connective tissue that contained little or no elastic fibres. Oxytalan fibres generally had a definite functional arrangement when present in structures subjected to loading. It is hypothesised that their main function may be to reinforce the existing collagen bundles of dense connective tissue to resist permanent deformation. In addition, the fibres could provide a degree of additional strength and resiliency to tissue that is relatively inelastic.

The inter-articular disc of the temporomandibular joint contained numerous oxytalan-staining elements that were not arranged in a manner

orientated to withstand functional forces. In this location it is postulated that the fibres may have a different function, and a possible nutritive role has been suggested.

The findings of this investigation provide additional support for Fullmer's hypothesis that oxytalan fibres occur in tissues subjected to stress. Moreover, the location of oxytalan fibres within the rabbit temporomandibular joint, in addition to certain anatomical considerations, suggests that this articulation is a weight bearing structure during function.

SIGNED STATEMENT

This project report is submitted in partial fulfilment of the requirements of the Degree of Master of Dental Surgery in The University of Adelaide.

The report contains no material which has been accepted for the award of any other degree or diploma in any University. To the best of my knowledge and belief, it contains no material previously published or written by another person except when due reference is made in the text of the report.

LESTER MILTON DUTHY

ACKNOWLEDGEMENTS

I am extremely grateful to Dr. M.R. Sims, Reader in Orthodontics, for his constructive criticism and supervision of this research report.

I recognise with gratitude the assistance provided by Dr. J.A. Cran, Head of the Department of Oral Pathology and Oral Surgery, for making available the facilities of the Department.

Mrs. I. Zaleski gave valued photographic suggestions, and Mrs. P. Berry typed the final manuscript; to these people I extend my sincere appreciation.

Finally, I wish to thank my wife for her understanding and support during the period of my research programme.

## INTRODUCTION

---

In 1958 H.M. FULLMER first reported the presence of a new fibre type in connective tissue which he named 'oxytalan' because of its acid resistant properties in contrast to collagen. Oxytalan fibres were distinguished from elastic fibres by a special staining technique which necessitated the prior oxidation of tissue sections before they could be demonstrated with certain elastic stains. Following further studies of human and animal material (FULLMER 1965,1966) he concluded that oxytalan fibres were located in regions of connective tissue subjected to functional stresses.

Subsequently CARMICHAEL and OAKES (1970) reported the presence of oxytalan fibres in the periarticular tissues of the rat temporomandibular joint. However, no description was provided of fibre location and distribution in that structure.

This investigation has been undertaken to re-evaluate and extend the work of Carmichael and Oakes using material from the temporomandibular and knee joints of the rabbit.

A preliminary study comparing the temporomandibular joints from rabbits and domestic cats was undertaken to determine the relationship of elastic and oxytalan fibres in different functional forms of the joint. Elastic fibres were present in the articular structures of both species; however, only the rabbit joint contained oxytalan staining elements. The comparative anatomical findings observed in

the initial study suggested that the joint of the domestic cat may be non-stress bearing, while that of the rabbit is adapted to bear pressure during jaw movements. The presence of oxytalan in the rabbit temporomandibular joint therefore supported Fullmer's original hypothesis that the fibre is found in regions of connective tissue subjected to stress.

The significance of these findings will be considered in more detail during this investigation.

## AIMS OF THE INVESTIGATION

---

1. Confirm the presence of oxytalan and elastic fibres in the structures comprising the temporomandibular joint of the rabbit.
2. Study the location and orientation of oxytalan and elastic fibres found in the temporomandibular joint.
3. Examine the knee joint of the rabbit for the presence of oxytalan and elastic fibres.
4. Compare the distribution of oxytalan and elastic fibres of the temporomandibular and knee joints.
5. In view of Fullmer's hypothesis that oxytalan fibres are found in areas of stress; to evaluate the rabbit temporomandibular joint as a possible weight-bearing structure during function.

OXYTALAN FIBRES

elastic fibres

temporomandibular and other synovial joints

OXYTALAN FIBRES

FULLMER (1958) first reported a new type of fibre in locations previously believed to contain predominantly collagen. The fibres were demonstrated by an aldehyde fuchsin staining technique after prior oxidation with peracetic acid. He found them in human periodontal membrane, tendons, ligaments, adventitia of blood vessels, sheaths of hair follicles and in the epineurium and perineurium of nerves. They were observed to run in the same general direction as the collagen bundles and were also present in certain connective tissues of mice, rats, guinea pigs, monkeys and turkeys. He postulated that these new fibres, which were subsequently named 'oxytalan', might be a form of collagen which develops in areas of stress.

FULLMER and LILLIE (1958) outlined the investigations which led to oxytalan being established as a separate connective tissue fibre distinct from other connective tissue elements. Because of the resistance of the fibre to acid hydrolysis its name was derived from the Greek words meaning 'acid-enduring'. They suggested that on the basis of its staining properties and enzymatic hydrolysis

reactions oxytalan could be distinguished from other connective tissue fibres.

FULLMER (1959a) described the formation and development of oxytalan fibres in the periodontium of humans using foetal and adult material. Various staining methods were used as the basis for this study. Oxytalan staining fibres first appeared in the oral mucosa of embryos at six months, and seemed to develop from condensations of mucopolysaccharide between collagen bundles. He observed that the fibres increased in size and orientated themselves with further development of the periodontium. Once teeth erupted and were subjected to occlusal forces there was a considerable increase in size of the oxytalan fibres in the trans-septal region of the tooth's attachment. Fullmer stated, *"... It is tempting to postulate that stress placed upon the fibres is primarily responsible for the increase in size of the fibres."*

FULLMER (1960a) published the results of a comparative study of the oxytalan fibre in the periodontium of several mammals. The aim of the study was to observe the relationship of oxytalan to elastic and other fibres of the connective tissues. Staining methods and enzymatic reactions were used for differentiating the various fibre types. The results appeared to support a revised concept that the oxytalan fibre was either an incompletely developed or a specially modified elastic fibre. The ratio of oxytalan to elastic fibres was found to vary according to the species, the tooth type and the location about the tooth. It was noted that all

the pre-elastic fibres stained well with the oxytalan fibre stains and could not be distinguished from oxytalan by histochemical methods. Fullmer argued that since oxytalan fibres occurred in connective tissues requiring little or no elasticity, the development of elastic tissue in these sites might actually be detrimental to proper function. He therefore proposed that a different type of elastic structure was produced in those situations. He recommended, "... that the term oxytalan be used to designate elastic-like fibres in certain structures that in the adult state never develop into characteristic elastic fibres; and the term pre-elastic to either developing elastic tissue in structures in which it can be expected to undergo maturation into characteristic elastic fibres, or to extensions of recognisable elastic fibres."

FULLMER (1960b) reported the presence of oxytalan fibres in radicular cysts and dental granulomas. He suggested that the presence of the fibres in lesions involving the jaws would seem to indicate the periodontal origin of the connective tissue cells which produced them.

FULLMER (1961) examined the maxillary alveolar processes of 135 cadavers and found that oxytalan fibres generally tended to be larger and more numerous in functional than in non-functional periodontal ligaments surrounding molar teeth.

FISHER and FULLMER (1962) and FULLMER and WITTE (1962) published further reports on the presence of oxytalan fibres in other pathological states involving the jaws, such as ameloblastoma and scleroderma.

KOHL and ZANDER (1962) observed the distribution of oxytalan fibres in the periodontium of the monkey and noted that they travelled in close relation to both blood and lymphatic channels.

RANNIE (1963) introduced an improved method of oxidation of tissue sections using a potassium monopersulphate bleach in place of the original peracetic acid. Material of human, monkey and rat origin was used in the investigation. He confirmed the findings of Fullmer and suggested that oxytalan fibres might function in the periodontium to prevent overstretching of the tissues and so prevent ischaemia due to obliteration of the vascular channels. Additionally, the fibre was thought to provide added strength to the periodontal ligament.

LÖE and NUKI (1964) studied the periodontium of several animal species and concluded that the oxytalan positive structures were normal components of the tissue. On the basis of their origin, course, morphology and argyrophillic properties the authors deduced that these special staining fibres might be neural elements.

FULLMER (1965,1966) summarised the results of additional histochemical, enzymatic and comparative studies of the periodontium. He concluded that the precise relationship of elastic to oxytalan fibres had not been definitely established. However, histochemical reactions for pre-elastic and oxytalan fibres had given identical results. He therefore proposed that oxytalan fibres in the periodontium of man might represent elastic-type fibres produced by the connective tissue cells in that structure. This opinion was based on the view that connective tissue cells produced different

types of elastic or elastic-like tissue at different locations throughout the body.

CARMICHAEL and FULLMER (1966) reported an electron microscopic study of the oxytalan fibre in the periodontal ligament of the rat. They concluded that the ultrastructural features of the fibres were in many respects similar to those of elastic tissue.

GREENLEE, ROSS and HARTMAN (1966) examined the fine structure of elastic fibres and commented on the similarity between the immature elastic fibres they observed and the ultrastructural features of oxytalan fibres described by Carmichael and Fullmer.

GOGGINS (1966) studied the distribution of oxytalan fibres in the periodontium of primary teeth. He found that they were mainly arranged in a manner similar to that found in the periodontium of adult jaws. On the basis of their staining properties, morphology and distribution he stated that oxytalan fibres were connective tissue and not nervous elements.

SOULE (1967) described the presence of oxytalan fibres in the periodontal ligament of the alligator and caiman which represented lower vertebrate forms. He noted that the fibres were relatively fewer in number in teeth which had continuous replacement throughout life. Furthermore, the fibres were not seen until the developing tooth actually came into function. Soule concluded that his findings lent support to Fullmer's original assumption that oxytalan fibres appeared in regions of stress.

CARMICHAEL (1968) stated that the function of the oxytalan fibre

was not entirely clear. From an investigation of the periodontium in a mouse he described the distribution of oxytalan fibres. He concluded that they might be concerned with the stability of the periodontal vessels since, "... The insertion of oxytalan fibres into the cementum implies an anchorage for the vessels which might permit them to accommodate themselves to distortional and compressive strains."

EDWARDS (1968) observed an increase in size and number of oxytalan fibres in the crestal region of the periodontium of dogs during orthodontic tooth movement. He stated that there was little real evidence concerning the function of these fibres, and suggested that they might have some anchoring effect which would prevent overstretching of the tissue in certain areas.

BOESE (1969) concluded that oxytalan fibres played a role in the relapse of orthodontically rotated teeth. He postulated that the stress produced in the periodontal ligament when a tooth is rotated coincided with an increase in the number of oxytalan fibres. Apparently the fibres maintained their tension by stretching rather than permanently increasing their length.

EDWARDS (1970) investigated tooth movement in human subjects and found that severing all the crestal fibres surrounding a tooth resulted in negligible rotational relapse.

CARMICHAEL and OAKES (1970) reported in an abstract publication that the periarticular tissues of the rat temporomandibular joint contained both elastic and oxytalan-like fibres. A detailed report of their findings was not provided and no further information has

been published in the literature. A personal communication with Carmichael (1971) did not provide any additional details on the location and distribution of these fibres in the temporomandibular joint.

## LITERATURE REVIEW

oxytalan fibres

ELASTIC FIBRES

temporomandibular and other synovial joints

ELASTIC FIBRES

FULLMER (1958) reported that elastic fibres were distinguished from oxytalan fibres on the basis of certain histochemical staining tests.

FULLMER and LILLIE (1958) published the staining reactions of elastic and oxytalan fibres. Their results are represented in the following condensed form :

Reactions	Oxytalan	Elastin
<u>Stained directly</u>		
The 5 elastin stains	-	+
<u>Peracetic acid oxidised</u>		
Orcein	Brown*	Brown
Aldehyde fuchsin	Purple	Purple
Resorcin fuchsin	Purple*	Purple
Verhoeff's stain	-	Black
Orcinol-new fuchsin	-	Purple

\*Some fibres are reactive, others are not.

FULLMER (1965) reviewed the research on oxytalan fibres and presented the evidence which in his view related them to elastic fibres. His criteria are summarised by the following points :

1. Some animals have elastic fibres in their periodontal ligaments with a morphology and distribution analogous to oxytalan fibres in man.
2. In those animals where both elastic and oxytalan fibres are present in the periodontal membrane, no differences could be found in the morphology and array between the two fibres.
3. Often, parts of the same fibre in the periodontal ligament of swine stain like elastic while other parts of the same fibre stain like oxytalan.
4. Formalin-fixed oxytalan fibres are generally refractory to digestion by elastase, although they are susceptible to digestion by the same enzyme after strong oxidation with peracetic acid.
5. The fibres are stained with three of the basic elastic tissue stains provided they are first oxidised with peracetic acid.
6. On rare occasions typical elastic fibres may develop in human periodontal ligaments subjected to heavy occlusal forces.
7. Developing (pre-elastic) fibres in man are stained by the oxytalan method prior to the stage when they can be stained with elastic tissue methods.

8. Elastic fibres often appear to develop from oxytalan fibres in periodontal ligaments involved with scleroderma.
9. In man, many fine extensions of elastic fibres running from the dermis to the basement membrane of normal skin can be routinely stained with oxytalan methods and not by elastic tissue techniques.

## LITERATURE REVIEW

---

oxytalan fibres

elastic fibres

### TEMPOROMANDIBULAR AND OTHER SYNOVIAL JOINTS

#### TEMPOROMANDIBULAR AND OTHER SYNOVIAL JOINTS

The literature review is concerned with structures comprising the temporomandibular joint. However, reference will be made to specific components of other synovial joints. A considerable amount of research on the temporomandibular joint has utilised material of human origin. These investigations will be used as a basis for further discussion in the literature review.

It has been stated (BARBENEL, 1972) that the temporomandibular joint is a stress bearing structure; however, there is no unanimity of opinion on this viewpoint (BLACKWOOD, 1966).

The component parts of a joint which pertain to the present investigation are :

1. articular surfaces
2. articular disc
3. joint capsule
4. ligaments, tendons and muscles related to joints

## 1. ARTICULAR SURFACES

### - weight bearing synovial joints

The cartilage covering the articular surface of weight bearing synovial joints is generally of the hyaline variety. It is a highly specialised connective tissue consisting of relatively few cells distributed throughout an abundant extracellular matrix. The matrix is not truly homogeneous but contains many fibres which are thought to be mostly collagen in nature. These components are arranged architecturally to withstand the various forces delivered at the surface of the cartilage and transmitted to its deeper structures.

The collagen frame-work of articular cartilage has been reported on many times using various examination techniques. A review of the fibrillar structure is beyond the scope of this investigation; however, up to the present time there has been little agreement even on the most general features of fibre arrangement. The arcade concept of BENNINGHOFF (1925), in which the collagen fibres are thought to form curved arcades extending from the layer of calcified cartilage to the free surface, is probably the most widely accepted of all the structures proposed for articular cartilage.

Hyaline cartilage stained by the common histochemical methods for collagen does not reveal any fibres. This is thought to be due to the high acid mucopolysaccharide content of the ground substance which effectively blocks the anionic dyes from attaching to the cationic sites of the collagen (HAMMERMAN and SCHUBERT, 1962). The collagen fibres of articular cartilage may be shown by phase

contrast microscopy, the electron microscope and the use of special stains.

- temporomandibular joint

ORBAN (1944) described the articulating parts of the human temporomandibular joint as being covered by fibrous or fibrocartilaginous tissue, and not by hyaline cartilage. At no stage during the development of the condyle does hyaline cartilage, which is present during its growth period, reach the surface. The fibrous covering of the condyle was stated to be of fairly even thickness with its most superficial layers consisting of a strong network of collagenous fibres. It also contained cartilage cells which tended to increase in number with age. Cartilage cells were similarly found in the temporal fibrous articulating tissue in varying numbers.

SICHER (1951) acknowledged the presence of cartilage cells in the fibrous covering of the opposing bony surfaces. He attributed the lack of blood vessels in both surface layers as being proof that the joint is subjected to considerable functional pressure. Additionally, the presence of cartilage in the fibrous layers, as well as the direction of the fibre bundles themselves, was stated to be further evidence for the pressure bearing role of this joint. He said, "... The fibres run at right angles to the bony surface in the deep layer, and parallel to the surface in the superficial layer. In this arrangement the fibres duplicate the direction of

*the fibrils in an articular cartilage. The deep layers are adapted to pressure, the superficial layers to sliding under pressure."*

MACALISTER (1954) undertook a microscopic survey of the human temporomandibular joint and found that the articular tissue contained three distinct layers. They consisted of an outer fibrous layer, a mid-transitional layer and an inner layer of hyaline cartilage until the end of the second decade. Thereafter, the outer fibrous layer changed to a true fibrocartilaginous covering with cartilage cells apparent in the fibrillar matrix.

SCOTT (1955) stated that the most convincing evidence for designating the temporomandibular joint a non-pressure bearing structure was to be found in the arrangement of the head of the condyle. During childhood the condylar growth cartilage was located below the surface perichondrium. He called the superficial zone of the perichondrium the fibrous layer, and designated the deep zone as the cellular layer. In true pressure bearing joints, he argued, the growth cartilage of the bony element is separated from the articulation by the epiphyseal bone which in turn is covered by articular cartilage. Such an arrangement was not to be seen in the human temporomandibular joint.

MILES and DAWSON (1961) observed the presence of elastic fibres in the articular fibrous tissues of temporomandibular and sternoclavicular joints. In human temporomandibular joints the elastic fibres were generally found to follow the orientation of the collagen bundles. They used conventional elastic stains and found

fibres one to three microns thick which branched and formed a network throughout the articular tissue. Elastic fibres were also demonstrated in the temporomandibular joints of a variety of different animals, including the rabbit. Miles and Dawson claimed that elastic fibres might be an integral part of articular fibrous tissue and said that their function was to impart resilience to the condylar surface.

MOFFETT, JOHNSON, McCABE and ASKEW (1964) noted that the ratio of chondrocytes to fibrocytes, as well as their total number, was not constant in the articular tissue of man. This ratio changed for all specimens and also varied in different articular areas of the same mandibular condyle. The cellular pattern showed no relationship to age but seemed to depend more on mechanical factors associated with function. In the superficial layers of the fibrous tissue collagen bundles were seen to travel parallel to the joint surface and interlace with each other in this plane. The authors distinguished between articulating and non-articulating parts of the joint. They found that in those areas of the joint presumed to articulate, the fibrous covering was thicker and contained fibrocartilage in its deeper layers. It was concluded that, *"The slow transformation of fibrous articular tissue into fibrocartilage occurs in those parts of the joint which are weight-bearing or loaded surfaces. Much evidence is available to indicate that cartilage can be induced to form in connective tissue at points where there is movement combined with pressure or mechanical loading."*

From an examination of the internal bony architecture they

suggested that the form of the condyle showed a correlation with the distribution of pressure along its surface.

BLACKWOOD (1966) studied the cellular remodelling in articular tissue and showed that three cell zones were discernable in the growing articular portion of the human mandibular condyle. They comprised the articular zone, the proliferative zone and the hypertrophic zone. Growth was thought to take place mainly in the middle zone. Three cell zones were also observed in the mature condyle. The surface articular zone was similar to that in the growing joint. However, the proliferative zone had shrunk to a thin band of cells, while the hypertrophic zone was replaced by a zone of fibrocartilage which overlaid the sub-articular bone. Blackwood regarded the temporomandibular joint as being normally a non-weight bearing structure, but he contended that any mechanical loading of the joint at its surface must be capable of causing the transmission of a stimulus to the deeper layers in order to initiate the remodelling changes observed in the study.

MOFFETT (1966) considered that differentiation into fibrocartilage occurred in those parts of the joint where the fibrous articular tissue was compressed during function. In the review he discussed the various types of remodelling and stated that, "*... the temporomandibular joint is capable of altering its contours as a morphological adaptation to the mechanical stresses associated with function.*"

BLACKWOOD (1969) stated that the articular surface of the condyle is formed by dense bundles of collagen fibres orientated for the

most part parallel to the surface and interspersed with some fine elastic fibres.

## 2. ARTICULAR DISC

Articular discs have probably received more attention in the literature than any other joint structure. The Nomina Anatomica (1955) describes the term discs as circular structures with or without central perforations. Meniscus is said to mean a semi-lunar shaped element with one concave and one flat surface. For descriptive purposes the term disc will be used throughout this investigation to denote both types of structure.

PARSONS (1899) noted that the mandibular disc was a very constant feature in the Mammalia, although it may be suppressed or underdeveloped in some animals. He believed that a combination of rotation with gliding during jaw movements was often coincident with the formation of discs.

ORBAN (1944) described the mandibular disc in man as being composed of dense collagenous tissue whose fibres were straight and occasionally interspersed with a few elastic fibres. The disc did not show the usual fibrocartilaginous character of discs in other parts of the body. He regarded this as a reflection of its high mobility and plasticity during function. With age the fibroblasts were thought to develop into "... chondroid cells which, later, may become real chondrocytes. Even small islands of hyaline cartilage may be found in the discs of older persons."

The presence of chondrocytes was thought by Orban to increase the resistance and elasticity of the fibrous tissue.

SICHER (1951) stated that the lack of blood vessels in certain parts of the disc was proof that there was considerable pressure within the human temporomandibular joint. He regarded the presence of cartilage cells, which occurred only in higher age groups, as a response of the tissue to pressure and friction.

REES (1954) studied the anatomy and histology of the human temporomandibular joint and attempted to correlate structure with function. He found the majority of fibres comprising the disc were of dense plaited collagen. However, in the upper stratum of the so-called 'bi-laminar' zone at the posterior part of the disc he observed much loose fibro-elastic tissue. Groups of cells resembling chondrocytes were also seen in the denser regions of the disc.

HANKEY (1954) observed that the human mandibular disc was composed of interlacing bundles of thick collagen which ran parallel to the surface on the upper and lower parts of the disc. The presence of some elastic fibres was also noticed in the disc, particularly in the loose connective tissue at the posterior region of the joint.

MACALISTER (1954) found that the mandibular disc in humans consisted essentially of dense collagenous tissue and cartilage cells were only observed in elderly subjects who had worn artificial dentures. He assumed that cartilage cells were a manifestation

of physical changes affecting the joint and should not be included therefore in a histological description of the normal disc.

SPRINZ (1954) described the mandibular disc of a rabbit as being composed of dense fibrous tissue which contained no cartilage cells. The central parts of the disc were found to be avascular.

BARNETT (1954) noted the structure of various joints from different animal species. He concluded that discs were present "... *in those articulations where some of the movements characteristic of ball-and-socket and condyloid joints are combined with the movements characteristic of plane joints.*" Such a combination of movements demanded a well-rounded entering surface and a relatively flat receiving surface. The disc was thought to compensate for any discrepancies between the opposing bony surfaces during mandibular movements. Barnett observed that the disc contained cartilage cells in those animals whose upper and lower articulating surfaces were steeply inclined to each other.

GRIFFIN and SHARPE (1960) reported a histological study of the temporomandibular joints obtained from cadavers whose ages ranged from 18 to 62 years. They observed that parts of the disc consisted of fibrocartilaginous tissue. The same areas were also found to be avascular. It was concluded that these particular sites were subjected to compression during joint function.

BARNETT, DAVIES and MacCONAILL (1961) stated that elastic tissue is found in locations throughout the human mandibular disc in addition to the upper stratum of the bilaminar zone described by

Rees. Elastic tissue was observed anteriorly at the site where the lateral pterygoid muscle attached to the disc. Fine elastic fibres were also distributed throughout the whole of the disc, including the central dense portion, and were orientated in a random manner. They observed that with material obtained from an older age group the elastic fibre content of the main body of the disc decreased in number and there was parallel hyalinisation of the collagenous tissue.

DIXON (1962) examined the temporomandibular joints of cadavers between the age of 45 and 60 years. He found that the anterior part of the disc was composed of densely woven fibrous tissue while the posterior part demonstrated a more open texture. Cartilaginous changes were common in the fibrous part of the disc obtained from older subjects. The vascular and elastic zones noted previously by Rees at the posterior part of the disc were also seen.

MOFFETT, JOHNSON, McCABE and ASKEW (1964) observed more cartilage cells in the central dense site of the human mandibular disc than at its peripheral parts. Bundles of collagen fibres were seen to run parallel to the surface of the disc in this central area and had a predominantly antero-posterior direction. In the more peripheral zones the disc became thinner with the collagen bundles now forming an interlacing network. At the same time the number of cartilage cells were observed to decrease. They interpreted the presence of fibrocartilage in the central part of the disc as being an indication of the stress bearing role it played

during jaw movements.

THILANDER (1964) undertook an investigation of the collagen structure of the human mandibular disc in a pathology-free series with a wide age range. Collagen fibres, together with elastic fibres, were observed at an early intra-uterine stage. Shortly after birth the collagen fibres demonstrated a reorientation similar to that seen in the adult structure. This change coincided with a decrease in the elastic fibre content. With further aging, the amount of collagen gradually increased as the elastic fibre content of the disc gradually decreased. Cartilage cells were not observed in the disc at any stage. Their absence was thought to support the finding that the material used had no history of joint disorders.

SPRINZ (1965) studied the mandibular joint from a number of marsupials and monotremes for the presence or absence of an articular disc. In those joints where the disc was completely formed its structure consisted of bundles of collagen fibres. He suggested that in those species which lacked a disc there may have been fusion between the disc and articular surfaces, since there appeared to be a relatively thicker articular fibrous covering.

ÖBERG, CARLSSON, FAJERS and BERGMAN (1966) reported the morphological aging of the normal temporomandibular disc. They found that 'chondroid' cells were observed in all the discs examined from subjects whose ages ranged from 3½ to 67 years. The cartilaginous cells were assumed to be a normal component of the disc and their relative increase with advancing age represented a physiological

rather than a pathological phenomenon.

By comparing the jaw movements in mammals MILLS (1967) stated that the disc may have developed in those animals where lateral jaw movements were possible. He considered that any lateral movement must include a rotational component rather than being purely translatory. Mills pointed out that the function of the disc was not well-known in mammals generally and indicated a need for further research in this field.

### 3. JOINT CAPSULE

In current anatomical nomenclature the term articular capsule includes both the fibrous capsule and the synovial membrane. Since the synovial apparatus is beyond the scope of this investigation it will not be discussed further.

According to BARNETT, DAVIES and MacCONAILL (1961) true articular capsules are confined to synovial joints where they form somewhat barrel-shaped sleeves around the joints and generally attach at either end to the bones participating in the articulation. In places the fibrous capsules may attach to other ligaments instead of to bone, and they may also be deficient in part of their extent.

ORBAN (1944) described the articular capsule of the temporomandibular joint in man as being an outer fibrous layer with loose thin walls.

SICHER (1951) studied the temporomandibular joint also and found

that the capsule from human material was thin walled. He noted that the portion of the capsule between the temporal bone and the disc appeared to be loose and suggested that this arrangement may allow translatory movements to occur in the upper joint compartment. In the lower compartment the capsule was described as being tense between the disc and condyle and therefore thought to limit the amount of movement which could take place.

REES (1954) found that the disc of the human temporomandibular joint gained attachment both medially and laterally with the capsule and both inserted together to the medial and lateral poles of the condyle. Posteriorly, the disc appeared firmly attached to the capsule which ran directly from the temporal bone to the mandibular condyle. The capsule was found to be deficient anteriorly.

SPRINZ (1954) investigated the effects of meniscectomy in rabbit mandibular joints and stated that the disc was attached peripherally to the capsule surrounding the joint. During excision of the disc he observed that it was generally most firmly attached to the anterior part of the capsule.

CHOUKAS and SICHER (1960) emphasised that the relations of the disc to the capsule and the condyle, in different areas of the human temporomandibular joint, have their own special functional significance. The capsule and the disc were fused anteriorly to allow for some fibres of the lateral pterygoid muscle to attach directly with the disc. Medially and laterally the capsule and the disc had independent attachments to the condyle. Posteriorly the disc was described as being only loosely attached to the capsule.

BARNETT, DAVIES and MacCONAILL (1961) stated in general that fibrous capsules varied in their degree of development and strength and may be thickened in different parts according to the functional demands placed upon them. Capsules consisted chiefly of collagen fibres arranged as parallel bundles. Intermingled with the collagen was a network of reticular fibres. They found that elastic fibres only occurred in the capsule in association with blood vessels.

#### 4. LIGAMENTS, TENDONS AND MUSCLES RELATED TO JOINTS

##### - ligaments and tendons

In addition to the fibrous capsules enclosing joints, many articulations are further reinforced by other ligaments which may be intra-articular or extra-articular in position.

STILWELL and GRAY (1960) used post-mortem material to examine the microscopic structure of periosteum in different areas of tendinous contact. They noted that the periosteum underlying different tendons did not always have the same structure. Also, there was no consistent pattern of periosteal structure from the same area of attachment in different specimens. Fibrous connective tissue formed the periosteum in approximately two-thirds of the areas studied, while fibrocartilage was the predominant tissue in the remaining one-third. Elastic fibres were only found in moderate amounts from periosteum formed of more loosely arranged tissue.

COOPER and MISOL (1970) examined the insertion of patella and medial femoral collateral ligaments in adult dogs by light and

electron microscopy. They divided the insertion sites into four zones - tendon (or ligament), fibrocartilage, mineralised fibrocartilage and bone. Collagen fibres constituted by far the bulk of tendon and ligament zones, with occasional elastic fibres scattered among the parallel rows of collagen. Both fibre types were found to extend unchanged in proportion, arrangement and direction from the tendon to form the inter-cellular matrix of the fibrocartilage zone. The investigators postulated that the elastic fibres may enable ligaments and tendons to return to their original shape after deformation and also maintain alignment of collagen fibres especially after lateral bend.

- periosteum

BAILEY'S TEXTBOOK OF HISTOLOGY (1964) described the periosteum as a fibrous membrane investing the bones, except at their articular surfaces, and consisting of two different layers of tissue. The outer layer is composed of coarse fibrous connective tissue containing few cells but numerous blood vessels and nerves. The inner layer is less vascular but more cellular than the outer layer and contains many elastic fibres.

- muscles related to the T-M joint

ABBIE (1939) claimed that in certain marsupials the temporalis and lateral pterygoid muscles find attachment to the neck of the mandible and the articular disc. The insertion of the temporalis into the condyle and disc was thought to provide some reinforcement for a relatively underdeveloped lateral pterygoid muscle in these animals.

SICHER (1951) stated that in humans the uppermost fibres of the lateral pterygoid muscle gain attachment to the anterior border of the articular capsule and the anterior part of the disc.

SYMONS (1952) studied the development of the human temporomandibular joint and concluded that the disc appeared to be an extension of the tendon of the lateral pterygoid muscle into the joint area.

REES (1954) found that the lateral pterygoid, masseter and temporalis muscles are all attached to the human mandibular disc. He described the lateral pterygoid as making a 'true insertion', while the others were connected by fibrous bundles at right angles to the direction of their muscle fibres.

SPRINZ (1954) noted that the disc in rabbits was attached anteriorly to both the lateral pterygoid and masseter muscles.

Joints known to be load-bearing occur between some long bones, while often it is a matter of speculation whether there is a force transmitted across the temporomandibular joint.

ROYDHOUSE (1955) studied the pull of the muscles of mastication and concluded that there was an upward force on the cranium during functional jaw movements.

SCOTT (1955) also analysed the action of the muscles of mastication and found that fibres of the temporal muscle acting alone (sheep and dogs) or in combination with the lateral pterygoid muscle (man and primates) may provide a mechanism for removing pressure from the head of the condyle during mastication.

BARBENEL (1972) found that the force actions of the muscles of mastication acting across the joint were best analysed using linear programming methods. In this way the minimum joint forces as a function of occlusal load could be determined. The results indicated that the temporomandibular joint is a load-bearing structure during function.

### Selection of Animals

Five rabbits of mixed sex and of various strains were used to provide material for the investigation. They consisted of laboratory animals approximately 12 months old. Two of the rabbits were used for dissection purposes to study the gross anatomy of the temporomandibular and knee joints. The joints from the three remaining rabbits were removed for histological examination.

To sacrifice the animals 5 ml of Nembutal (Abbott's veterinary sodium pentobarbitone) containing 60 mg/ml was injected into the lateral vein of the ear.

### Removal of Joints

Temporomandibular joint:

After sectioning the bone of the zygomatic arch, neck of the condyle and the temporal bone surrounding the root of the zygoma, the temporomandibular joint was carefully dissected out without damaging the articular tissues.

Knee joint:

The patella ligament was dissected from its bony attachments and examined separately. The femur, tibia and fibula were sectioned approximately one centimetre from the articulation. The joint was

then dissected out from the soft tissues surrounding it.

#### Fixation

The joints were transferred immediately to a phosphate buffered solution of 10% formol saline for 24 hours prior to decalcification.

#### Decalcification

This was carried out using a solution of 40% formic acid.

(Appendix VII.1).

The specimens were checked radiographically to determine when decalcification was complete. The average time taken for the temporomandibular joints was two weeks, while four weeks were generally required to obtain complete decalcification of the knee joints.

#### Processing

Following decalcification the specimens were placed in 5% sodium sulphate in order to neutralise the remaining formic acid. They were then dehydrated and processed in the usual laboratory manner employing a double embedding technique. (Appendix VII.2).

#### Blocking

The specimens were blocked in fresh clean paraffin wax at 56°C using either plastic moulds (peel-away) or blocking irons, depending upon the bulk of the tissue specimen.

Three temporomandibular joint blocks were obtained and orientated so that sections could be cut in the sagittal, coronal and horizontal planes.

Two knee joint blocks were orientated longitudinally to obtain sections in the antero-posterior and medio-lateral planes.

A patella ligament (including its bone) was blocked to obtain longitudinal sections of the structure in the antero-posterior plane.

#### Cutting

Sections were cut at 6 microns using a Leitz microtome type 1212. The sections were transferred to a water bath (Labmaster) and mounted on clean glass slides.

Total number of sections obtained :

#### Temporomandibular joint

Serial sections obtained from the saggital plane numbered 680, while 476 were cut from the horizontal plane. In the coronal plane 220 serial sections were cut from the anterior part of the joint, while 100 sections were sufficient to study the posterior (non-articulating) part of the joint.

#### Knee joint

A series of sections were obtained from this joint at intervals of 200 microns. Each series consisted of 20 serial sections. A total of 280 antero-posterior and 260 medio-lateral longitudinal sections were cut.

#### Patella ligament

Forty serial sections were cut from the block.

#### Staining

Two different histochemical stains were used routinely throughout

this investigation.

1. Aldehyde fuchsin, as employed by FULLMER and LILLIE (1958) to selectively demonstrate oxytalan fibres, was used to stain every tenth section. (Appendix VII.3). An adjacent slide was used throughout the series as a control slide. This slide was stained identically except that the oxidation step was omitted. The staining technique was modified by oxidising the sections with a 10% aqueous solution of Oxone (DuPont's monopersulphate compound) for 90 minutes in place of the original peracetic acid (RANNIE, 1963; FULLMER, 1966). Halmi's counterstain was used for all the aldehyde fuchsin-stained sections. (Appendix VII.3).
2. Orcein was also used by FULLMER (1959b) to show oxytalan fibres in oxidised tissue sections. (Appendix VII.4). As with the aldehyde fuchsin series, every tenth section was stained, while an adjacent control section was stained with orcein without prior oxidation. Light green counterstain was used for all the orcein sections. (Appendix VII.4). Fullmer stated that the orcein technique had an advantage over the aldehyde fuchsin method because, unlike aldehyde fuchsin, the orcein reacted only slightly with the mucopolysaccharide present in the ground substance of connective tissue. It was therefore possible to detect fine oxytalan staining fibres which would be missed if aldehyde fuchsin was used. The disadvantage of orcein, according to Fullmer, was that it did not stain all of the oxytalan fibres present in connective tissue.

### Photomicrography

Black and white exposures were taken with a Leitz 'Ortholux' photo-microscopic attachment using Ilford FP4 cut-sheet film 4 $\frac{1}{4}$ " x 3 $\frac{3}{4}$ ". The image magnification produced at the film surface corresponded with the magnification registered at the eye-piece. Processing and printing procedures were carried out according to the recommended methods. Care was taken to print the negatives without a magnification factor.

Colour exposures were taken with a Leitz 'Orthomat' photo-microscopic attachment using Kodak Kodachrome II Professional 35mm film. The exposed film was processed at Kodak laboratories and printed on standard size 5" x 3" paper.

### Criteria for calling a fibre 'oxytalan'

FULLMER and LILLIE (1958) outlined the staining reactions of oxytalan and elastic fibres and the effect of enzymatic hydrolysis on these reactions. Their results are summarised in the following two tables :

1. Staining reactions of Oxytalan and Elastic fibres

Reactions	Oxytalan	Elastin
<u>Stained directly</u>		
The 5 elastin stains	-	+
<u>Peracetic acid oxidised</u>		
Orcein	brown*	brown
Aldehyde fuchsin	purple	purple
Resorcin fuchsin	purple*	purple
Verhoeff's stain	-	black
Orcinol-new fuchsin	-	purple

\*Some fibres are reactive. others are not

2. Effect of Enzymatic Hydrolysis on staining reactions of Oxytalan and Elastic fibres with Aldehyde fuchsin

Enzymatic reactions	Oxytalan*	Elastic <sup>o</sup>
Undigested	purple	purple
Elastase	purple	dissolved
Peracetic-elastase	dissolved	dissolved
Testicular hyaluronidase	purple	purple
Peracetic-hyaluronidase	unstained	purple
Lysosome <sup>#</sup>	purple	purple
Peracetic-lysosome <sup>#</sup>	unstained	purple

\*Stained by the peracetic acid-aldehyde fuchsin method

<sup>o</sup>Stained by aldehyde fuchsin

<sup>#</sup>Fresh frozen sections were used

FULLMER (1960a) added  $\beta$ -glucuronidase to the list of enzymatic reactions. He found that its effect, when interposed between the oxidative and staining steps, was to remove mucopolysaccharides and the stainable component from oxytalan, but not elastic, fibres in tissue sections.

He concluded that the 'elastic-like' fibres are oxytalan if they satisfy the following conditions :

- (1) The fibres do not react with elastic tissue stains;
- (2) They are resistant to elastase digestion;
- (3) They are stained by the peracetic acid-aldehyde fuchsin-Halmi and the peracetic acid-orcein-Halmi methods,
- (4) If tissue sections are oxidised with peracetic acid and then treated by the appropriate testicular hyaluronidase,  $\beta$ -glucuronidase or lysosome digestion, oxytalan fibres do not stain with aldehyde fuchsin or orcein as in (3).

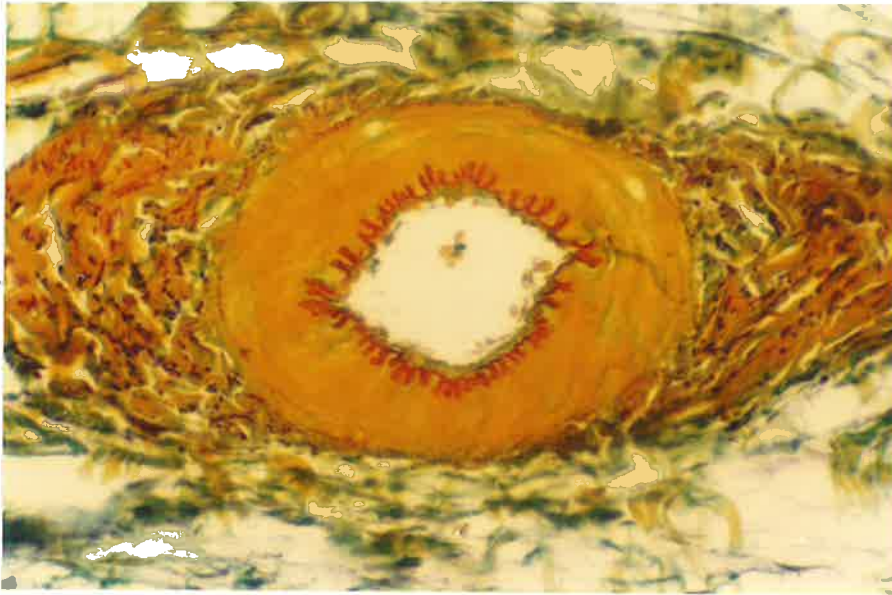
For the purpose of this investigation oxidised and non-oxidised tissue sections were stained by aldehyde fuchsin and orcein.

Enzymatic digestion using  $\beta$ -glucuronidase was used as a confirmatory test for the presence of oxytalan and elastic fibre types.

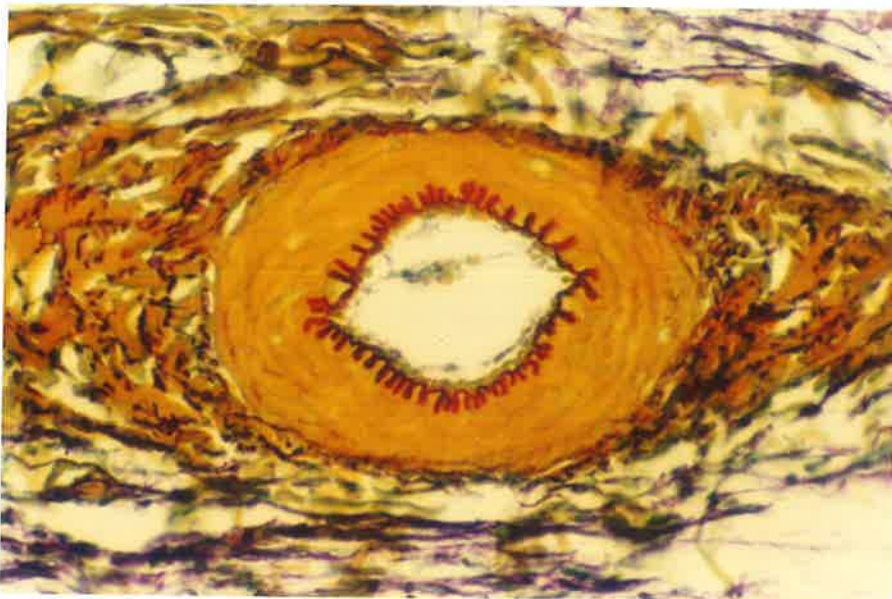
(Appendix VII.5).

The number of fibres stained in the oxidised sections was compared with non-oxidised adjacent sections to determine whether oxytalan and elastic fibres occurred together in certain connective tissues.

The aldehyde fuchsin and orcein stains used in this investigation are demonstrated in the staining reaction of a small artery (figs.1,2).

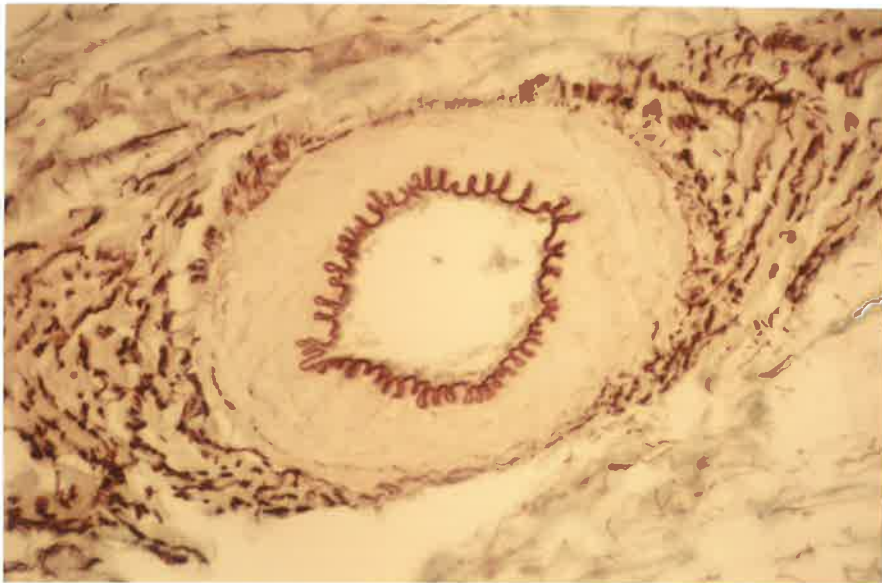

Non-oxidised

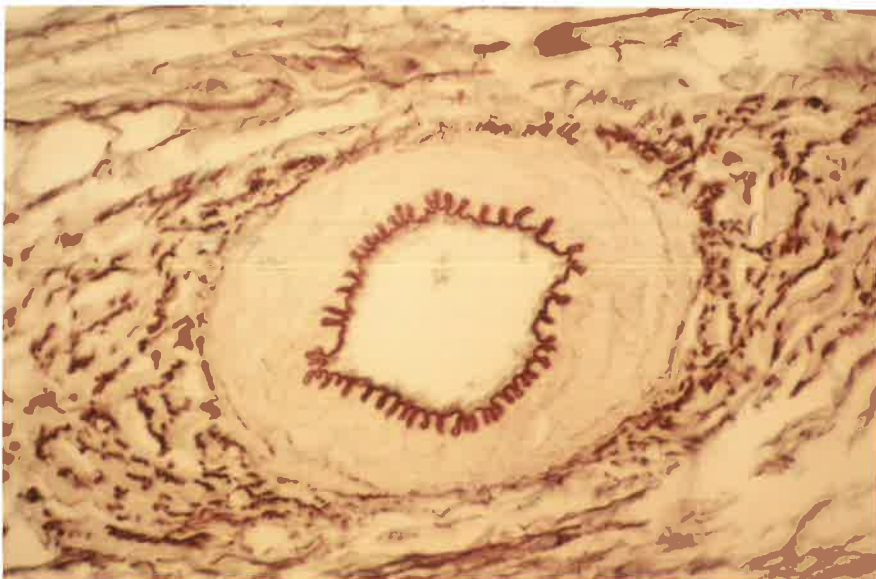


Oxidised

Fig. 1. x250. Artery. Oxidised and Non-oxidised, Aldehyde fuchsin-Halmi stain.



Non-oxidised



Oxidised

Fig. 2. x250. Artery. Oxidised and Non-oxidised, Orcein-Light green stain.

---

GROSS (STATIC) ANATOMY

functional anatomy

histologic anatomy and staining reactions

GROSS ANATOMY

Rabbits belong to the Order Lagomorpha and have many dental features in common with the Rodentia. From the superior aspect the outline of the mandibular condyle is somewhat pear-shaped, with its long axis placed antero-posteriorly. The broad anterior part of the condyle has a convex surface which articulates with the lower surface of the disc.

The disc is an oval-shaped structure which has its long axis orientated medio-laterally. The concave inferior surface of the disc fits the anterior portion of the condyle head. The superior aspect of the disc articulates with the narrow zygomatic process of the temporal bone, and the peripheral margin of the disc is raised superiorly.

In the rabbit the posterior glenoid tubercle is absent.

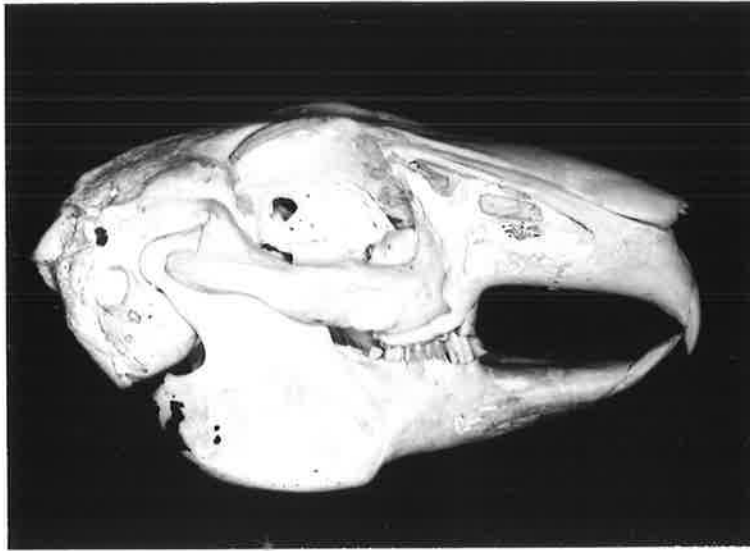A well-developed capsule is present which surrounds the whole of the joint and merges with the margin of the disc. The capsule is attached superiorly to the temporal bone and inferiorly to the mandibular condyle. Anteriorly, the union between the capsule and the disc divides the joint into an upper and lower compartment. The portion of the capsule forming the anterior wall of the upper compartment is thicker

than the corresponding region in the lower compartment. Posteriorly, the capsule is uniformly thick throughout its extent.

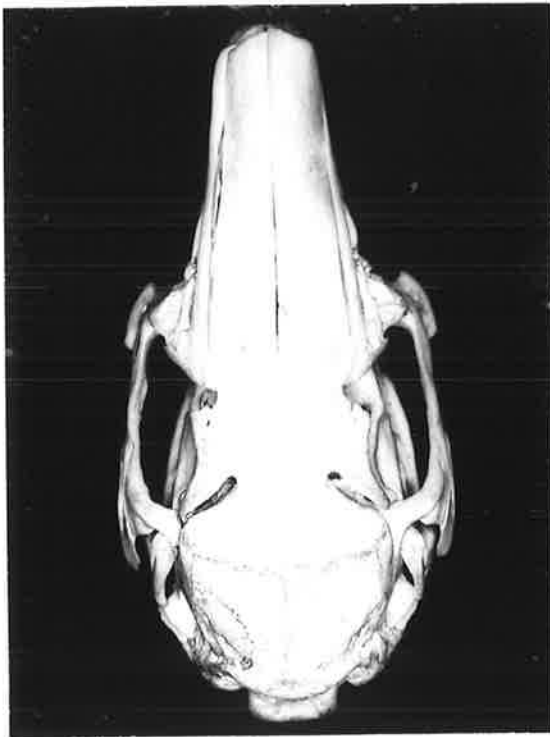
The masseter, temporalis and lateral pterygoid muscles are closely related to the mandibular joint and attach to the joint capsule with some of their fibre bundles. The temporalis and masseter muscles appear to fuse with each other for part of their length adjacent to the front of the capsule.

The gross anatomy of the temporomandibular joint articulation is shown by the photographs of a rabbit skull (fig. 3).

The articulation is also shown diagrammatically in the sagittal, coronal and horizontal planes (fig. 4).



Lateral View

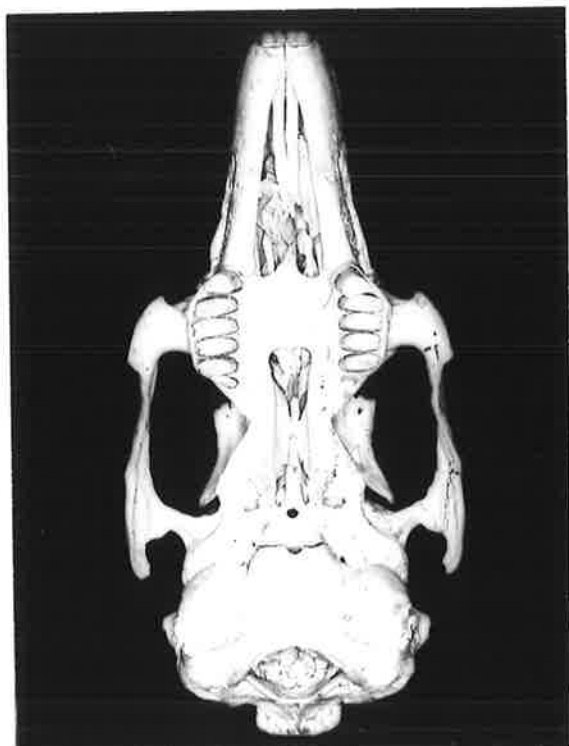


Superior View

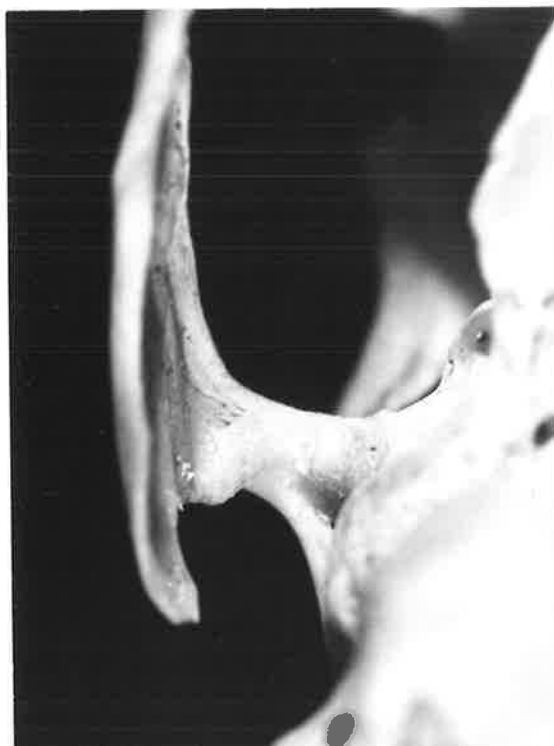

Articulation, Superior View

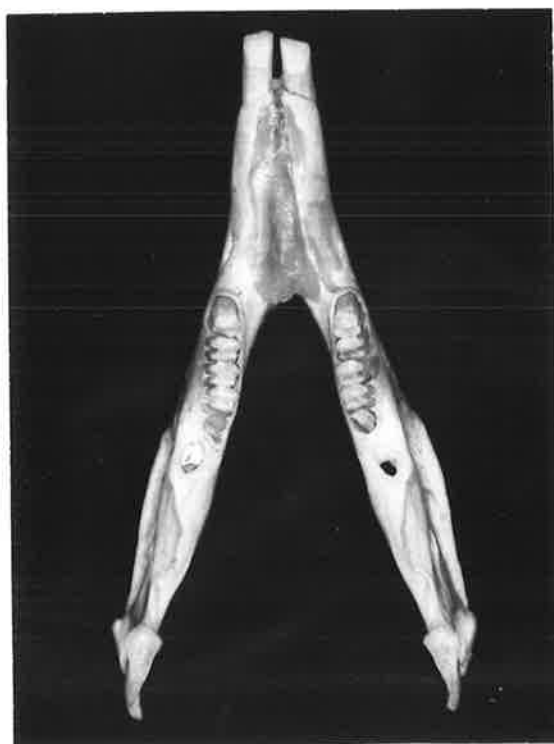Fig. 3a. Rabbit Skull.



Inferior View

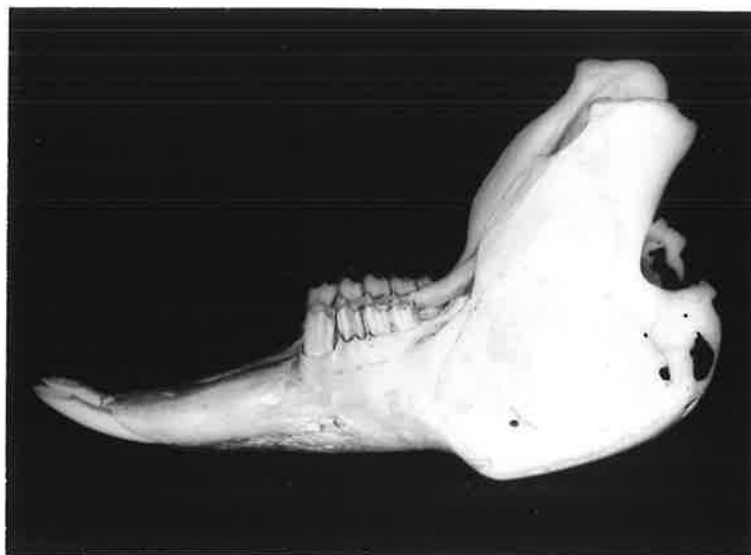

Temporal Articular Surface  
- Inferior View

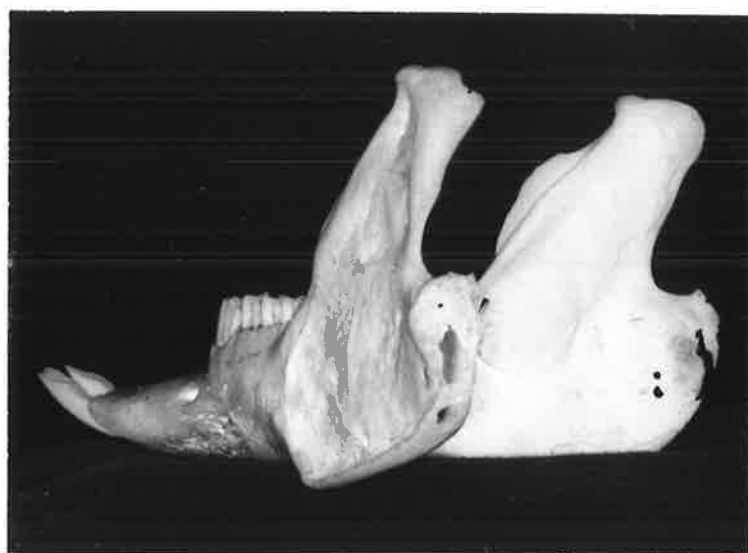


Mandible, Superior View

Fig. 3b. Rabbit Skull.



Mandible, Lateral View



Mandible, Postero-lateral View

Fig. 3c. Rabbit Skull.

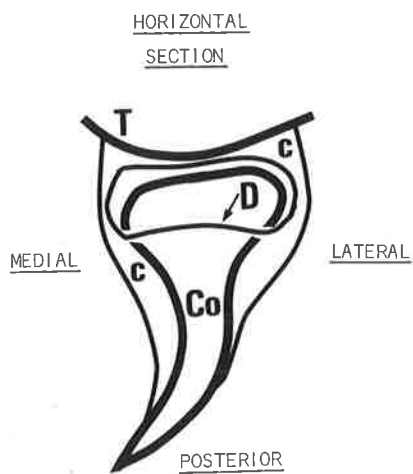
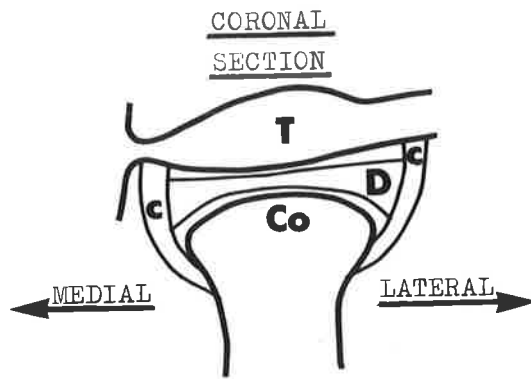
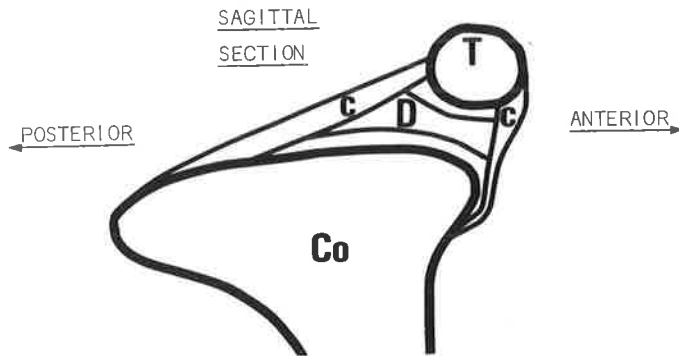


Fig. 4.

Diagrammatic representation of Rabbit TMJ

- T = temporal bone
- Co = condyle
- D = disc
- C = capsule

## RESULTS.....TEMPOROMANDIBULAR JOINT

gross (static) anatomy

FUNCTIONAL ANATOMY

histologic anatomy and staining reactions

FUNCTIONAL ANATOMY

In the rest position of the temporomandibular joint the condyles are situated below the zygomatico-temporal bones and slightly posterior to them (fig. 5a).

During opening both condyles move anteriorly until, at the maximum opening position of the mandible they have moved forward from the original rest position a distance approximating half their length (fig. 5b).

In a lateral excursion movement the ipsilateral condyle mainly rotates, while the condyle on the contralateral side shifts anteriorly a considerable distance. The anterior movement is of the same order as that already described for the maximum opening position of the mandible (fig. 5c).

The examination of the functional anatomy of the temporomandibular joint of a rabbit demonstrates that the condyle is capable of a wide variety of movements, particularly in an antero-posterior direction.

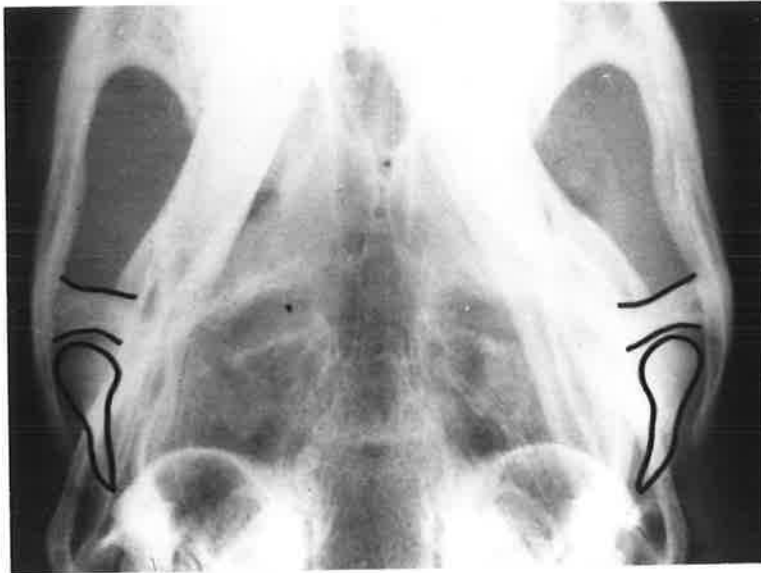

Fig. 5a.

Rest Position

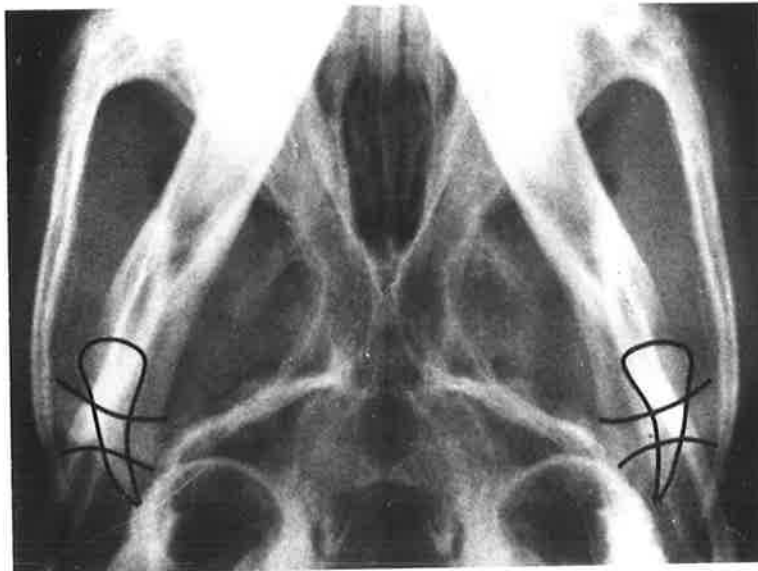


Fig. 5b.

Maximum opening

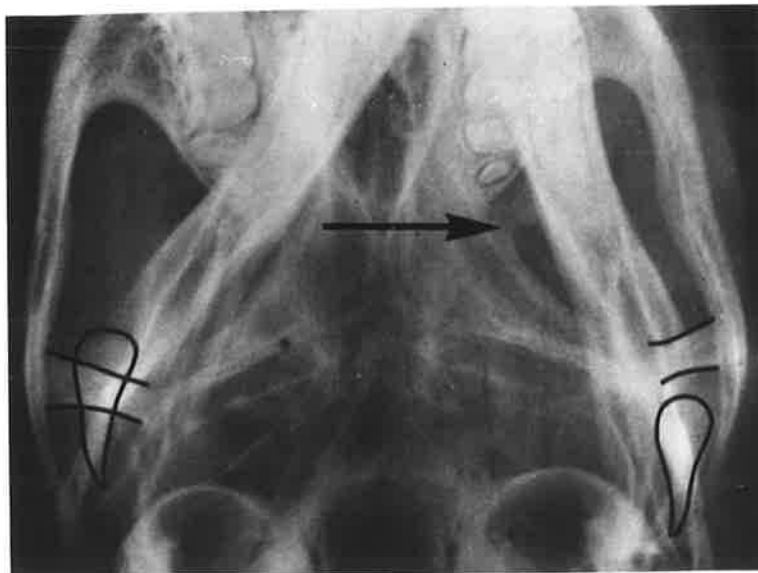


Fig. 5c.

Lateral Excursion

## RESULTS.....TEMPOROMANDIBULAR JOINT

---

gross (static) anatomy

functional anatomy

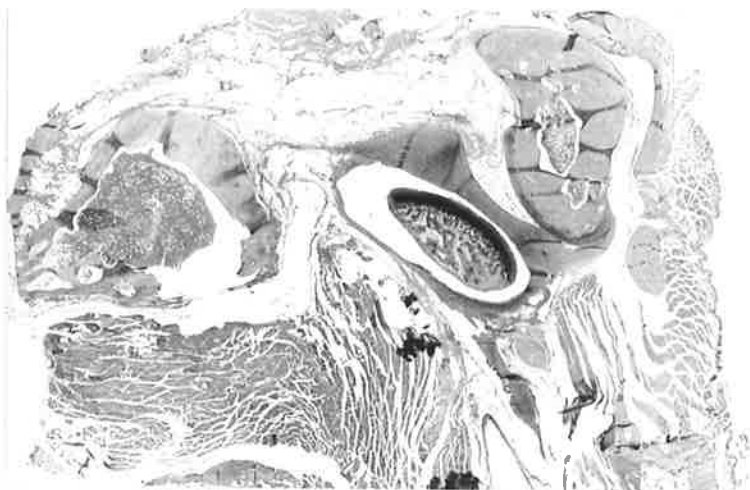
HISTOLOGIC ANATOMY AND STAINING REACTIONS

### HISTOLOGIC ANATOMY AND STAINING REACTIONS

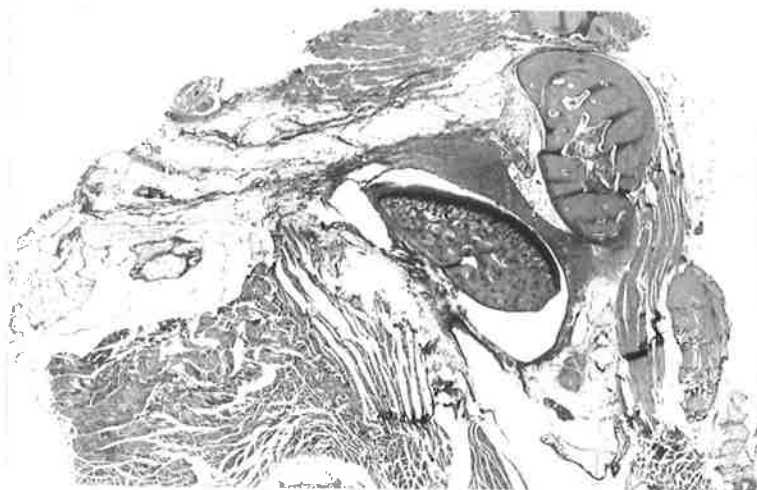
Low power photomicrographs of the rabbit temporomandibular joint [x5] are shown of progressive sagittal (fig. 6), coronal (fig. 7) and horizontal (fig. 8) sections to provide a three-dimensional impression of the anatomy and histology of the structure.

The findings of the staining methods used in this study will be discussed in relation to the following structures :

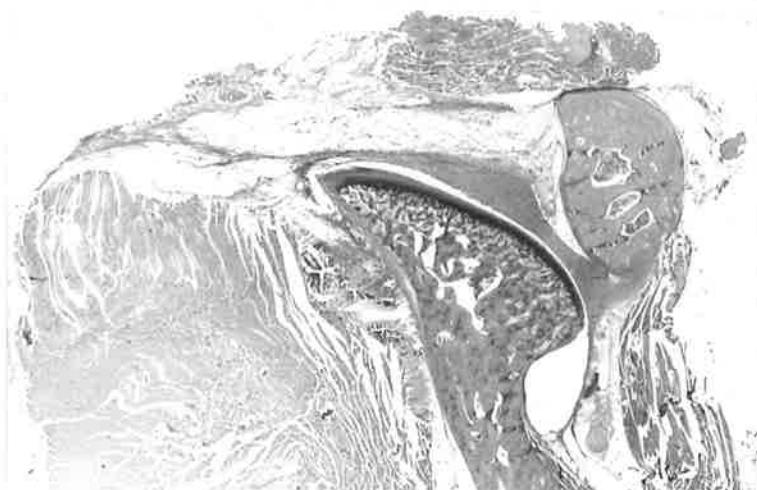
- (i) the bony surfaces
- (ii) the articular disc
- (iii) the joint capsule



(1)



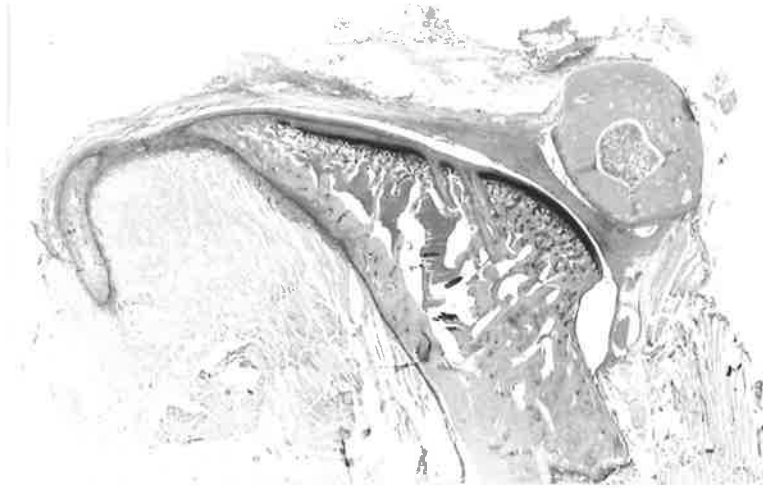
(2)



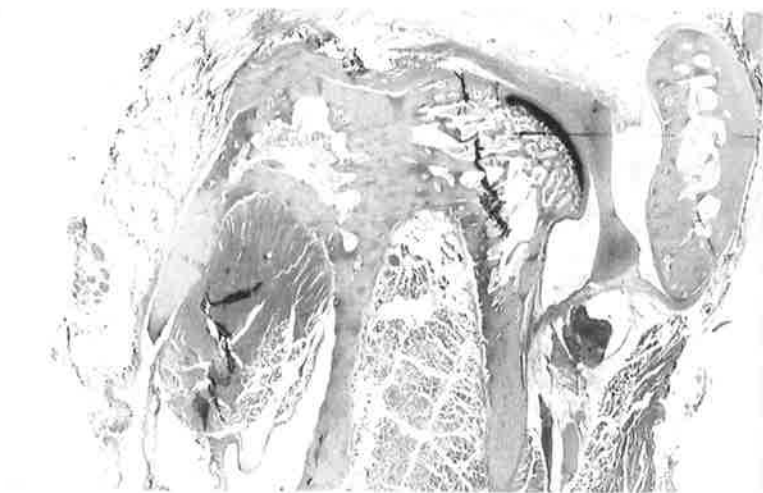
(3)

Fig. 6a. Sagittal sections Rabbit Temporomandibular joint (x5).  
Sections progress from Lateral to Medial.

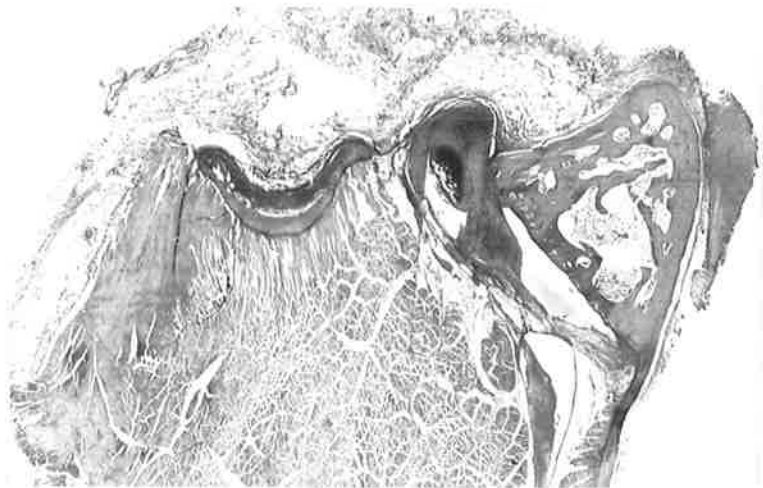
47.



(4)



(5)



(6)

Fig. 6b. Sagittal sections Rabbit Temporomandibular joint (x5).  
Sections progress from Lateral to Medial.

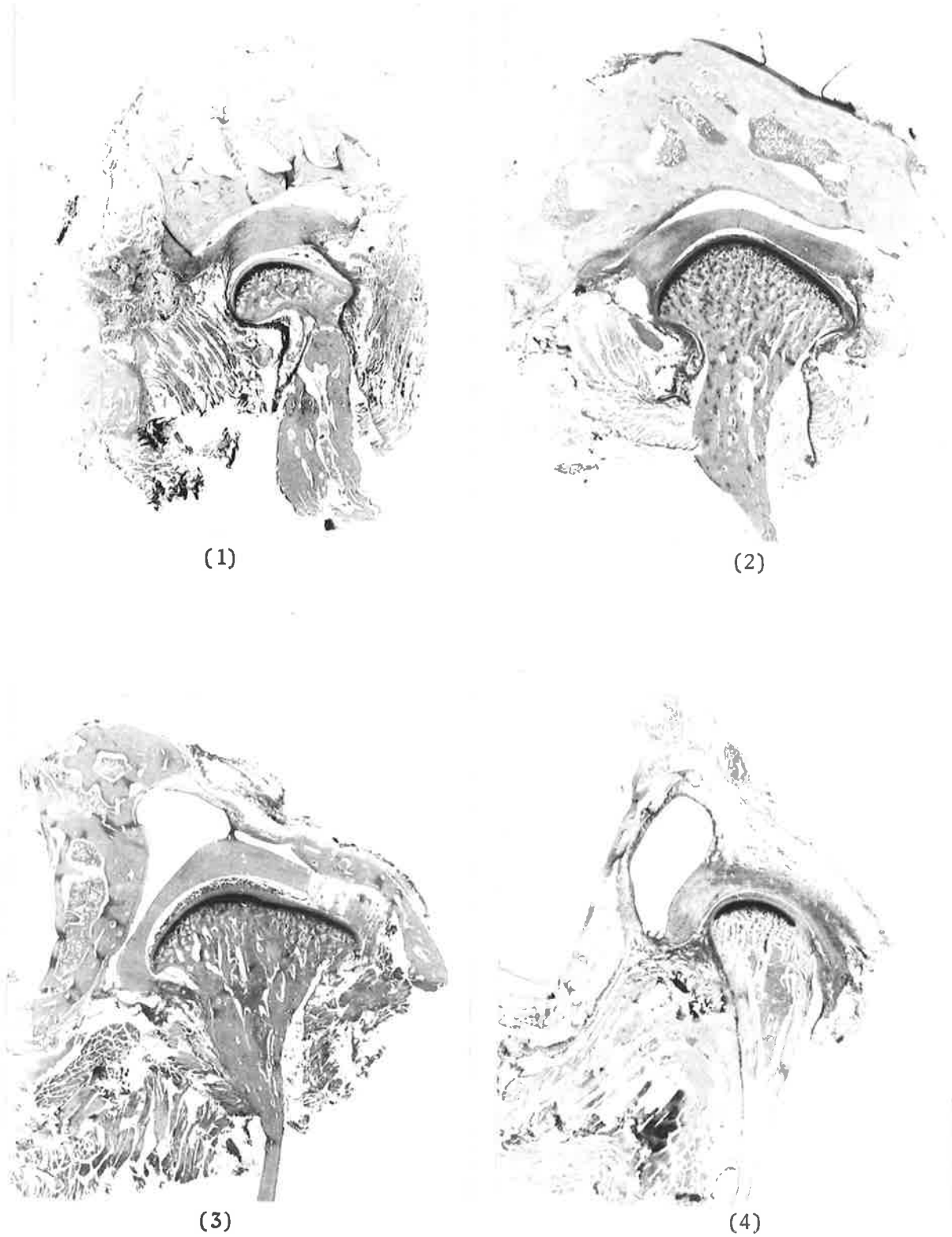


Fig. 7a. Coronal sections Rabbit Temporomandibular joint (x5).  
Sections progress from Anterior to Posterior.

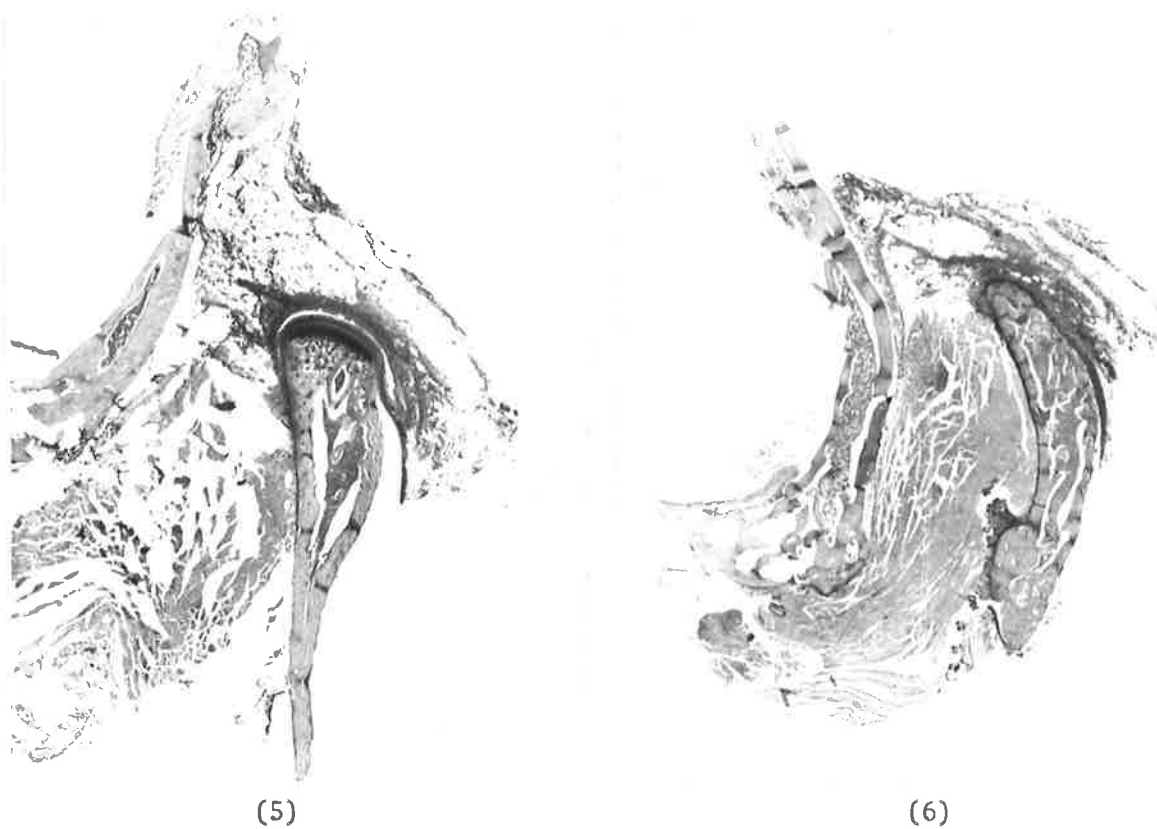


Fig. 7b. Coronal sections Rabbit Temporomandibular joint (x5).  
Sections progress from Anterior to Posterior.

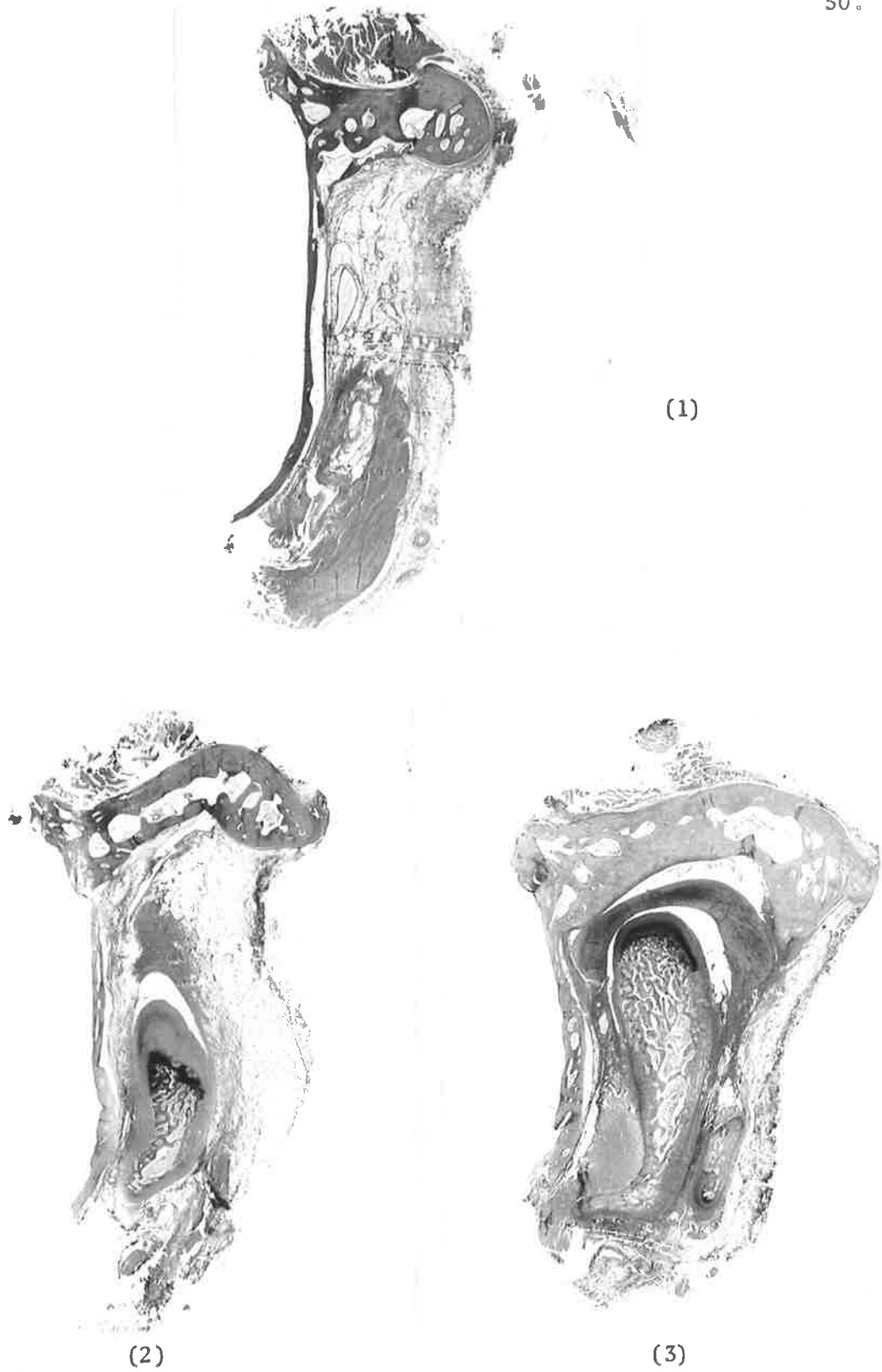
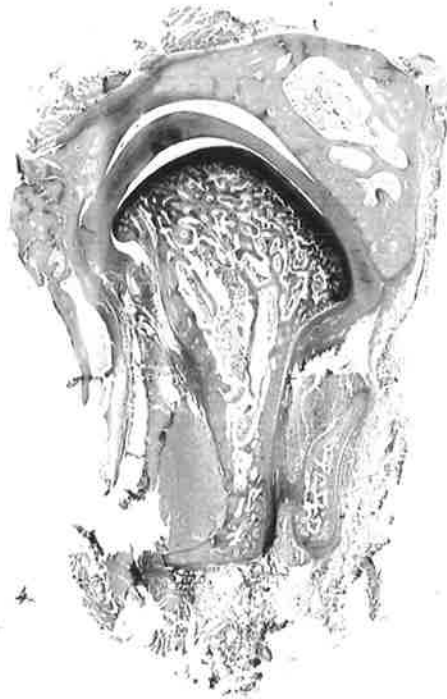
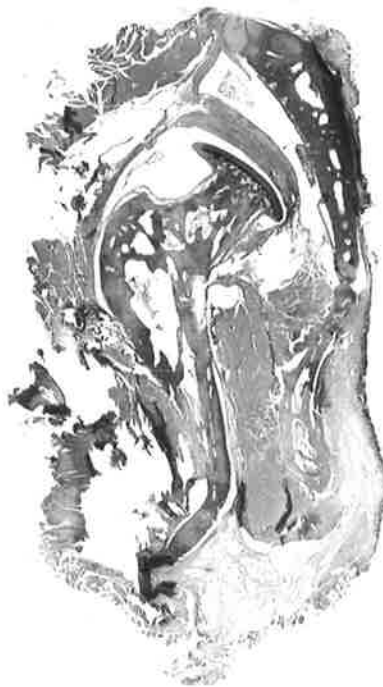

Fig. 8a. Horizontal sections Rabbit Temporomandibular joint (x5).  
Sections progress from Superior to Inferior.



(4)



(5)

Fig. 8b. Horizontal sections Rabbit Temporomandibular joint (x5).  
Sections progress from Superior to Inferior.

(i) THE BONY SURFACES OF THE TEMPOROMANDIBULAR JOINT

CONDYLE

'Articular' part of condyle

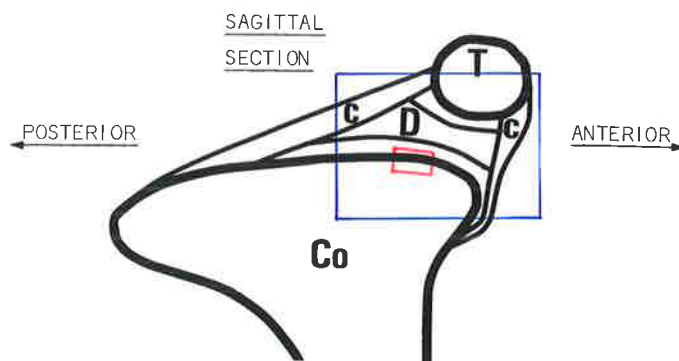
The anterior 'articular' part of the condyle has three distinct tissue layers. They consist of a surface fibrous layer, a mid-transitional layer of fibrocartilage and an inner layer of hyaline cartilage. These layers overlie the bone of the condyle (fig. 9).

A comparison of oxidised and non-oxidised sagittal sections stained by aldehyde fuchsin shows that elastic fibres are absent from the surface layers. Oxytalan fibres are present, arranged for the most part parallel to the surface and running in a predominantly antero-posterior direction (fig. 10a).

Orcein-stained material from the same region confirms the presence of oxytalan and the absence of elastic fibres (fig. 10b).

Horizontal sections demonstrate that oxytalan fibres at the most anterior part of the condyle are arranged obliquely to the surface (fig. 11).

Sections obtained from the coronal plane show mainly cross-sectional and oblique views of oxytalan fibres. This confirms the antero-posterior orientation of these fibres at the anterior part of the condyle (fig. 12).



T = Temporal bone	Co = Condyle
D = Disc	C = Capsule

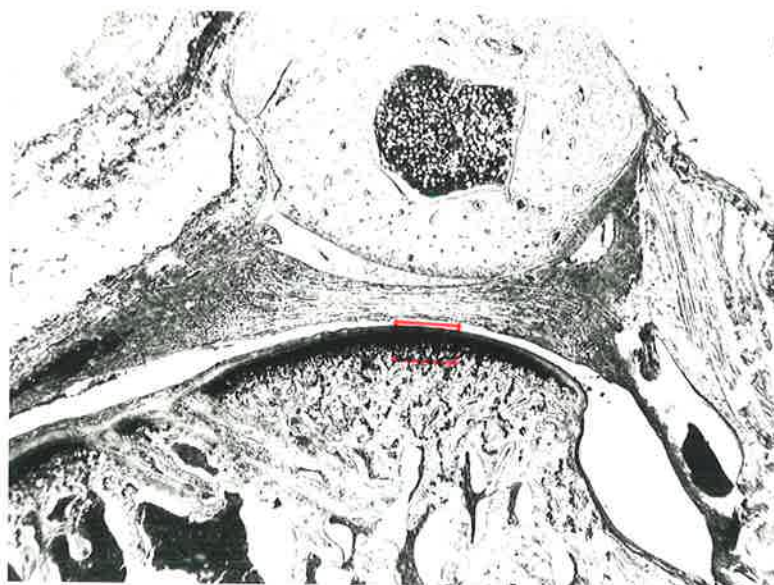
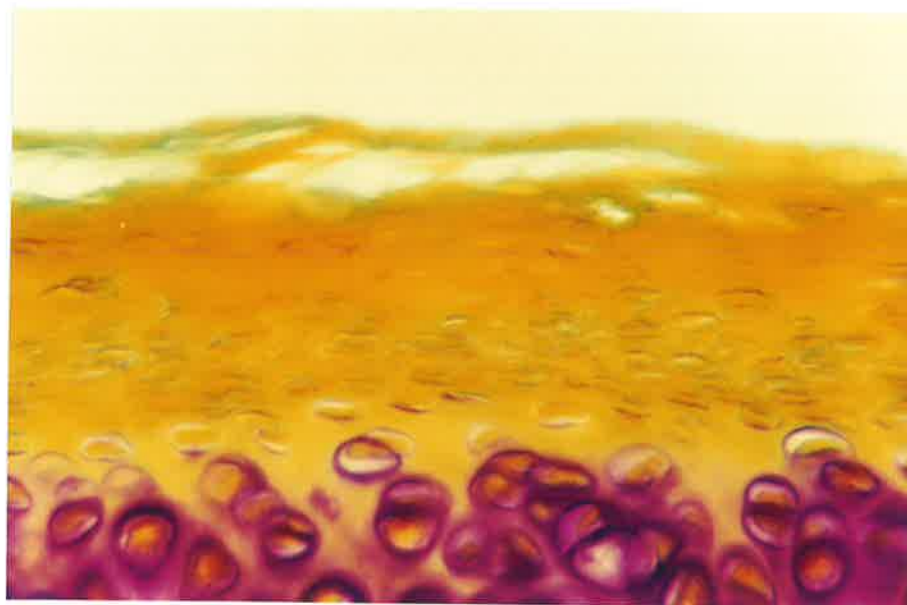


Fig. 9a. Rabbit Temporomandibular joint.

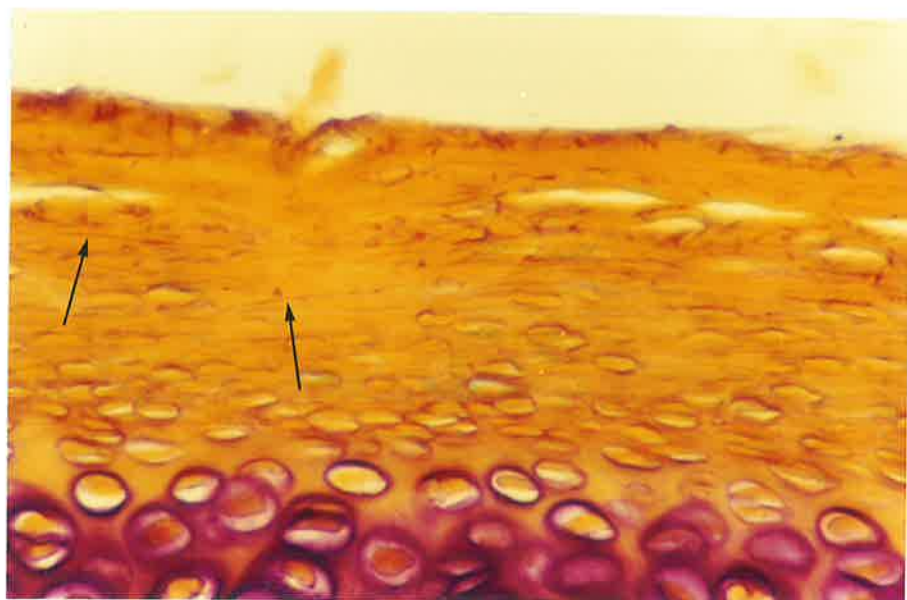
The diagram shows the articulation in sagittal section. The photomicrograph (x10) illustrates the anatomy of the articulating structures and represents the area outlined in the diagram. The articular portion of the condyle indicated in red is shown overleaf at higher magnification.



Fig. 9b. x250. Articular surface of Condyle, representing the area enclosed by the red outline in fig. 9a. Non-oxidised, Orcein-Light green stain. The letters indicate the three different tissue layers, where A = surface fibrous layer; B = fibrocartilage layer, and C = inner layer of hyaline cartilage.



Non-oxidised



Oxidised

Fig. 10a. x400. Articular surface of Condyle, Rabbit Temporo-mandibular joint (Sagittal section). Oxidised and Non-oxidised, Aldehyde fuchsin-Halmi stain. Oxytalan fibres are absent in the non-oxidised control section. In the adjacent oxidised section oxytalan fibres (arrows) run parallel to the surface, mainly in an anteroposterior direction.


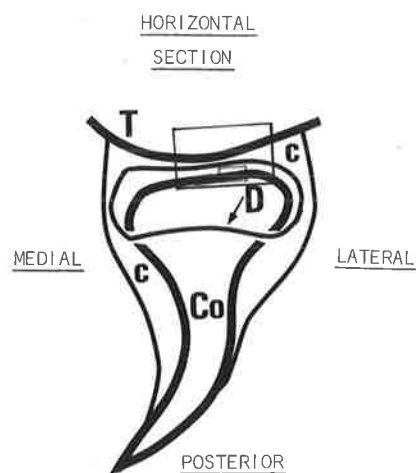


Fig. 10b. x250. Articular surface of Condyle, Rabbit Temporo-mandibular joint. (Sagittal section). Oxidised and Non-oxidised, Orcein-Light green stain. Oxytalan fibres are absent in the non-oxidised control section. In the adjacent oxidised section the arrows indicate oxytalan fibres running parallel to the surface.



T = Temporal bone      Co = Condyle  
D = Disc outline      C = Capsule

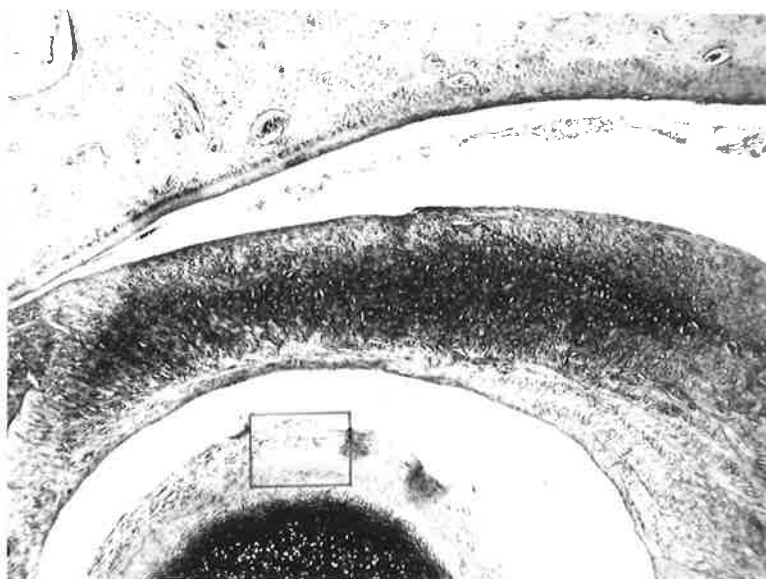


Fig. 11a. Rabbit Temporomandibular joint.

The diagram shows the component parts of the articulation in horizontal section.

The photomicrograph (x25) illustrates the anatomy of the articulating structures and represents the area outlined in the diagram.

The articular portion of the condyle indicated in red is shown overleaf at higher magnification.

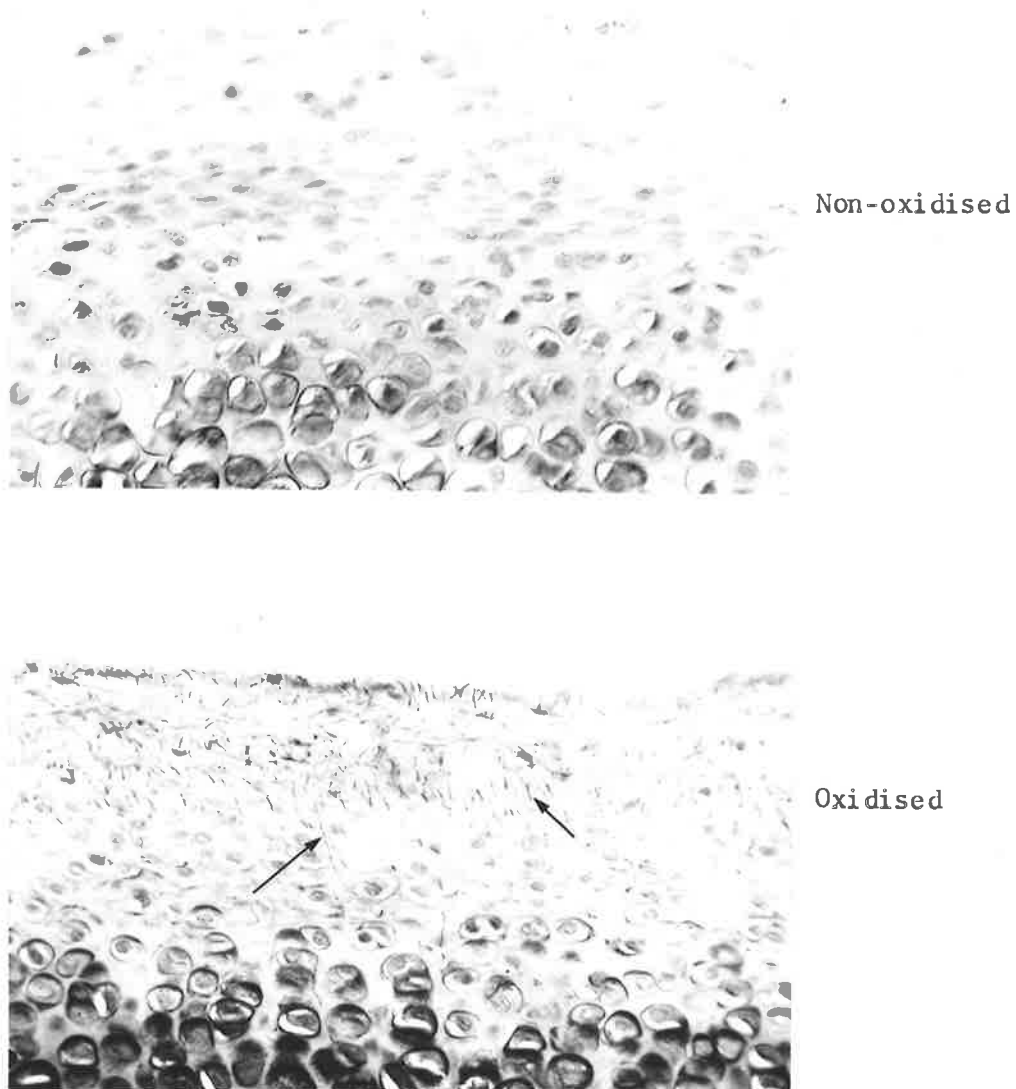


Fig. 11b. x250. Articular surface of Condyle, representing the area enclosed by the red outline in fig. 11a. Oxidised and Non-oxidised, Orcein-Light green stain. Both oxytalan and elastic fibres are absent in the non-oxidised control section. The adjacent oxidised section demonstrates oxytalan fibres (arrows) passing obliquely to the surface.

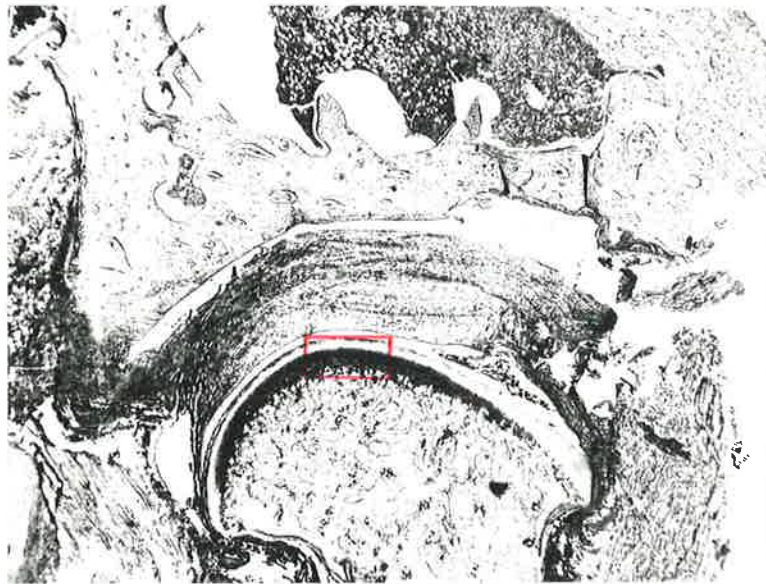
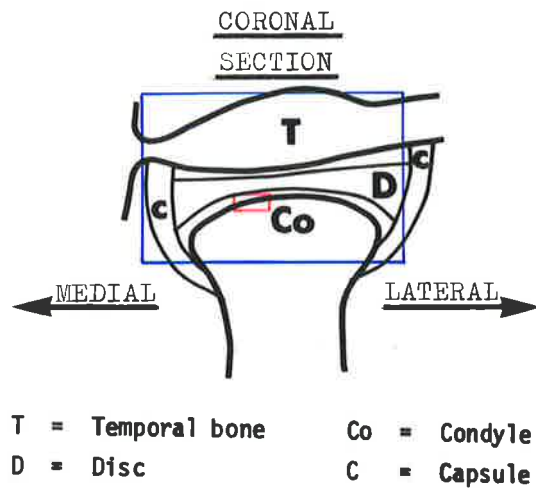


Fig. 12a. Rabbit Temporomandibular joint.  
The diagram shows the articulation in coronal section.  
The photomicrograph (x10) illustrates the anatomy of the articulating structures and represents the area outlined in the diagram.  
The articulating portion of the condyle indicated in red is shown overlaid at higher magnification.

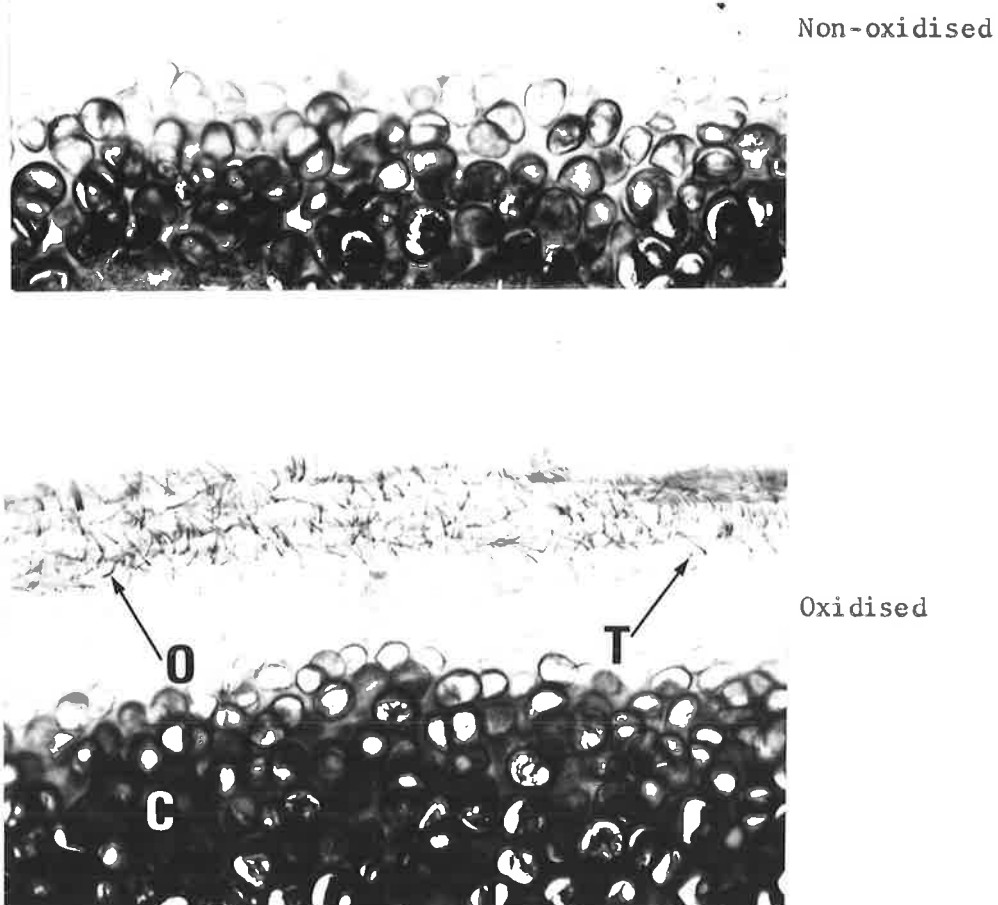


Fig. 12b. x250. Articular surface of Condyle, representing the area enclosed by the red outline in fig. 12a. Oxidised and Non-oxidised, Aldehyde fuchsin-Halmi stain. Oxytalan fibres are absent from the non-oxidised control section. The adjacent oxidised section shows oxytalan fibres in transverse (T) and oblique (O) section. C = layer of hyaline cartilage.

CONDYLE (Contd.)'Non-articular' part of the condyle

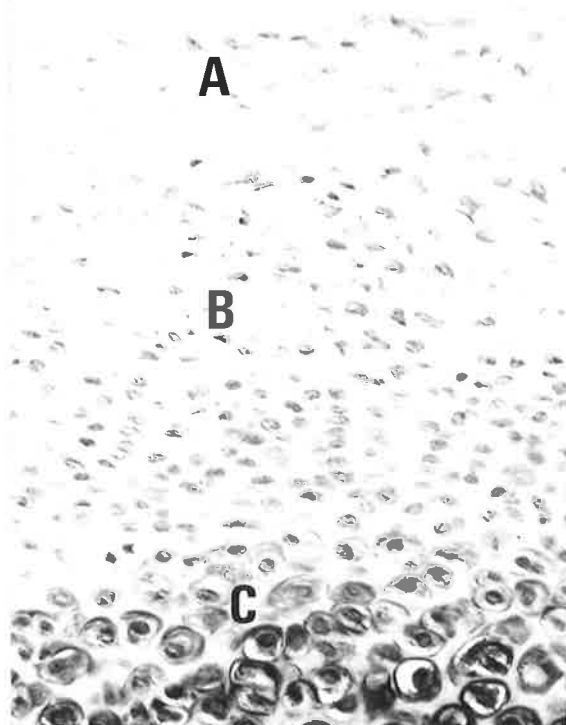
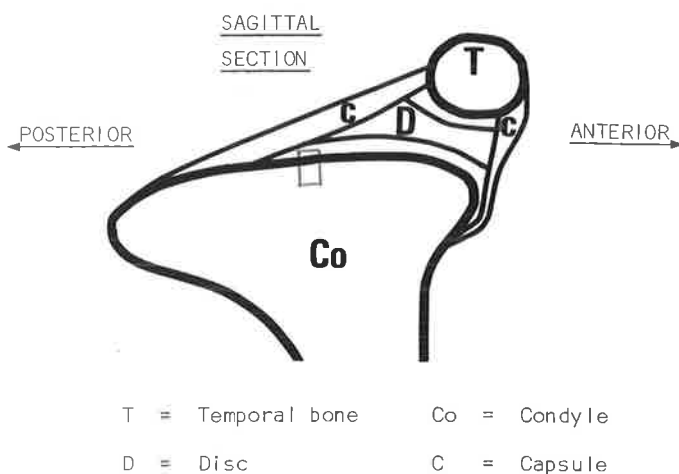
The three tissue zones found in the anterior part of the condyle are continued in the posterior 'non-articular' region, except that the fibrous and fibrocartilaginous layers are much wider.

Elastic fibres are generally absent from the non-oxidised control sections. This finding is similar to that recorded for the more anterior 'articular' part of the condyle.

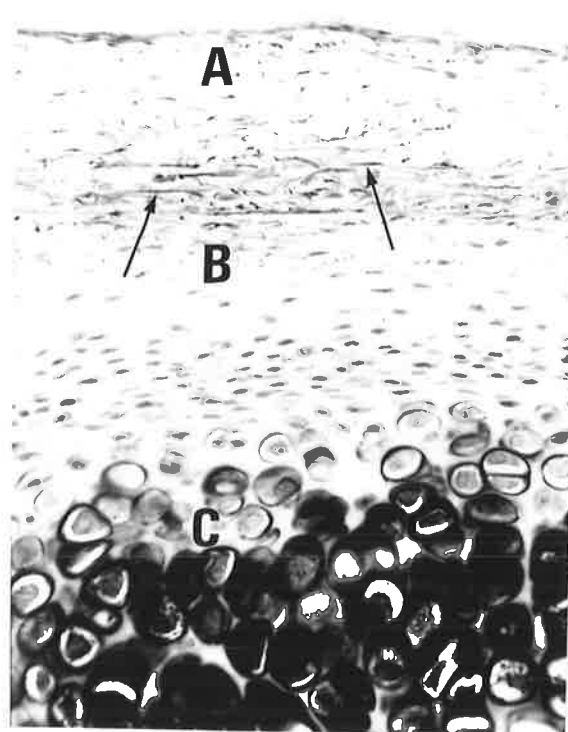
Oxytalan fibres are present and their numbers gradually become more frequent as the tissues are examined towards the posterior part of the condyle.

Approximately mid-way along the condyle the oxytalan fibres are mainly located in the surface fibrous layer close to its junction with the fibrocartilaginous layer. The fibres are arranged parallel to the surface and run predominantly in an antero-posterior direction (fig. 13).

Near the posterior extremity of the condylar surface the arrangement of the oxytalan fibres is less orderly; some pass obliquely to the surface, while others run parallel to it. The greatest concentration of fibres is still found in the region of fibrous tissue adjacent to the fibrocartilaginous layer (fig. 14).



Non-oxidised



Oxidised

Fig. 13. x250. Non-articular part of Condyle, Rabbit Temporo-mandibular joint. The region of the section is outlined in the diagram.

Oxidised and Non-oxidised, Orcein-Light green stain. Arrows indicate oxytalan fibres running parallel to the surface.

A = surface fibrous layer; B = fibrocartilage layer, C = inner layer of hyaline cartilage.



(i) THE BONY SURFACES OF THE TEMPOROMANDIBULAR JOINT (Contd.)

TEMPORAL BONE

'Articular' part of temporal bone

This region consists of a thin layer of fibrous tissue overlying bone. Oxidised tissue material demonstrates oxytalan fibres within the fibrous layer. No elastic fibres are present.

Sagittal sections show a thin superficial band of oxytalan fibres arranged parallel to the surface in an antero-posterior direction. Deep to these fibres, the oxytalan-staining elements are arranged haphazardly; some passing parallel and others obliquely to the surface (fig. 15).

Horizontal views exhibit oxytalan fibres in the fibrous layer that run mainly parallel to the surface (fig. 16).

'Non-articular' part of temporal bone

The surface fibrous layer observed in the articular part is absent and is replaced by normal periosteum. Oxytalan and elastic fibres are both absent (fig. 17).

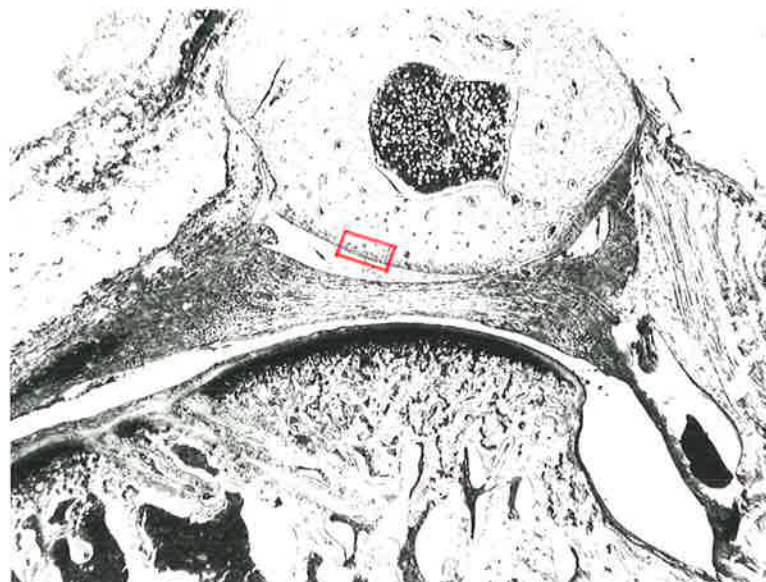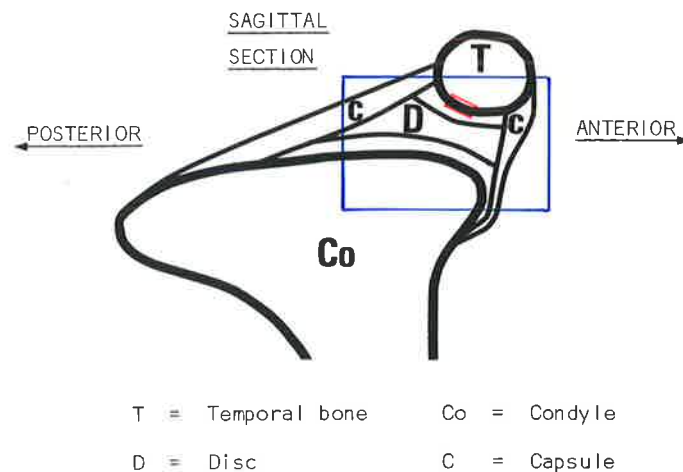


Fig. 15a. Rabbit Temporomandibular joint.

The diagram shows the component parts of the articulation in sagittal section.

The photomicrograph (x10) illustrates the anatomy of the articulating structures and represents the area outlined in the diagram above.

The articular portion of the temporal bone indicated in red is shown overleaf at higher magnification.

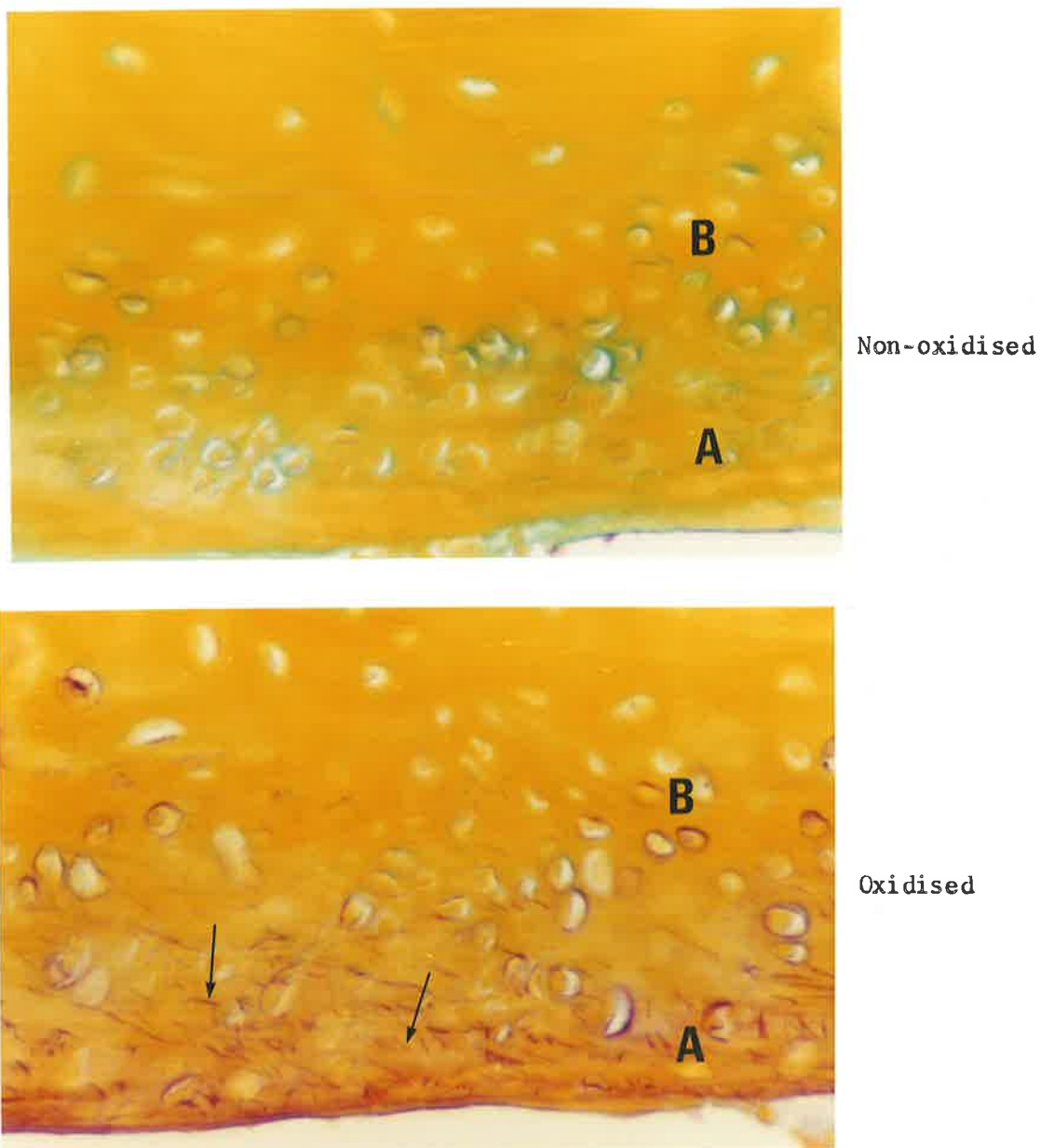
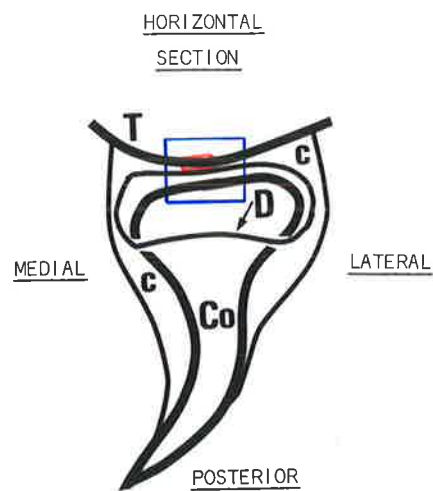


Fig. 15b. x400. Articular surface of Temporal bone, representing the area enclosed by the red outline in fig. 15a. Oxidised and Non-oxidised, Aldehyde fuchsin-Halmi stain. Fibres are absent in the non-oxidised control section. In the adjacent oxidised section, oxytalan fibres (arrows) are located in the fibrous layer overlying the bone.  
A = fibrous layer; B = bone.



T = Temporal bone	Co = Condyle
D = Disc outline	C = Capsule

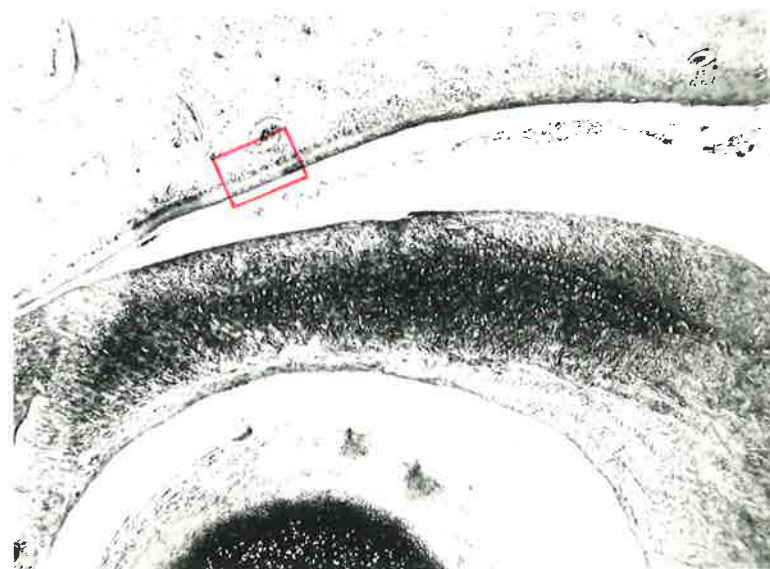


Fig. 16a. Rabbit Temporomandibular joint.  
The diagram shows the articulation in horizontal section.  
The photomicrograph (x25) illustrates the anatomy of the articulating structures and represents the area outlined in the diagram.  
The articular portion of the temporal bone indicated in red is shown overleaf at higher magnification.

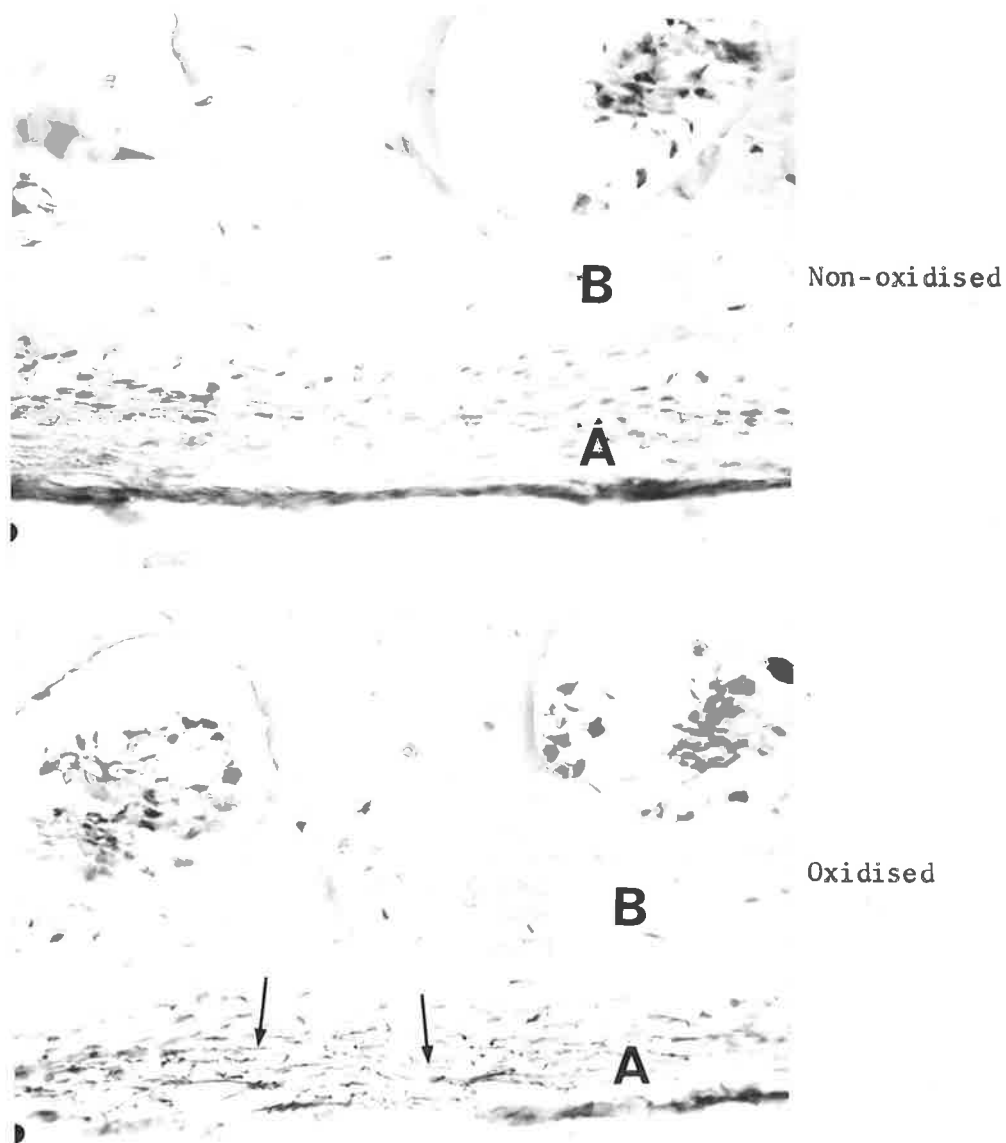


Fig. 16b. x250. Articular surface of Temporal bone representing the area enclosed by the red outline in fig. 16a. Oxidised and Non-oxidised, Orcein-Light green stain. Oxytalan fibres are absent in the non-oxidised control section. In the adjacent oxidised section oxytalan fibres (arrows) run parallel to the surface. A = fibrous layer; B = bone.



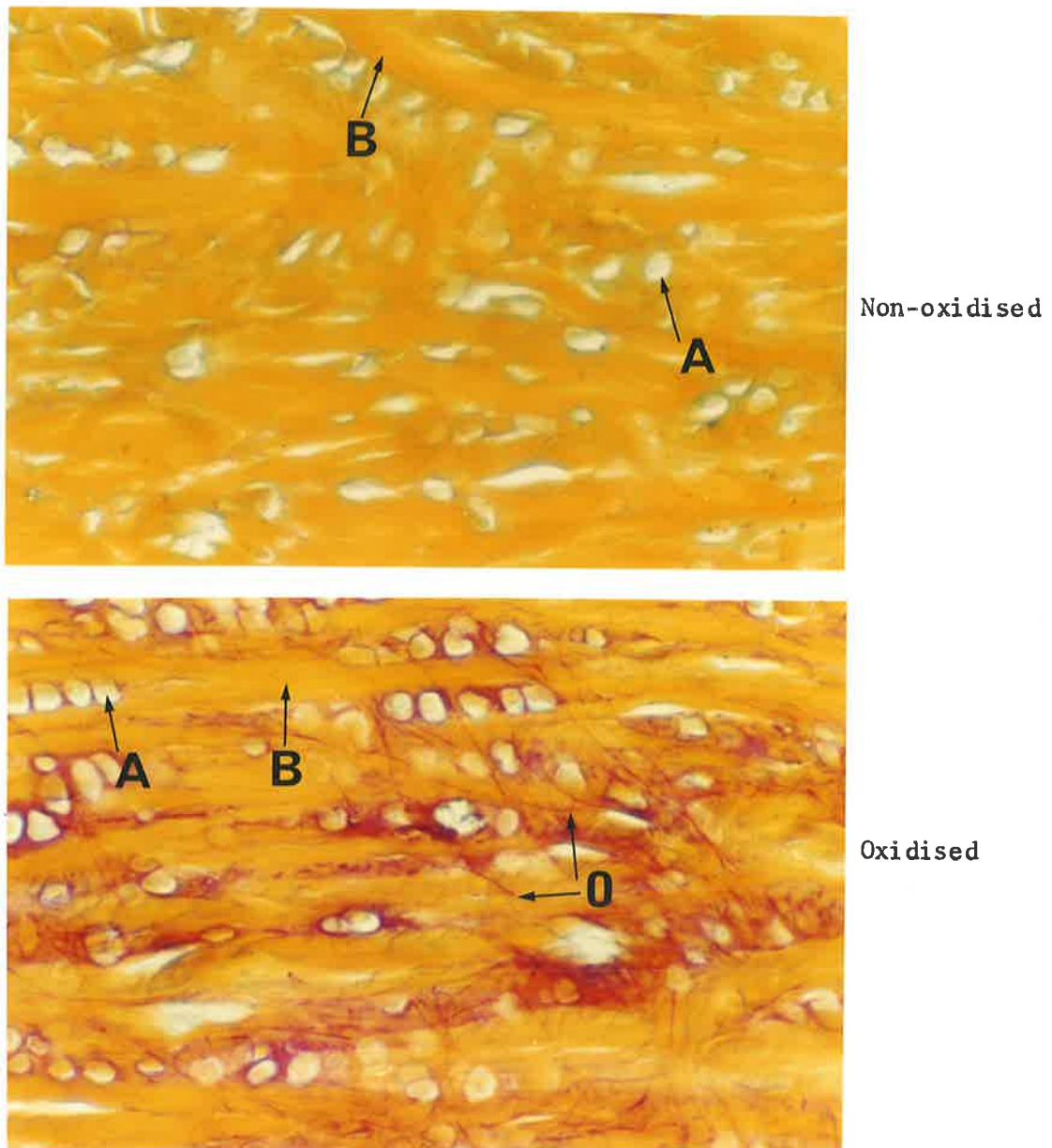
(ii) THE ARTICULAR DISC OF THE TEMPOROMANDIBULAR JOINT

The articular disc of the rabbit temporomandibular joint is an avascular structure composed of dense fibrocartilaginous tissue. The cells, which appear similar to cartilage cells, are arranged either singly or in typical cell 'nests' that run parallel with the bundles of collagen fibres in an antero-posterior direction (fig. 18).

Aldehyde fuchsin-stained sections demonstrate that the mucopolysaccharide matrix, normally surrounding maturing chondrocytes, is partly present around the cartilage-like cells of the disc. However, typical cartilage tissue is not evident. Elastic fibres are not present in the disc, but in the oxidised sections many fine branching fibres are seen. These oxytalan-staining fibres do not appear to have any particular orientation; some pass at right-angles to the collagen bundles, while others run parallel with them (figs. 19,20).

Orcein-stained sections confirm the presence of oxytalan fibres and the absence of any elastic fibres in the disc (figs. 21,22).





**Fig. 19.** x400. Articular Disc, Rabbit Temporomandibular joint (Sagittal section). Oxidised and Non-oxidised, Aldehyde fuchsin-Halmi stain. Oxytalan fibres are absent in the non-oxidised control section. In the adjacent oxidised section oxytalan fibres (O) are present. A = cartilage-like cells; B = collagen bundles.

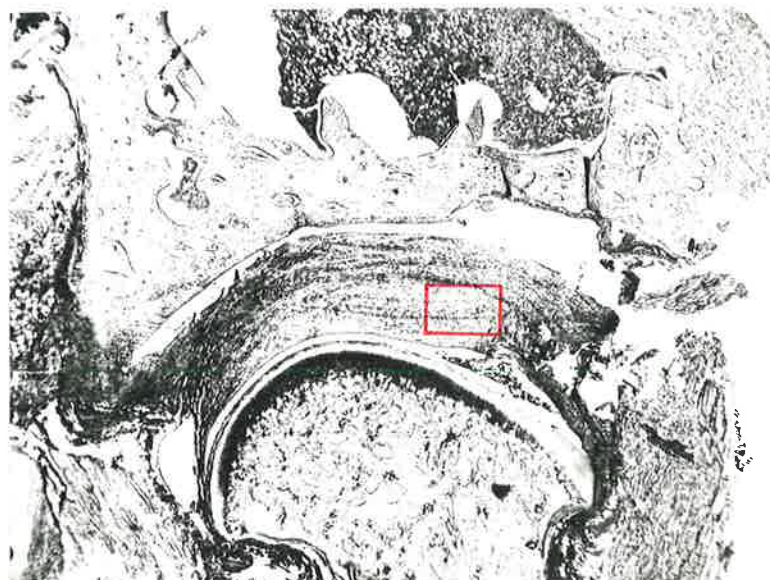
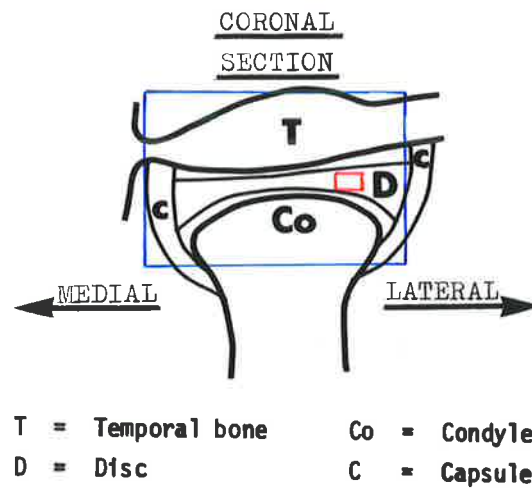


Fig. 20a. Rabbit Temporomandibular joint.  
The diagram shows the articulation in coronal section.  
The photomicrograph (x10) illustrates the anatomy of the articulating structures and represents the area outlined in the diagram.  
The portion of the articular disc indicated in red is shown overleaf at higher magnification.


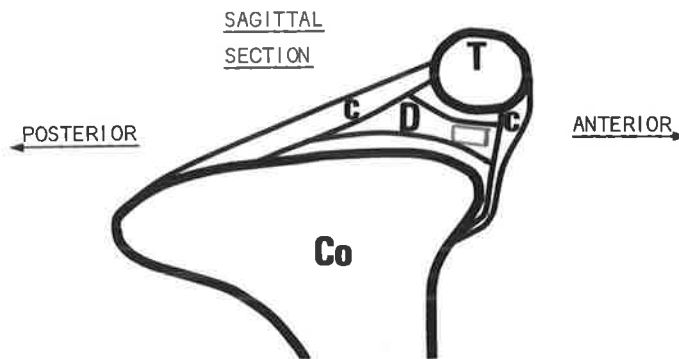


Fig. 20b. x250. Articular Disc, representing the area enclosed by the red outline in fig. 20a. Oxidised and Non-oxidised, Aldehyde fuchsin-Halmi stain. Oxytalan fibres (arrows) are orientated at random throughout the disc in the oxidised section. The fibres are not present in the adjacent non-oxidised control section.



T = Temporal bone      Co = Condyle  
D = Disc                      C = Capsule




Fig. 21. x250. Articular Disc, Rabbit Temporomandibular joint. The region of the section is outlined in the diagram. Oxidised and Non-oxidised, Orcein-Light green stain. Oxytalan fibres are absent in the non-oxidised control section. Many fine oxytalan fibres are present in the adjacent oxidised section. Branching of these fibres is seen occasionally (arrows).

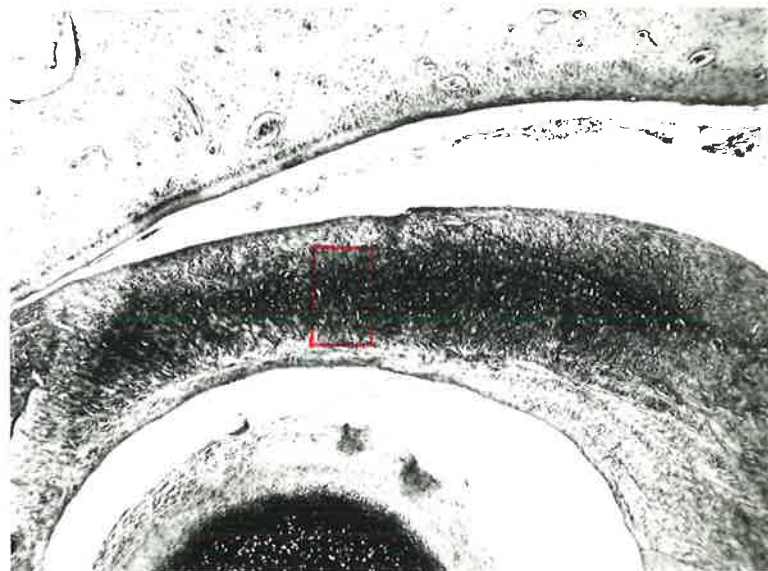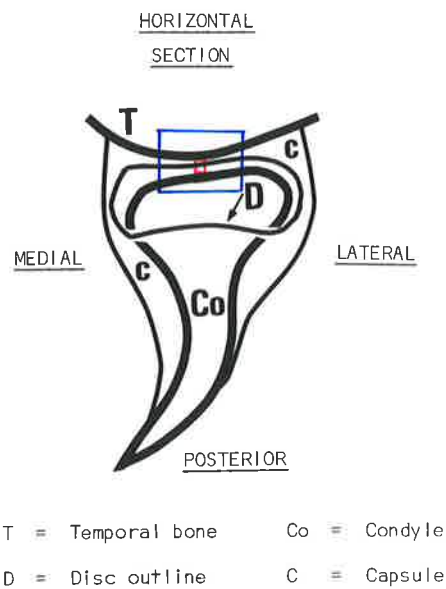


Fig. 22a. Rabbit Temporomandibular joint.

The diagram shows the articulation in horizontal section. The photomicrograph (x25) illustrates the anatomy of the articulating structures and represents the area outlined in the diagram.

The articular disc indicated in red is shown overleaf at higher magnification.

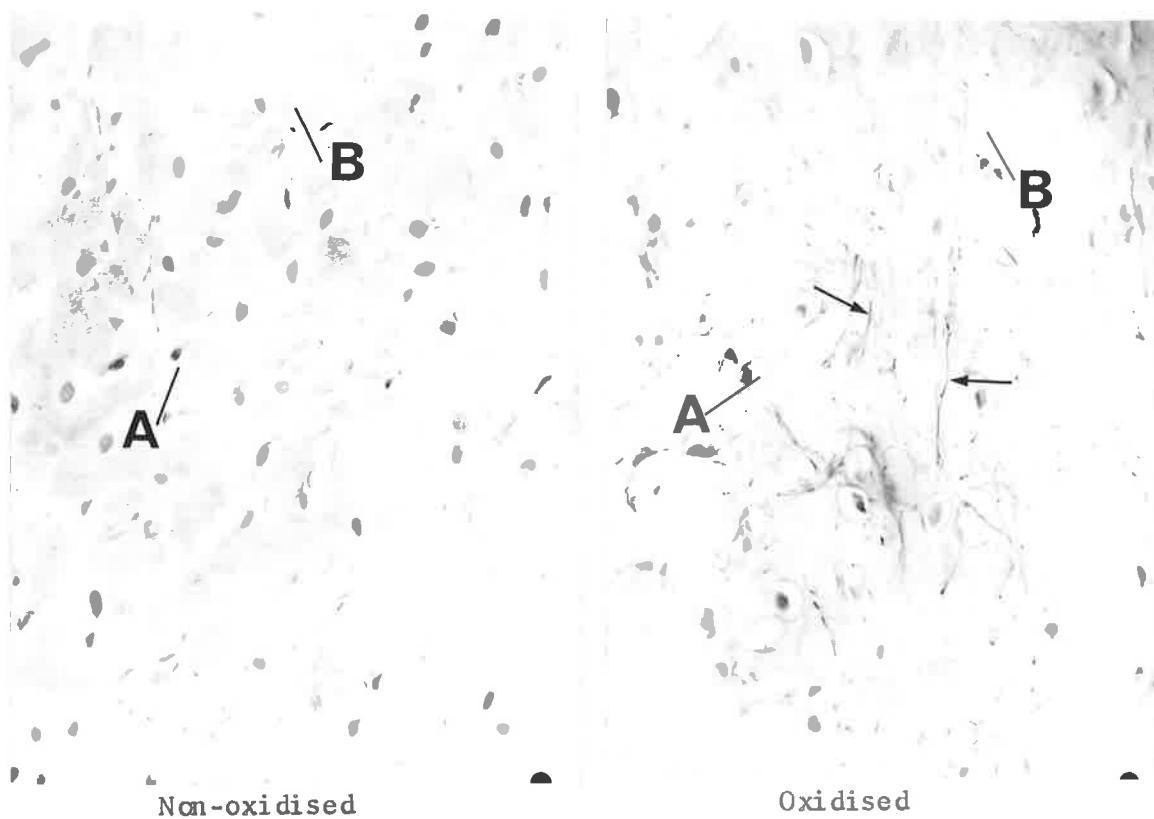


Fig. 22b. x250. Articular Disc, representing the area enclosed by the red outline in fig. 22a. Oxidised and Non-oxidised, Orcein-Light green stain. Oxytalan fibres are absent from the non-oxidised control section. The adjacent oxidised section contains oxytalan fibres (arrows). The distribution of the fibres is random. A = Cartilage-like cells; B = collagen bundles.

(iii) THE CAPSULE OF THE TEMPOROMANDIBULAR JOINT

The capsule may be structurally divided into anterior and posterior parts. The anterior portion is further delineated into an upper and lower division adjacent to the area where it merges with the disc.

Anterior part of Capsule

A well-developed fatty connective tissue layer, together with vascular and neural elements, is present between the most anterior part of the capsule and the temporalis muscle (fig. 23).

Fibres of the lateral pterygoid muscle attach to the antero-medial part of the capsule, while antero-laterally the capsule is closely related to the masseter muscle (fig. 24).

(a) Upper division

The upper division consists of dense collagenous connective tissue containing only a few blood vessels and elastic fibres. Numerous oxytalan fibres are present which generally run parallel with the collagen bundles. Sagittal sections show oblique and transverse views of the collagen and oxytalan fibres (fig. 25).



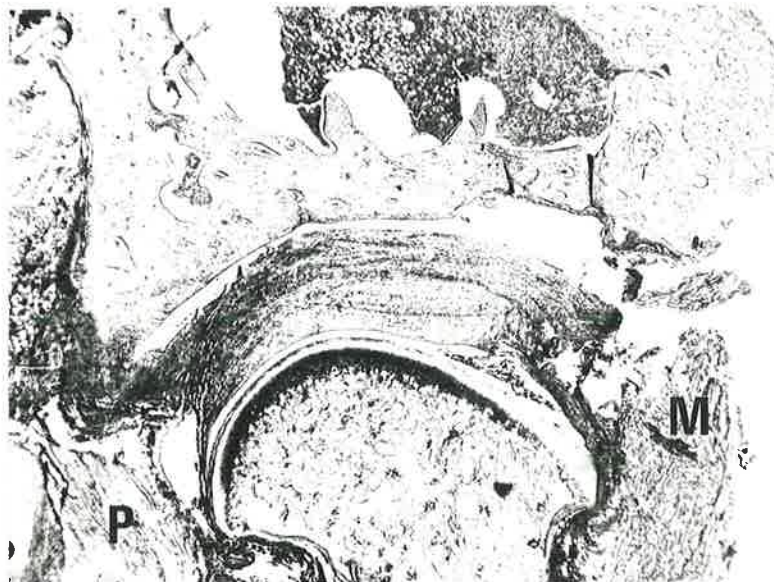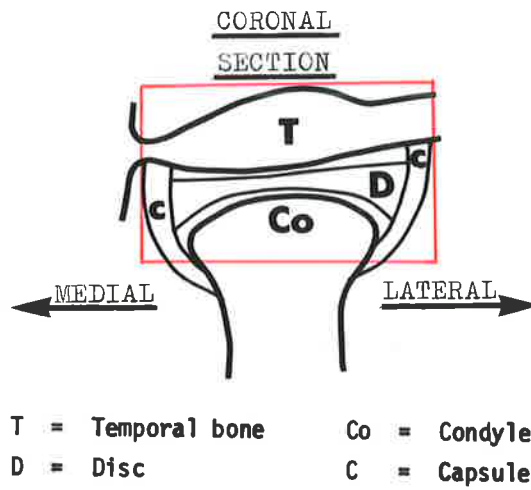


Fig. 24.    x10.    Rabbit Temporomandibular joint.  
The region of the section is outlined in the diagram.  
Non-oxidised, Aldehyde fuchsin-Halmi stain.  
P = lateral pterygoid muscle; M = masseter muscle.

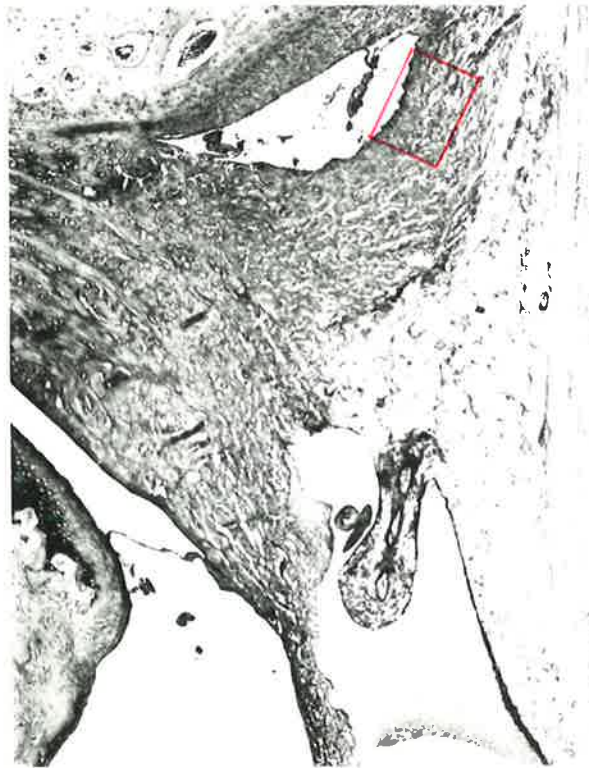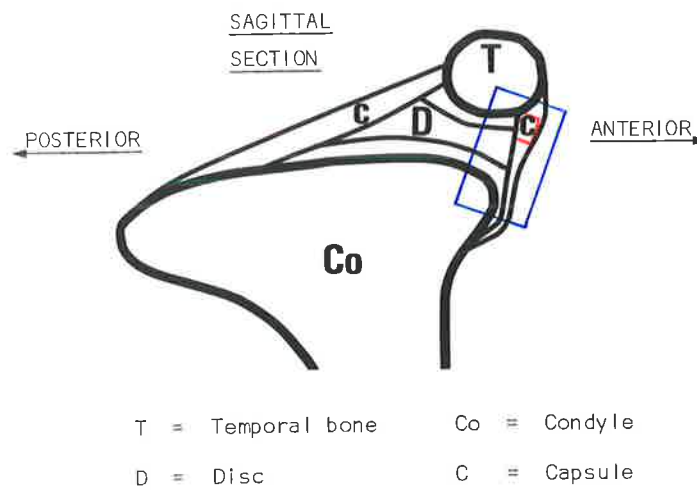


Fig. 25a. Rabbit Temporomandibular joint.  
The diagram shows the articulation in sagittal section.  
The photomicrograph (x40) illustrates the anatomy of  
the anterior portion of the articulation and represents  
the area outlined in the diagram.  
The portion of the capsule indicated in red is shown  
overleaf at higher magnification.

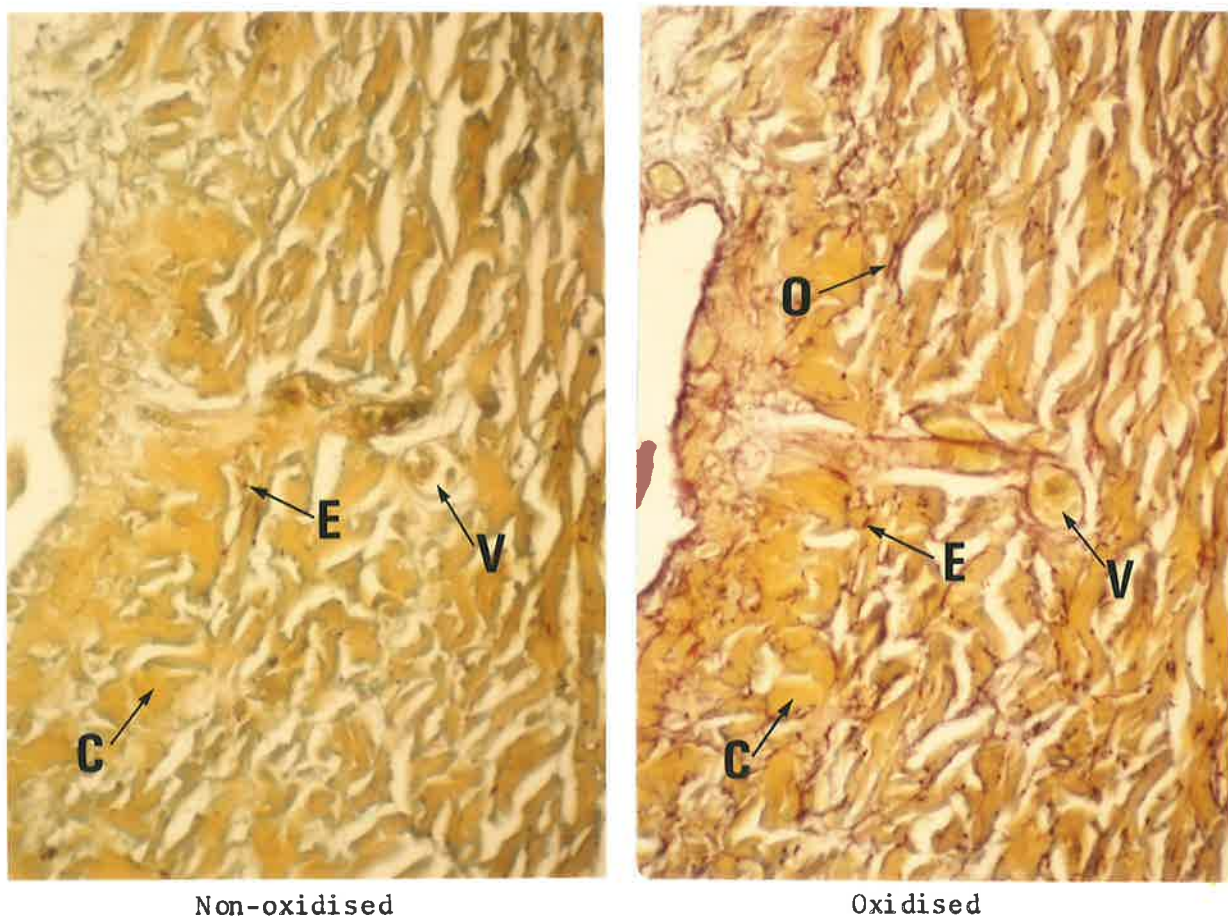


Fig. 25b. x250. Anterior part of Capsule, representing the area enclosed by the red outline in fig. 25a. Oxidised and Non-oxidised, Aldehyde fuchsin-Halmi stain. Elastic fibres (E) are present in the non-oxidised control section. In the adjacent oxidised section oxytalan fibres (O) as well as elastic fibres are found. Transverse views of the fibres are mainly seen. C = collagen bundle; V = venule.

(a) Upper division (Contd.)

Coronal sections show that the dense collagenous connective tissue of the capsule's upper division is continued on the antero-medial aspect of the joint. Oxytalan fibres are present and there is an absence of elastic fibres. The oxytalan fibres are sectioned transversely, indicating that they are arranged parallel with the collagen bundles in an antero-posterior direction (fig. 26).

The dense connective tissue of the upper division does not continue antero-laterally, but is replaced by a thin band of loose connective tissue consisting mainly of collagen and oxytalan-staining fibres. Elastic fibres are not present. This finding is similar to that noted for the antero-medial aspect. The oxytalan fibres are arranged in a less orderly fashion to that observed antero-medially. Some fibres are seen in transverse section, while others run more obliquely (fig. 27).

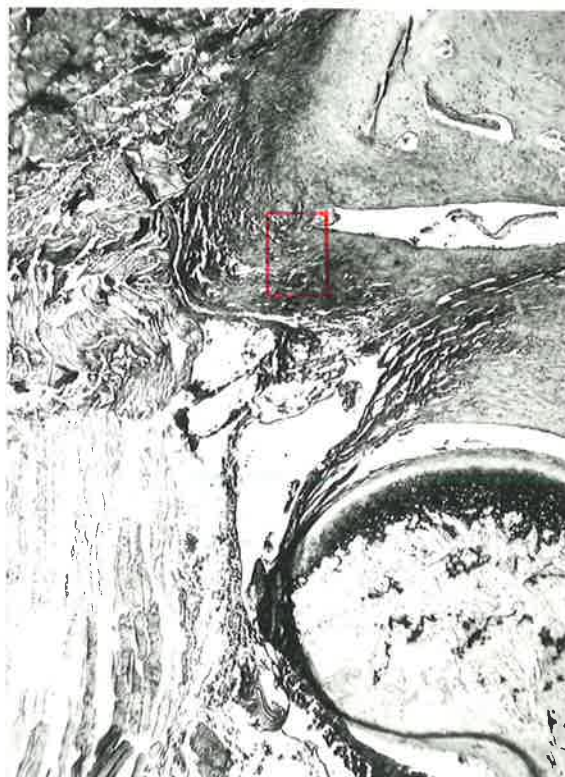
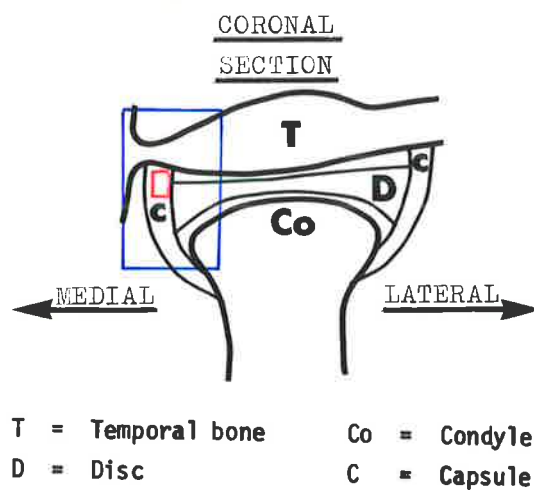


Fig. 26a. Rabbit Temporomandibular joint.  
The diagram shows the articulation in coronal section. The photomicrograph (x40) illustrates the anatomy of the antero-medial portion of the articulation and represents the area outlined in the diagram. The portion of the capsule indicated in red is shown overleaf at higher magnification.




Fig. 26b. x250. Antero-medial part of Capsule, representing the area enclosed by the red outline in fig. 26a. Oxidised and Non-oxidised, Aldehyde fuchsin-Halmi-stain. Oxytalan fibres are absent in the non-oxidised control section. In the adjacent oxidised section oxytalan fibres (arrows) are numerous.

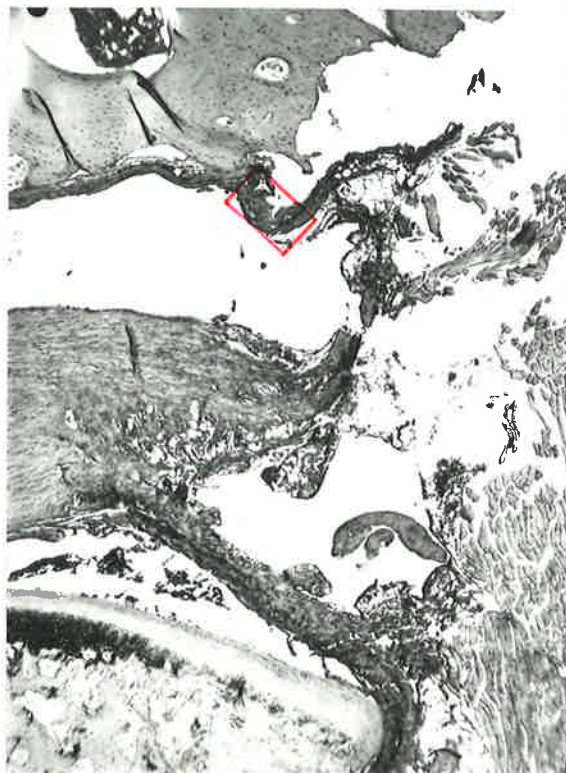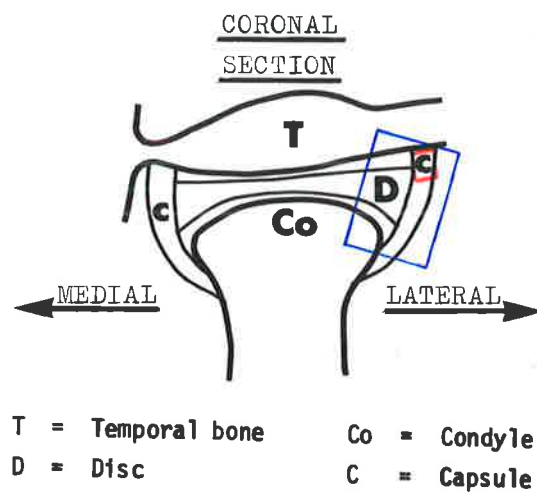


Fig. 27a. Rabbit Temporomandibular joint.  
The diagram shows the articulation in coronal section.  
The photomicrograph (x40) illustrates the anatomy of the anterolateral portion of the articulation and represents the area outlined in the diagram.  
The portion of the capsule indicated in red is shown overleaf at higher magnification.

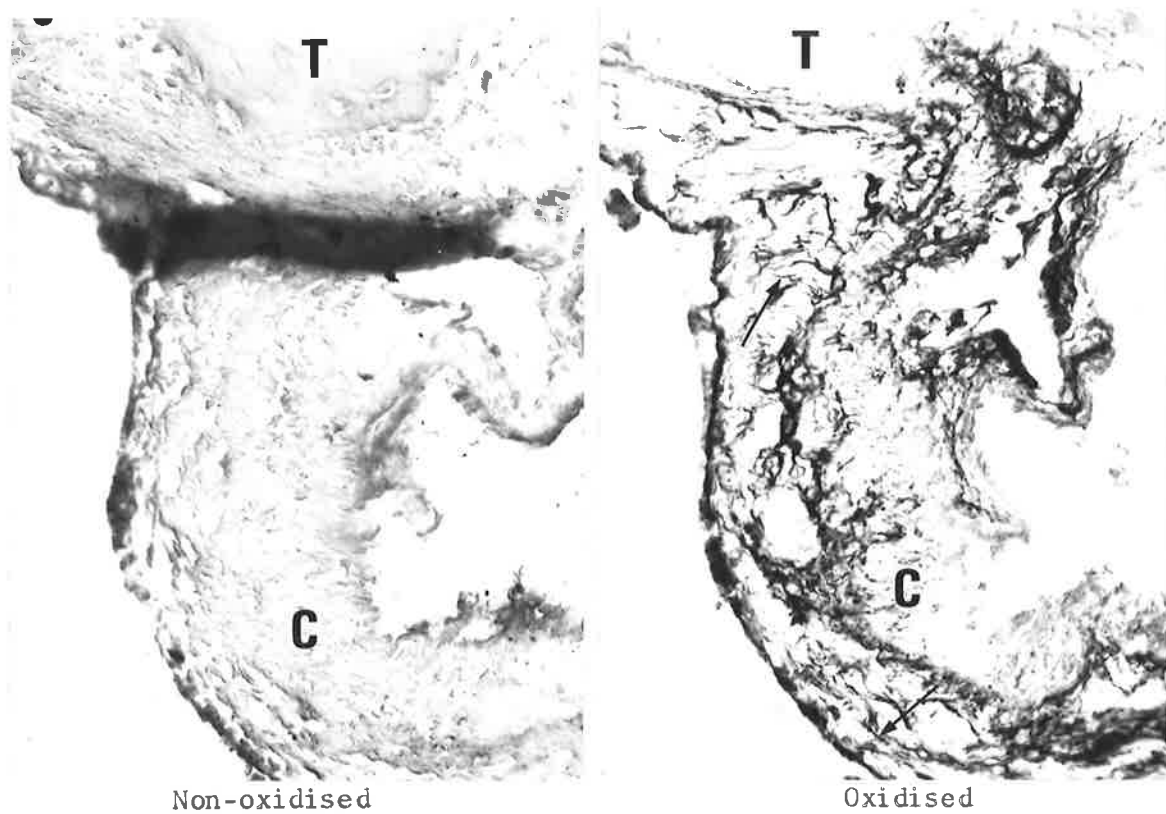


Fig. 27b. x250. Antero-lateral part of Capsule, representing the area enclosed by the red outline in fig. 27a. Oxidised and Non-oxidised, Aldehyde fuchsin-Halmi stain. Oxytalan fibres are absent in the non-oxidised control section. In the adjacent oxidised section oxytalan fibres (arrows) are distributed at random throughout the loose connective tissue. T = temporal bone; C = loose connective tissue of capsule.

### Anterior part of Capsule (Contd.)

#### (b) Lower division

In contrast to the upper division, the connective tissue of the lower division is less dense and contains abundant elastic fibres. Vascular and neural elements are also more numerous. A comparison of oxidised and non-oxidised tissue sections shows that oxytalan fibres are not present.

Sagittal views demonstrate elastic fibres mainly in cross-section running parallel with the collagen bundles in a medio-lateral direction (fig. 28).

The loose connective tissue of the lower division is continued medially and laterally from the most anterior part of the capsule.

Coronal views show elastic fibres in cross-section travelling in an antero-posterior direction with the collagen bundles. The lateral side of the lower division of the capsule does not have any oxytalan fibres (fig. 29).

The medial counterpart, however, contains a significant number of oxytalan-staining elements intermingled with the elastic fibres (fig. 30).

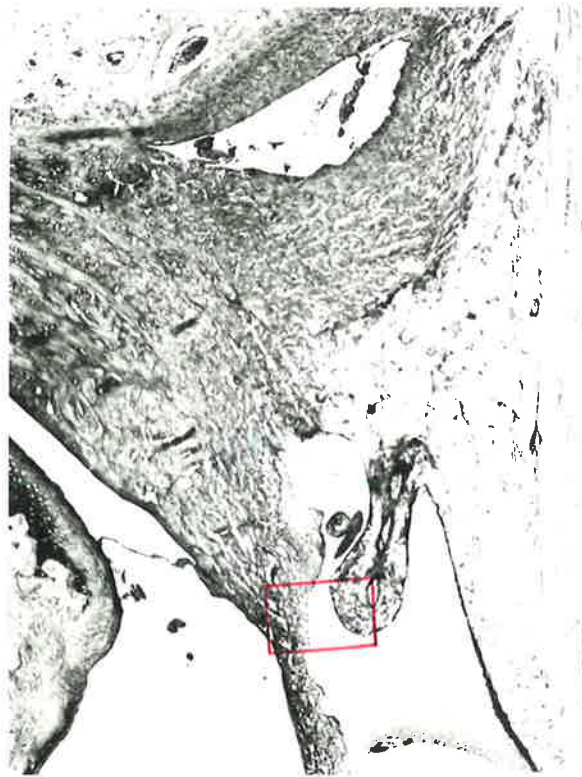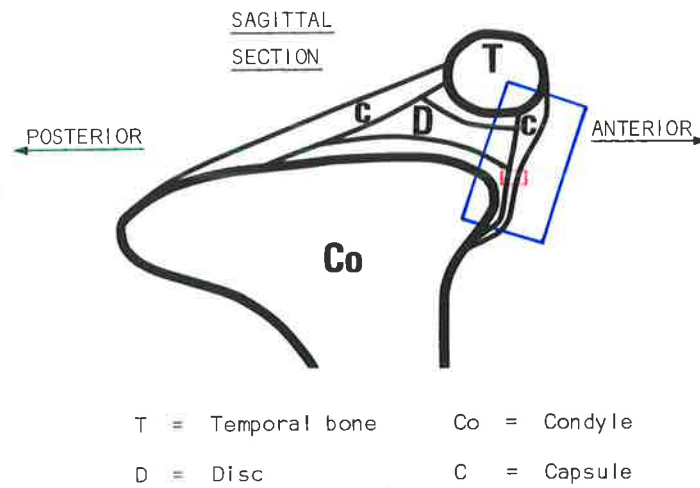


Fig. 28a. Rabbit Temporomandibular joint. The diagram shows the articulation in sagittal section. The photomicrograph (x40) illustrates the anatomy of the anterior portion of the articulation and represents the area outlined in the diagram. The portion of the capsule indicated in red is shown overleaf at higher magnification.

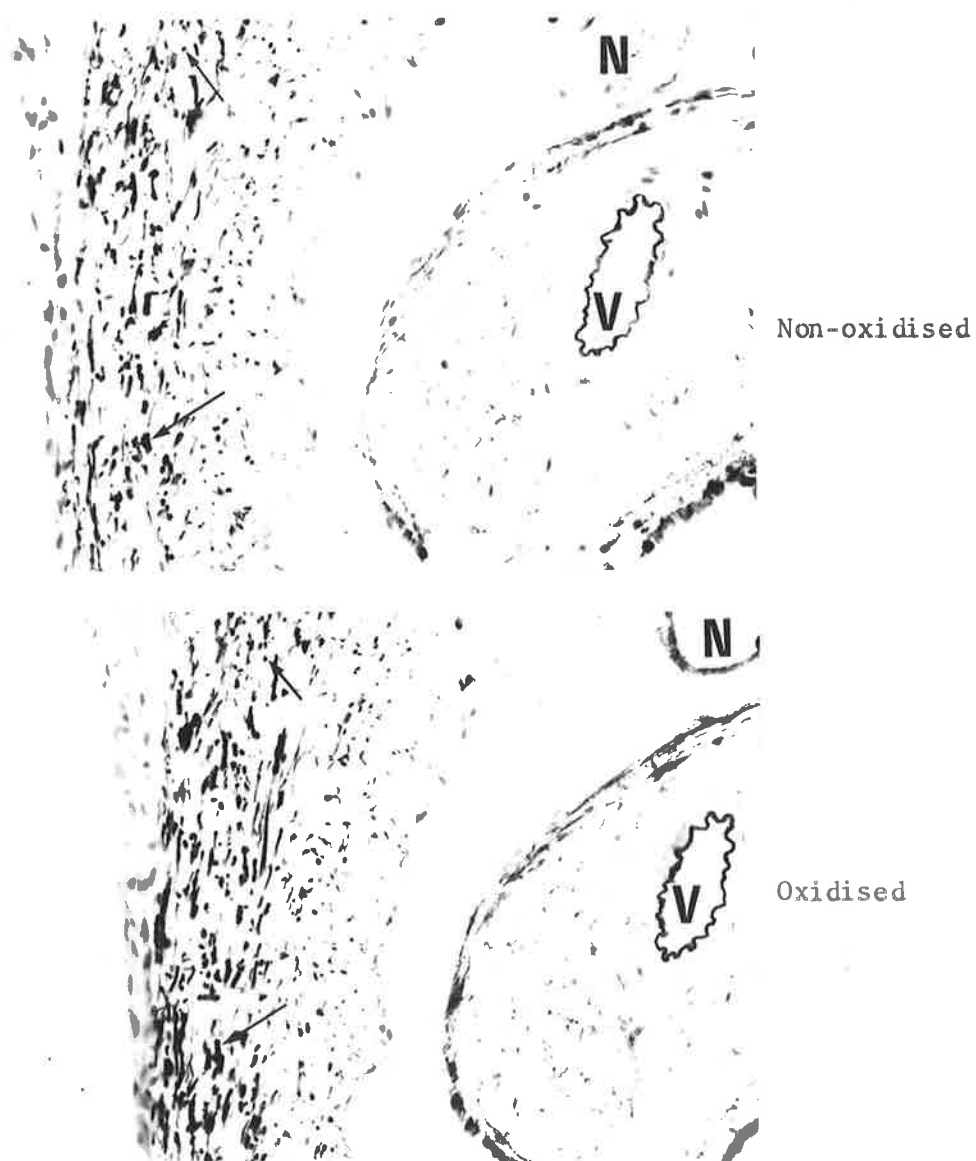


Fig. 28b. x250. Anterior part of Capsule, representing the area enclosed by the red outline in fig. 28a. Oxidised and Non-oxidised, Orcein-Light green stain. Elastic fibres are present in the non-oxidised control section. Since no additional fibres are present in the adjacent oxidised section, oxytalan fibres are absent. The arrows indicate elastic fibres cut transversely. N = small nerve; V = small artery.

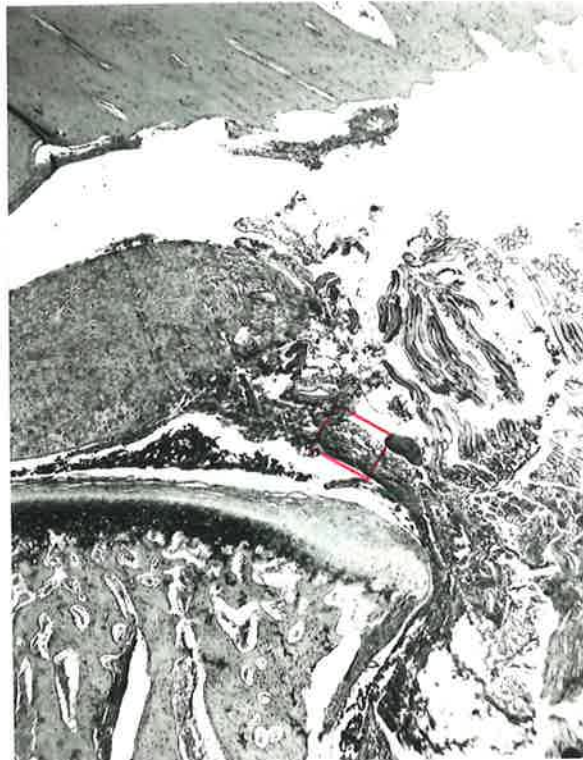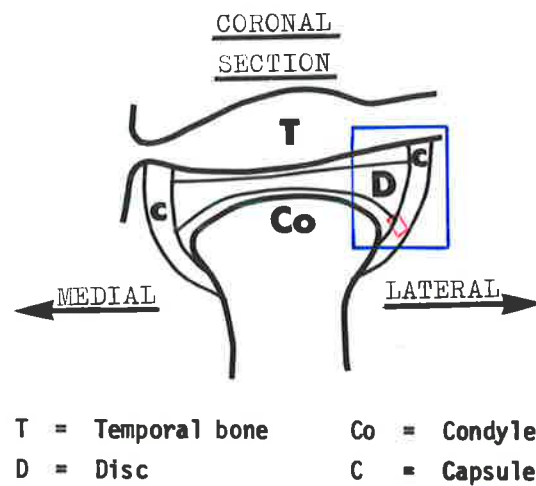


Fig. 29a. Rabbit Temporomandibular joint.

The diagram shows the articulation in coronal section. The photomicrograph (x40) illustrates the anatomy of the antero-lateral portion of the articulation and represents the area outlined in the diagram. The portion of the capsule indicated in red is shown overlaid at higher magnification.

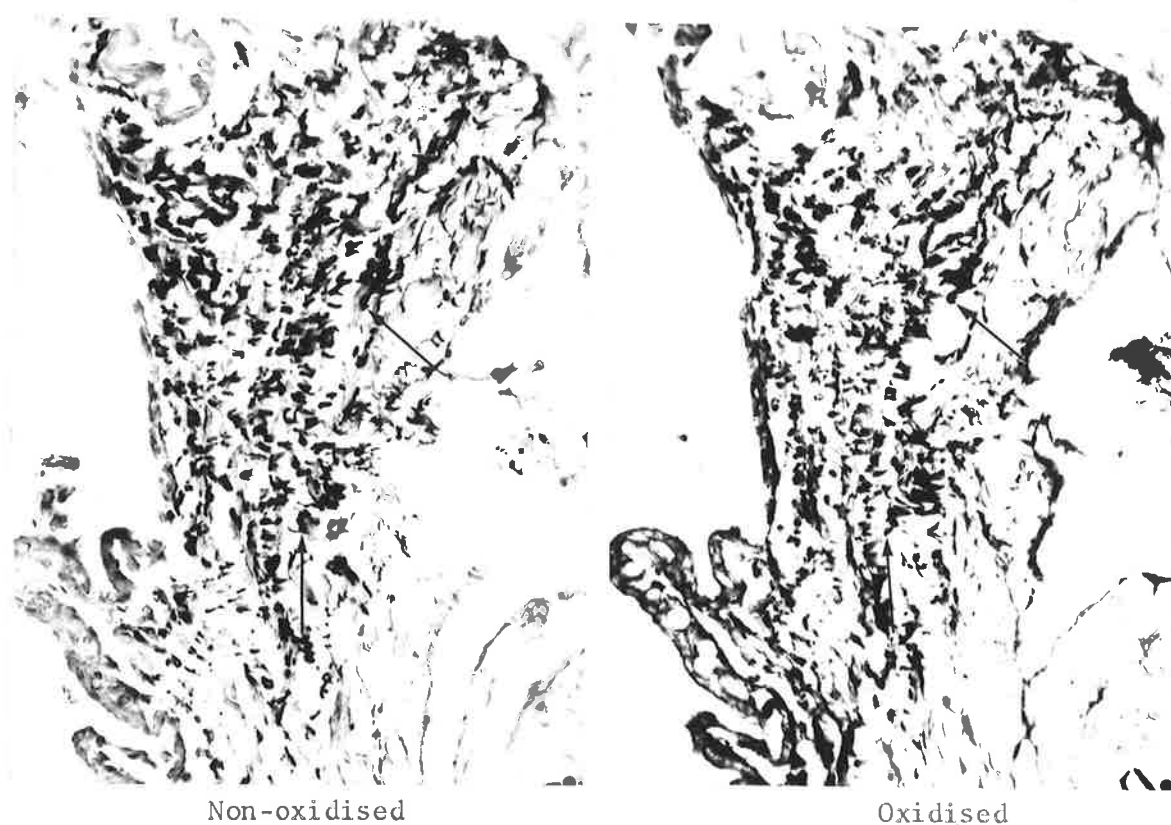


Fig. 29b. x250. Antero-lateral part of Capsule, representing the area enclosed by the red outline in fig. 29a. Oxidised and Non-oxidised, Aldehyde fuchsin-Halmi stain.

Elastic fibres (arrows) are present in both the non-oxidised control section and the adjacent oxidised section. Oxytalan fibres are absent.

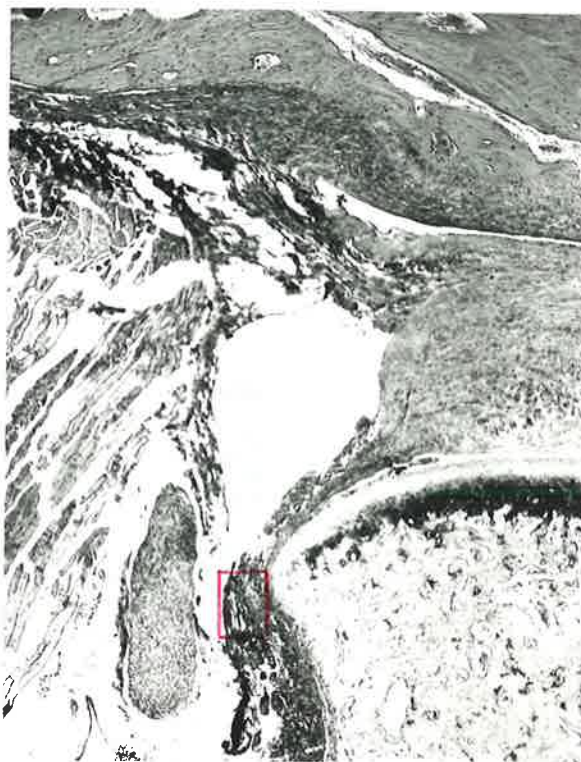
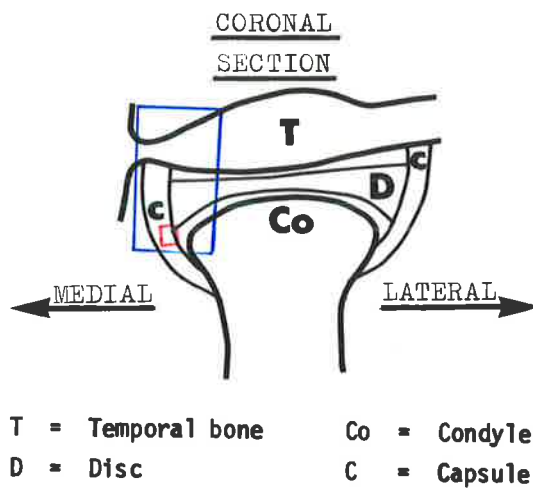


Fig. 30a. Rabbit Temporomandibular joint.  
The diagram shows the articulation in coronal section.  
The photomicrograph (x40) illustrates the anatomy of  
the antero-medial portion of the articulation and  
represents the area outlined in the diagram.  
The portion of the capsule indicated in red is shown  
overleaf at higher magnification.




Fig. 30b. x250. Antero-medial part of Capsule, representing the area enclosed by the red outline in fig. 30a. Oxidised and Non-oxidised, Aldehyde fuchsin-Halmi stain.

Elastic fibres are present in the non-oxidised control section. In the adjacent oxidised section oxytalan fibres also occur - the increased amount of darkly staining material is oxytalan.

E = elastic fibres; O = oxytalan fibres; V = venule.

### Posterior part of Capsule

This division of the capsule extends from the posterior region of the temporal bone to the back of the condyle.

It consists chiefly of loose, vascular connective tissue containing a large number of elastic fibres together with some oxytalan-staining elements.

Sagittal views of the capsule show elastic and oxytalan fibres orientated parallel with the collagen bundles in a predominantly antero-posterior direction (fig. 31).

Horizontal views of the same area also demonstrate both elastic and oxytalan fibres running antero-posteriorly (fig. 32).



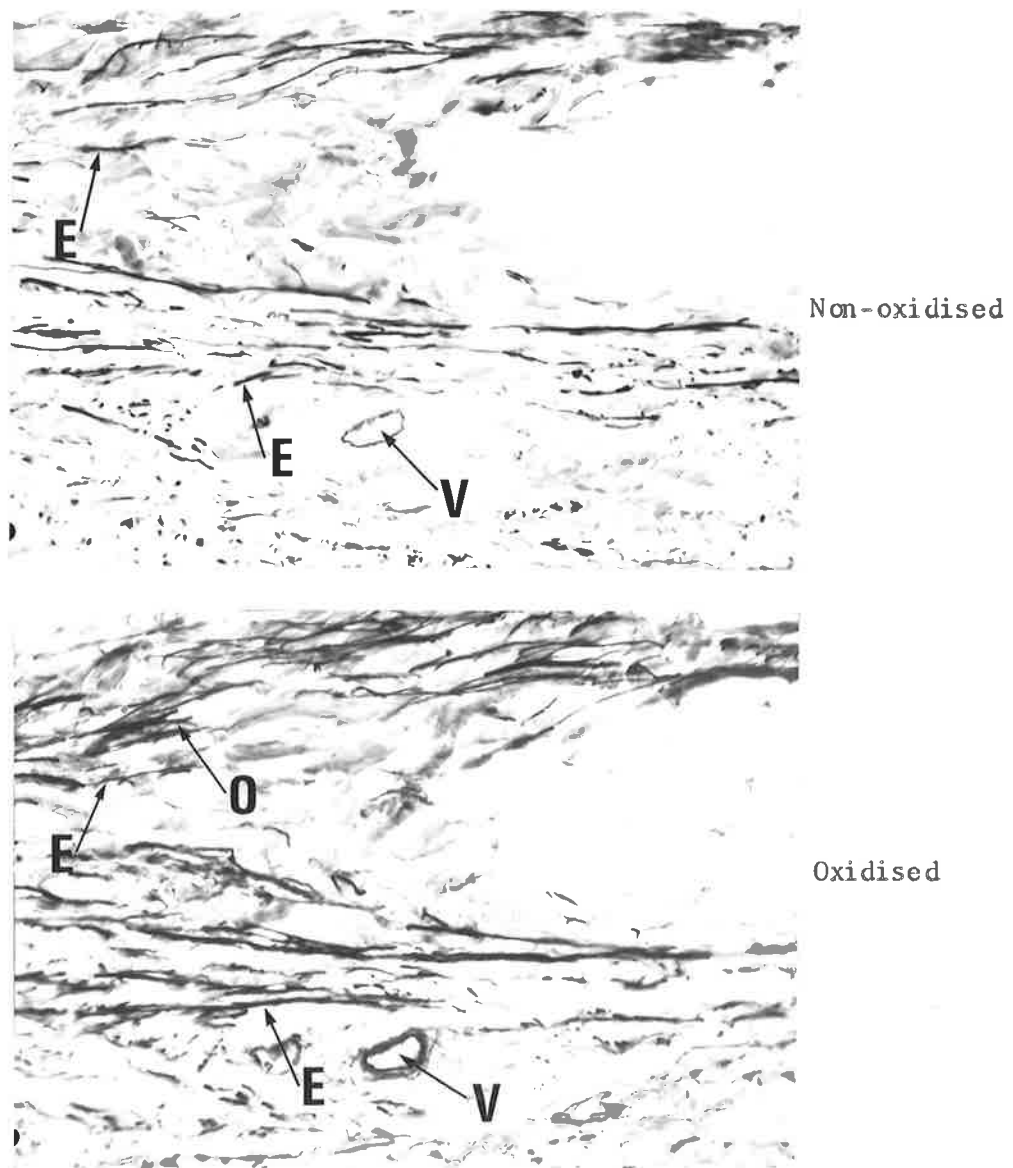


Fig. 31b. x250. Posterior part of Capsule, representing the area enclosed by the red outline in fig. 31a. Oxidised and Non-oxidised, Aldehyde fuchsin-Halmi stain. Elastic fibres are present in the non-oxidised control section. The additional fibres seen in the adjacent oxidised section are oxytalan. Both fibre types are seen mainly in longitudinal section. E = elastic fibres; O = oxytalan fibres; V = small artery.

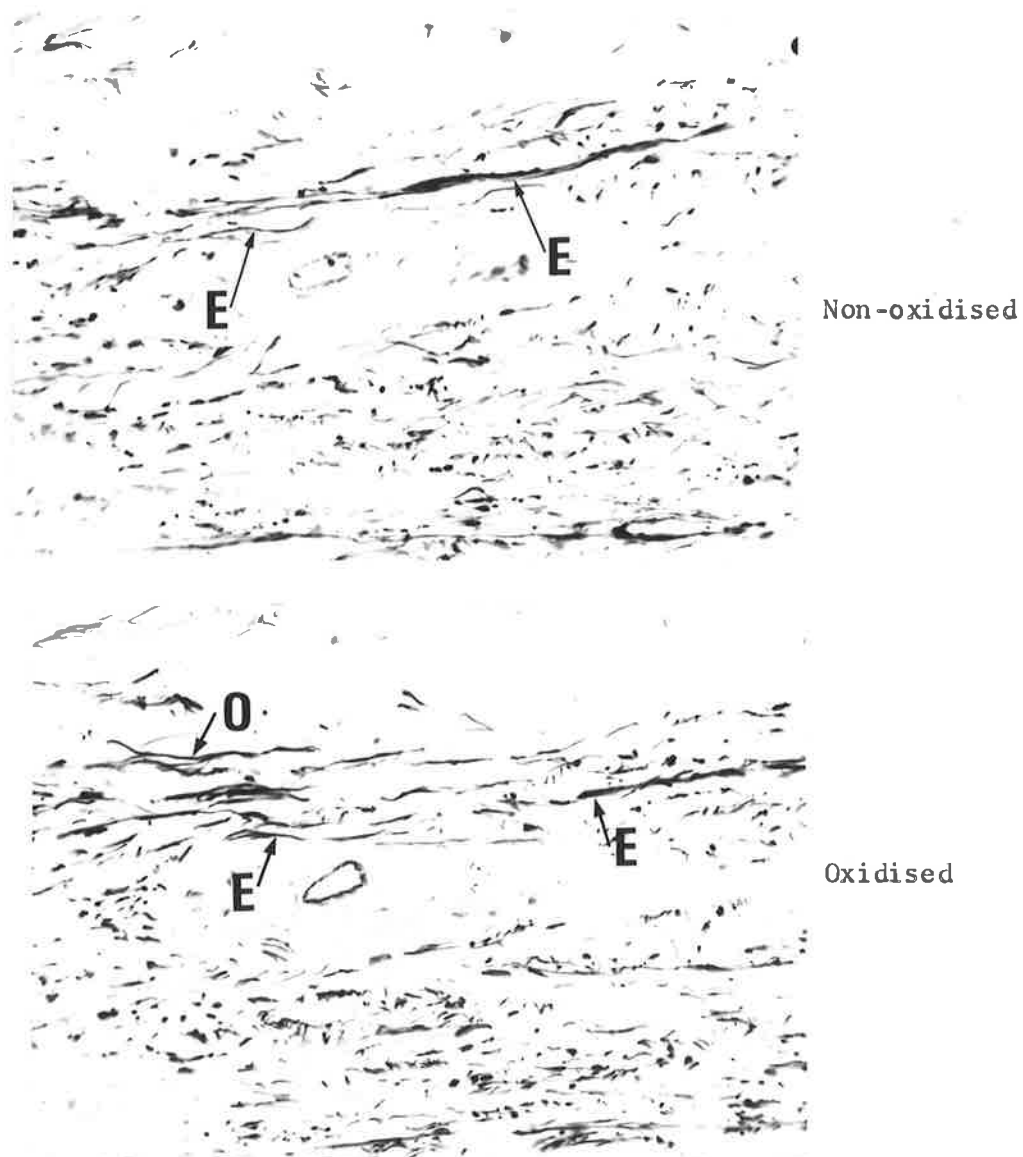
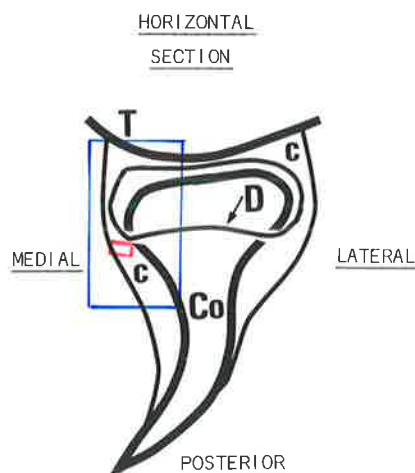


Fig. 31c. x250. Posterior part of Capsule, representing the area enclosed by the red outline in fig. 31a. Oxidised and Non-oxidised, Orcein-Light green stain. Elastic fibres are present in the non-oxidised control section. In the adjacent oxidised section some oxytalan fibres are also seen. O = oxytalan fibres; E = elastic fibres.



T = Temporal bone      Co = Condyle  
D = Disc outline      C = Capsule

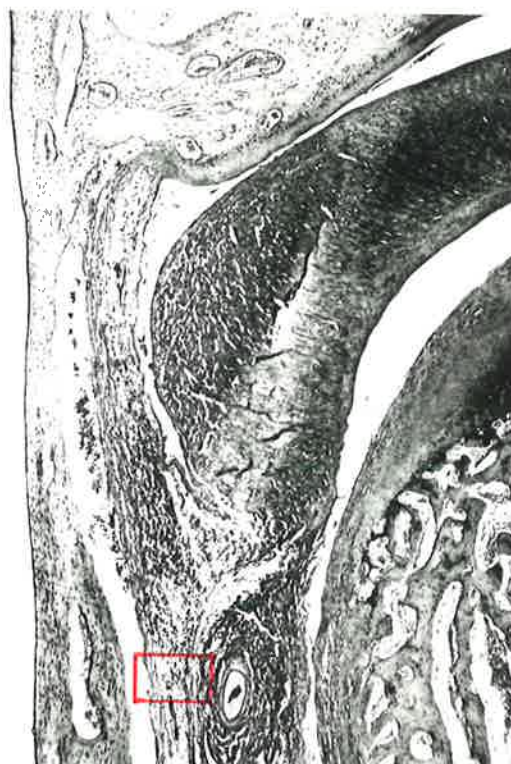

Fig. 32a. Rabbit Temporomandibular joint.

The diagram shows the articulation in horizontal section. The photomicrograph (x25) illustrates the anatomy of the posterior portion of the articulation and represents the area outlined in the diagram.

The part of the capsule indicated in red is shown overleaf at higher magnification.

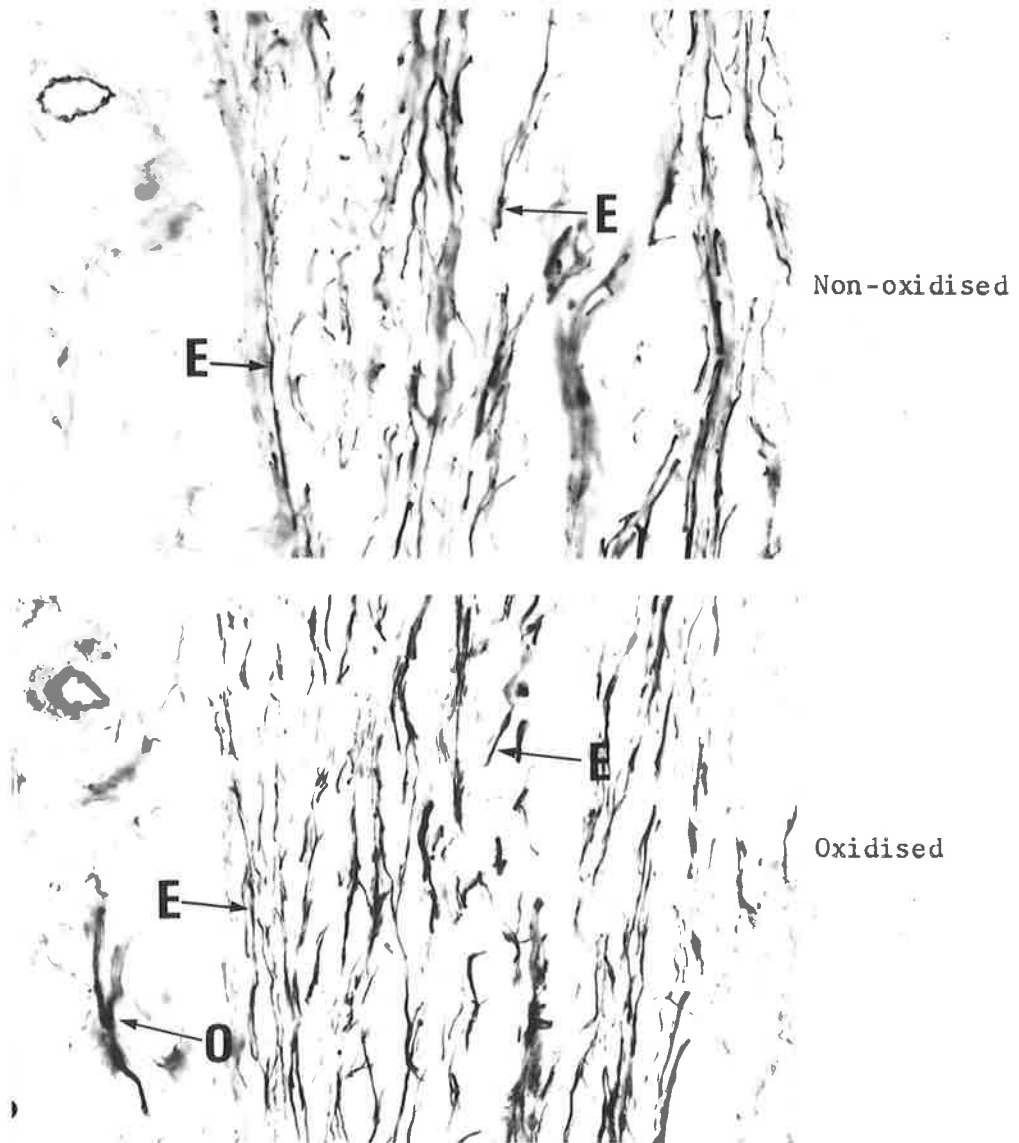


Fig. 32b. x250. Posterior part of Capsule, representing the area enclosed by the red outline in fig. 32a.

Oxidised and Non-oxidised, Orcein-Light green stain.

Elastic fibres are present in the non-oxidised control section. The additional fibres seen in the adjacent oxidised section are oxytalan. Both fibre types run antero-posteriorly.

O = oxytalan fibres; E = elastic fibres.

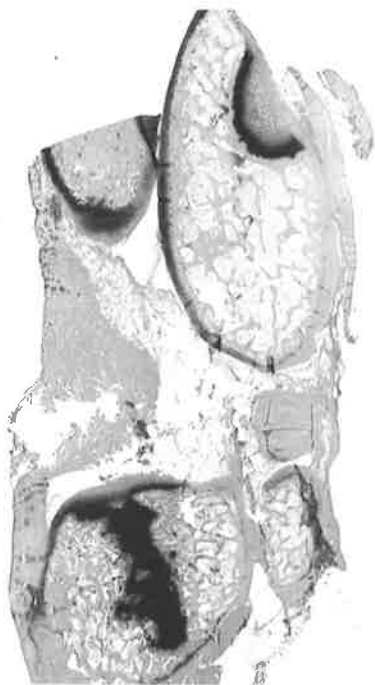

---

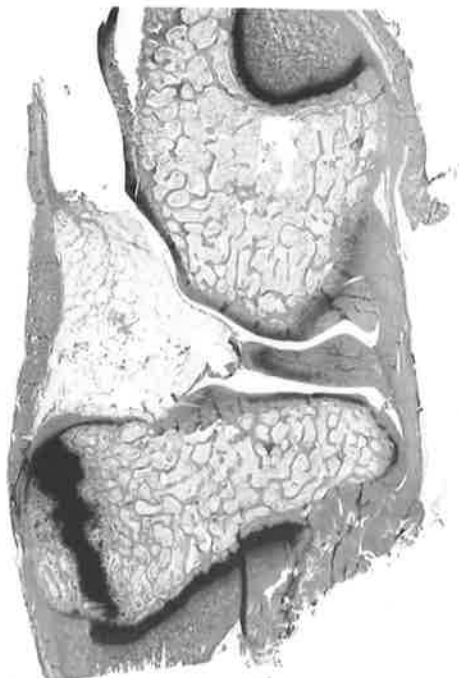
Low power photomicrographs of the rabbit knee joint [x5] are shown of progressive antero-posterior (fig. 33) and medio-lateral (fig. 34) longitudinal sections to provide an impression of the anatomy and histology of the articulation.

The findings of the staining methods used in this study will be discussed in relation to the following structures :

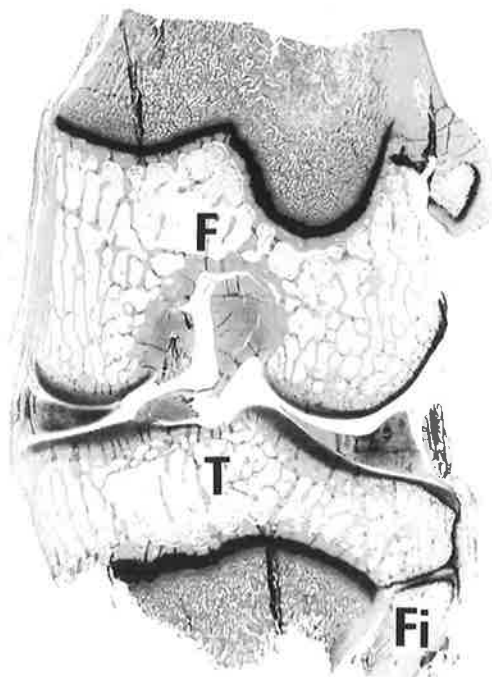
- (i) bony articular surfaces
- (ii) articular discs
- (iii) joint capsule
- (iv) intra-articular ligaments
- (v) extra-articular ligaments
- (vi) tendons
- (vii) periosteum
- (viii) patella ligament



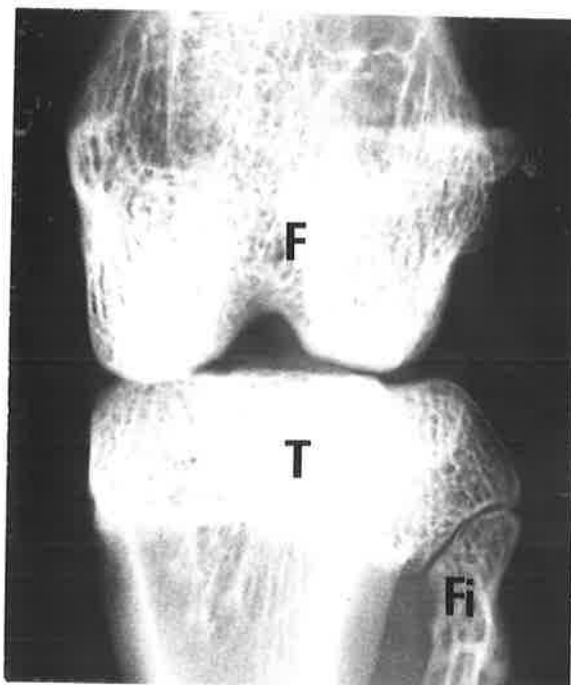
(1)



(2)

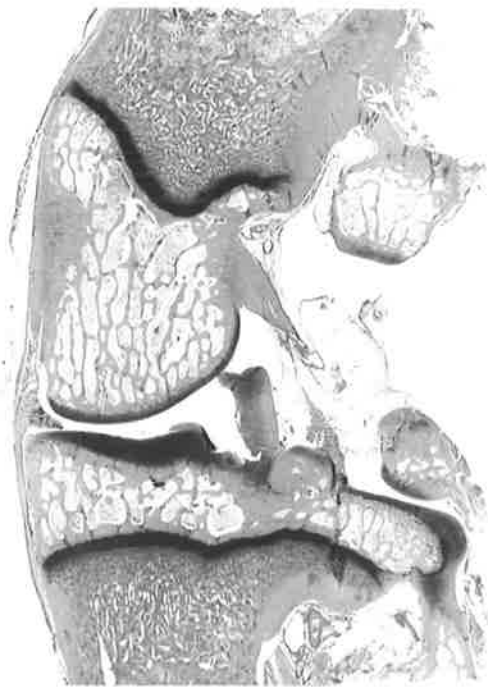


(3)

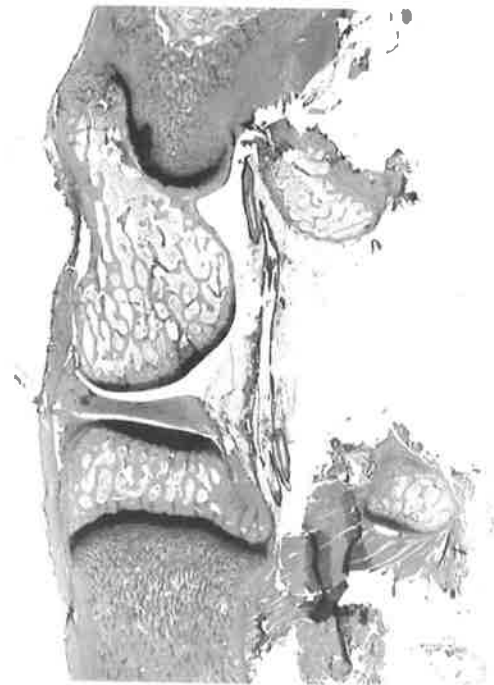
**Fig. 33a.**

Rabbit Knee joint. Progressive antero-posterior longitudinal sections (x5). The radiograph represents No. (3), where :

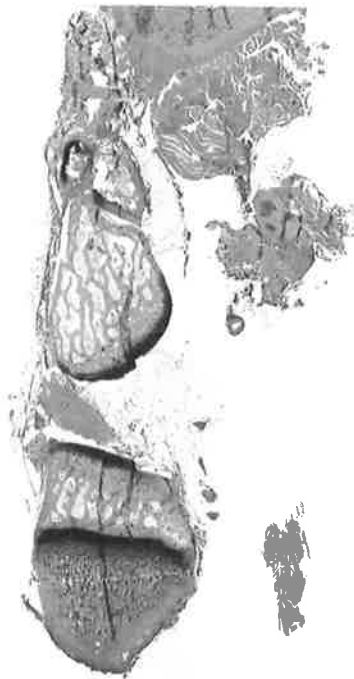F = femur; T = tibia; Fi = fibula.



(4)



(5)



(6)

Fig. 33b. Rabbit Knee joint. Progressive antero-posterior longitudinal sections (x5).

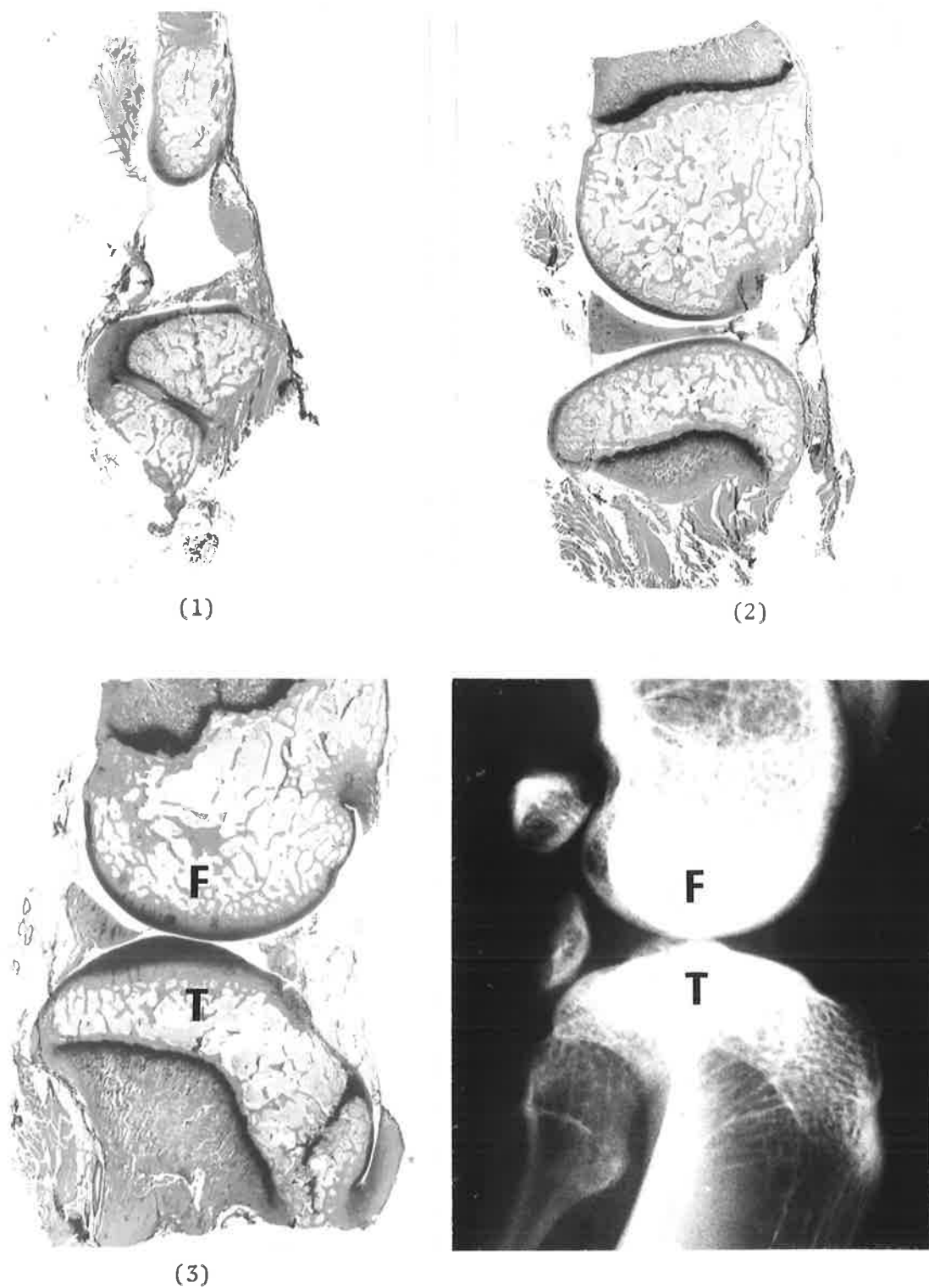
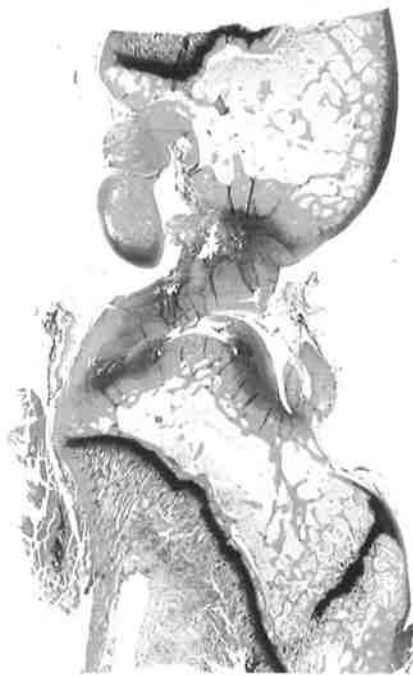
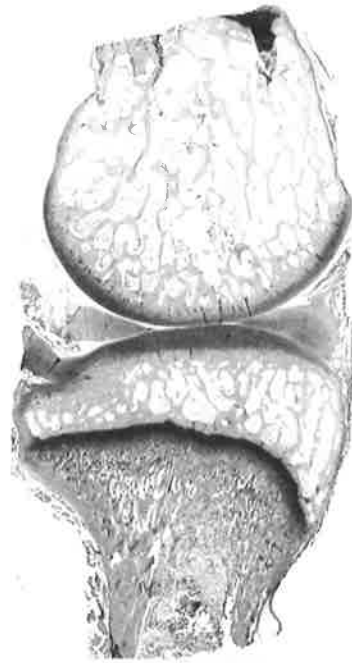
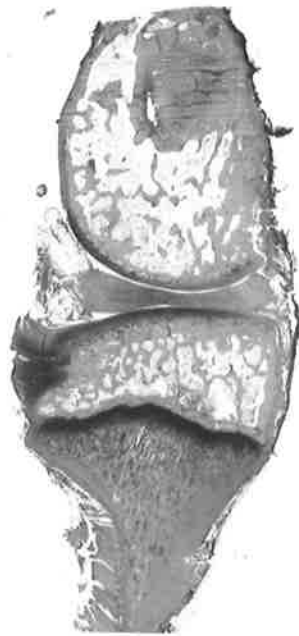Fig. 34a. Rabbit Knee joint. Progressive medio-lateral longitudinal sections (x5). The radiograph represents No. (3), where :  
 F = femur; T = tibia.



(4)



(5)



(6)

Fig. 34b. Rabbit Knee joint. Progressive medio-lateral longitudinal sections (x5).

(i) BONY ARTICULAR SURFACES OF THE KNEE JOINT

A layer of hyaline cartilage covers the ends of the long bones forming the articulation. A perichondrial layer is absent. Only a few chondrocyte cells are present in the superficial part of the articular cartilage and as the distance from the periphery increases the cells mature and divide, forming typical cell nests that are orientated perpendicular to the surface (fig. 35).

Both the aldehyde fuchsin and orcein-stained sections of the articular cartilage generally demonstrate chondrocyte cells scattered throughout a homogeneous matrix (fig. 36).

However, in some of the oxidised material, a few fine fibres are occasionally seen passing at random in the cartilaginous matrix. The fibres are mainly located in the superficial part of the cartilage and occur less frequently in the deeper layers. They are also seen more clearly in sections stained by orcein, since the matrix mucopolysaccharide does not react to the same degree with this stain as it does with aldehyde fuchsin. These oxytalan-staining elements are not found in all the oxidised tissue sections, and their presence does not appear to be related to any particular structures overlying the region of articular cartilage where they occur (fig. 37).

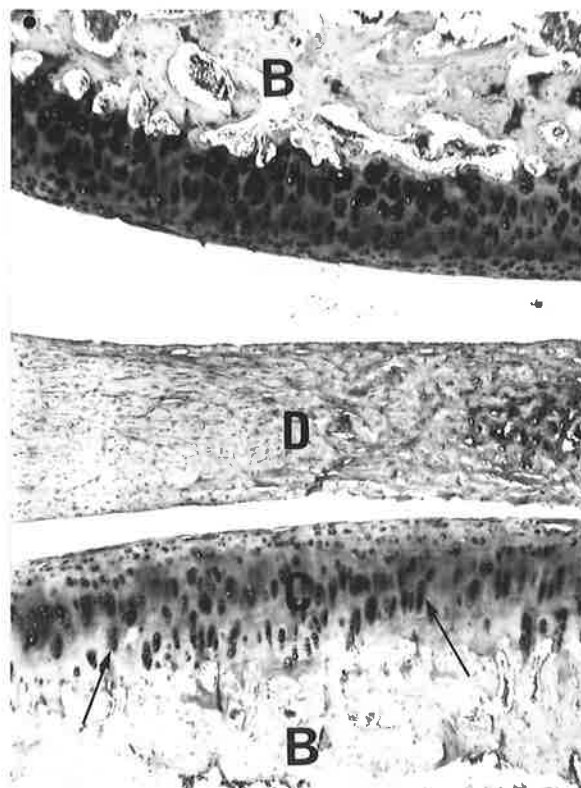


Fig. 35. x25. Articular surfaces of Rabbit Knee joint. Chondrocyte cells (arrows) are orientated perpendicular to the surface in the deeper layers of articular cartilage. B = bone; D = articular disc; C = hyaline cartilage.

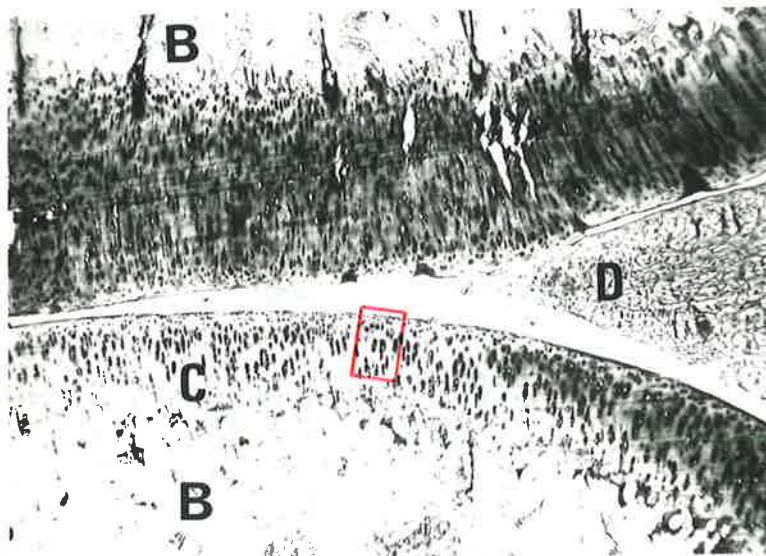


Fig. 36a. x25. Articular surfaces of Rabbit Knee joint. The portion of articular cartilage outlined in red is shown on the following two pages at higher magnification.  
B = bone; D = articular disc; C = hyaline cartilage.

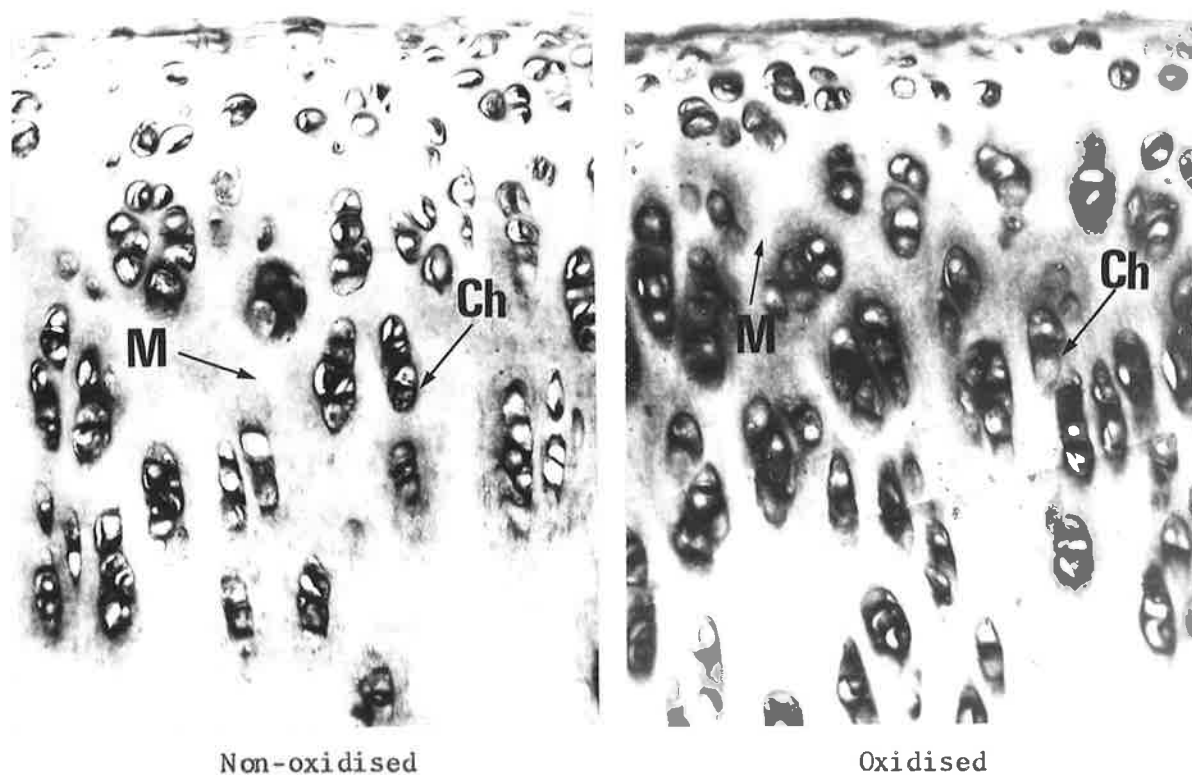


Fig. 36b. x250. Articular cartilage of Rabbit Knee joint, representing the area enclosed by the red outline in fig. 36a. Oxidised and Non-oxidised, Aldehyde fuchsin-Halmi stain. Elastic and oxytalan fibres are absent from both the non-oxidised control section and the adjacent oxidised section. Cartilage cells (Ch) are scattered throughout a homogeneous matrix (M).

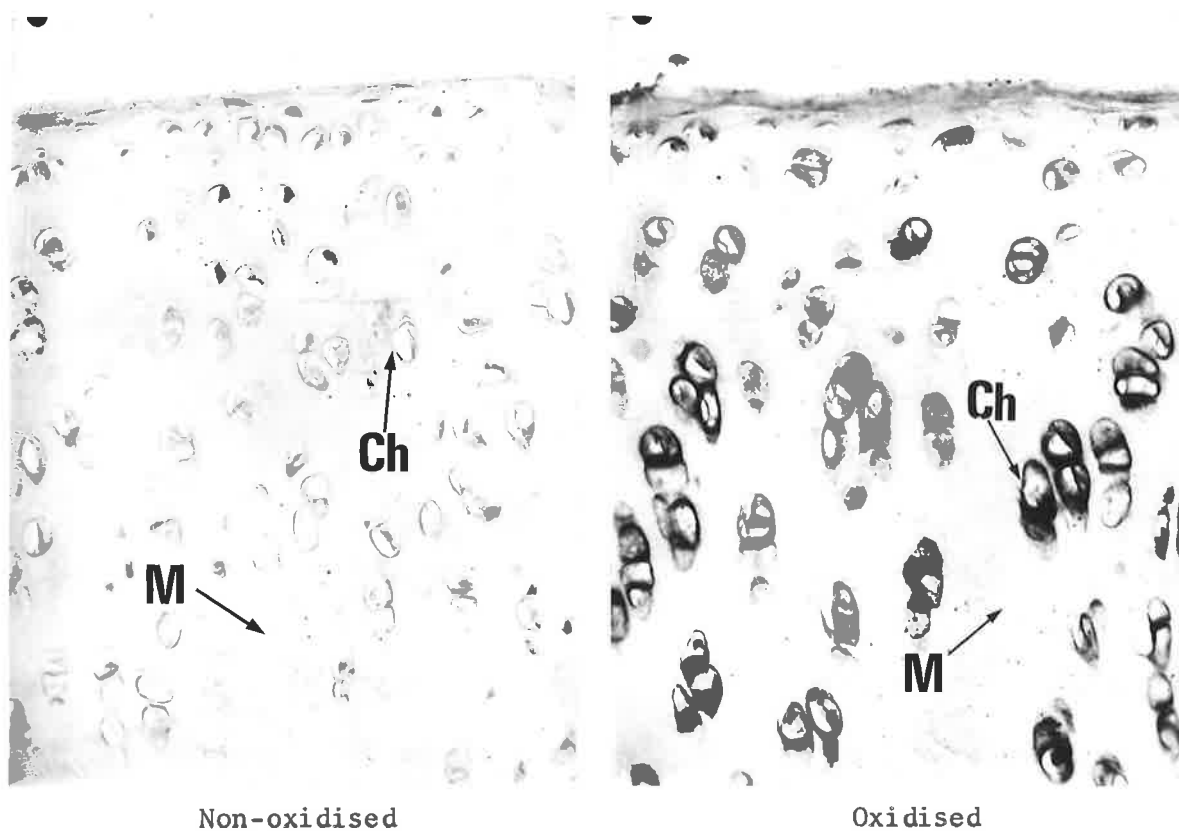


Fig. 36c. x250. Articular cartilage of Rabbit Knee joint, representing the area enclosed by the red outline in fig. 36a.

Oxidised and Non-oxidised, Orcein-Light green stain. Elastic and oxytalan fibres are not present in the matrix of the hyaline cartilage.

Ch = chondrocytes; M = matrix material.

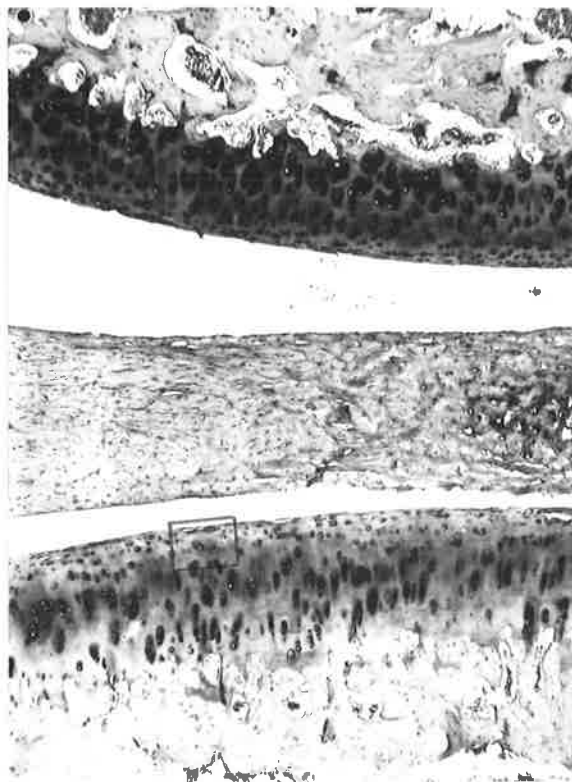


Fig. 37a. x25. Articular surfaces of Rabbit Knee joint. The portion of the articular cartilage outlined in red is shown at higher magnification in fig. 37b.

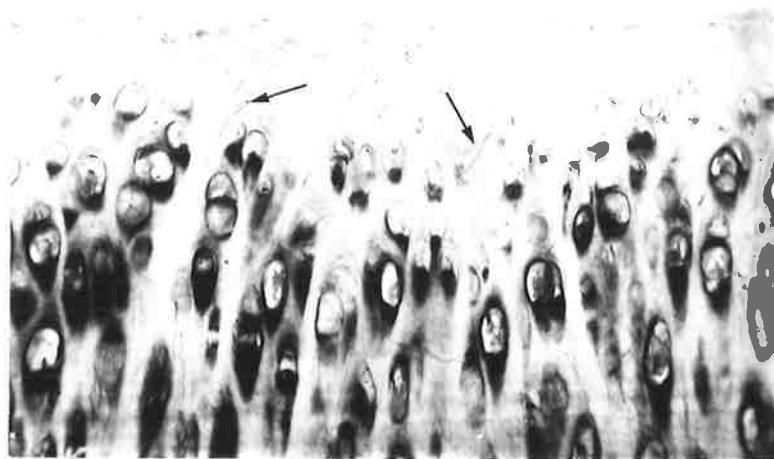


Fig. 37b. x250. Articular cartilage of Rabbit Knee joint, representing the area enclosed by the red outline in fig. 37a. Oxidised, Orcein-Light green stain. Fine oxytalan-staining fibres (arrows) are present throughout the cartilaginous matrix. Their orientation is random.

(ii) ARTICULAR DISCS OF THE KNEE JOINT

The two discs of the rabbit knee joint are interposed between the femur and the tibia and their shape approximates the contour of the opposing condylar surfaces. They consist of avascular fibrocartilaginous tissue with the chondrocytes arranged either singly or in typical cell 'nests' that run parallel with the collagen bundles (fig. 38).

Elastic and oxytalan fibres are both present in the disc, and the relative amounts of each fibre type varies in different regions of the disc. However, no consistent pattern of elastic and oxytalan fibre distribution is found in relation to either the morphology of the disc or the structures attaching to it. In some central parts of the disc, and also near its attachment with the capsule or a ligament, only oxytalan fibres are present. These fibres run parallel with the collagen bundles (figs. 39,40).

Elastic and oxytalan fibres occur together in other areas of the disc (fig. 41).

Both fibre types are also found where the disc is very thin. The elastic and oxytalan fibres pass parallel to the surface of the disc together with the collagen bundles (fig. 42).

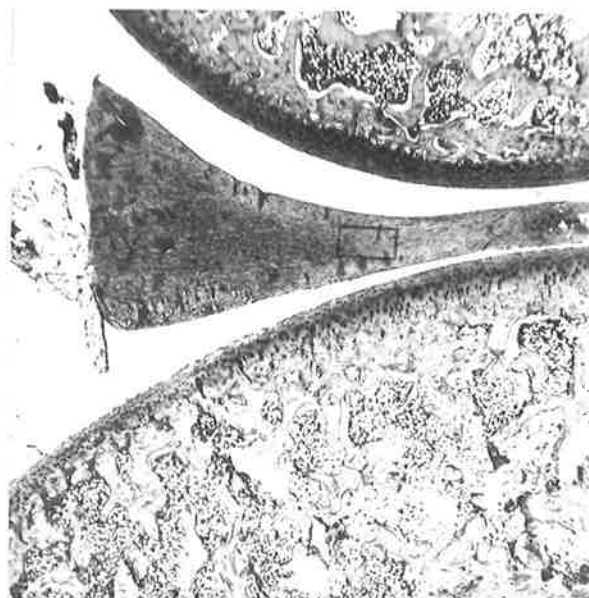


Fig. 38a. x10. Articular surfaces of Rabbit Knee joint. The portion of the articular disc outlined in red is shown at higher magnification in fig. 38b.




Fig. 38b. x250. Articular disc of Rabbit Knee joint, representing the area enclosed by the red outline in fig. 38a. Oxidised, Orcein-Light green stain. Chondrocyte cells (Ch) run parallel with the collagen bundles (Co).



Fig. 39. x400. Articular disc of Rabbit Knee joint.  
Oxidised and Non-oxidised, Aldehyde fuchsin-Halmi stain.  
Elastic and oxytalan fibres are absent in the non-oxidised control section. In the adjacent oxidised section, oxytalan fibres (arrows) are present.

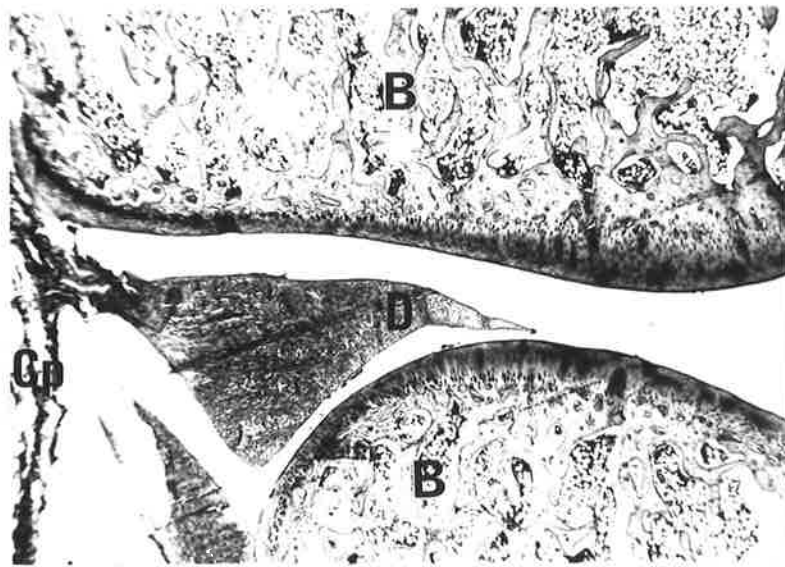


Fig. 40a. x10. Articular surfaces of Rabbit Knee joint, medio-lateral longitudinal section. The area where the articular disc attaches to the capsule has been outlined in red, and is shown overleaf at higher magnification.  
B = bone; D = articular disc; Cp = capsule.

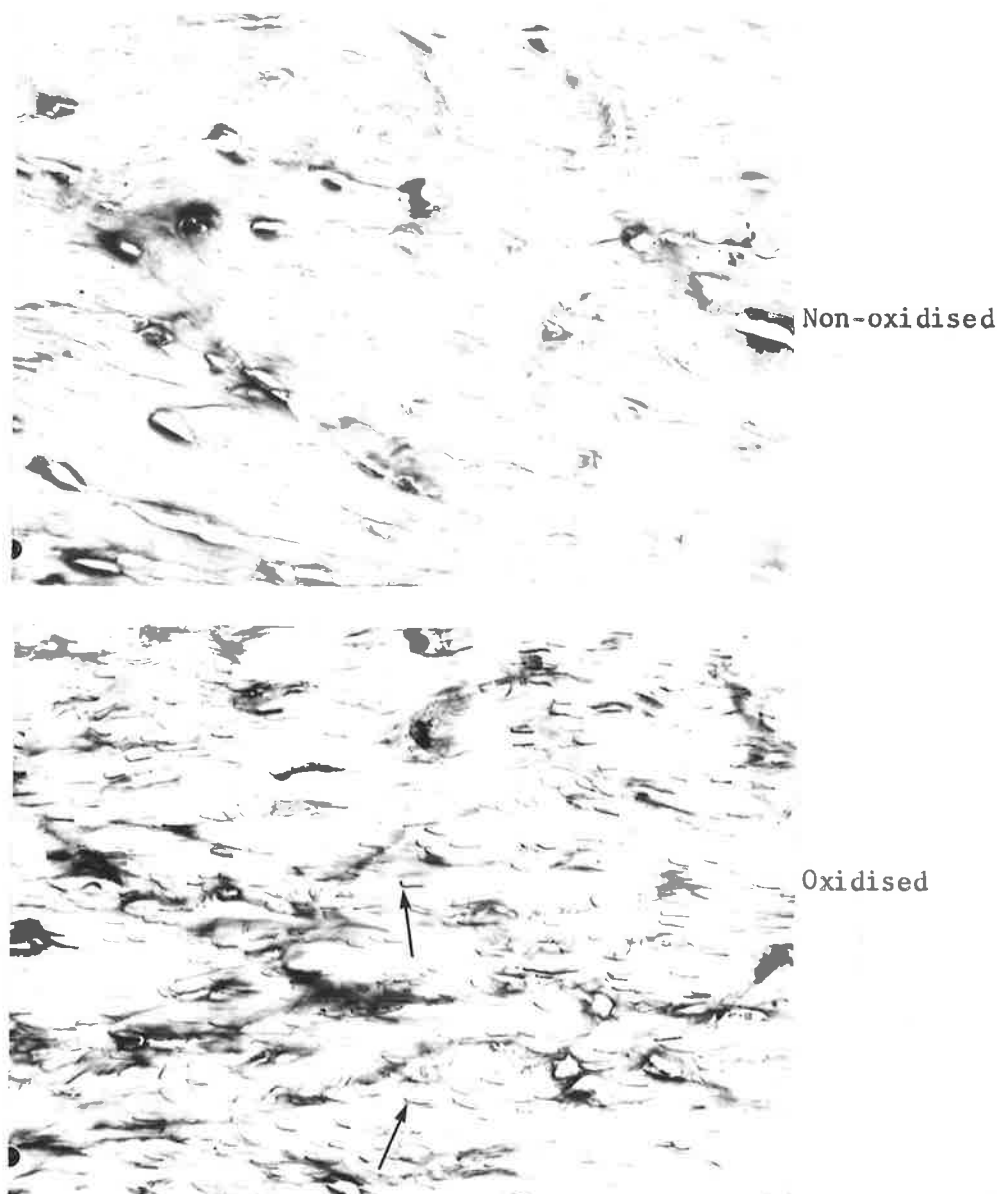


Fig. 40b. x250. Articular disc of Rabbit Knee joint, representing the area enclosed by the red outline in fig. 40a. Oxidised and Non-oxidised, Aldehyde fuchsin-Halmi stain. Elastic and oxytalan fibres are absent in the non-oxidised control section. In the adjacent oxidised section, oxytalan fibres (arrows) are numerous.

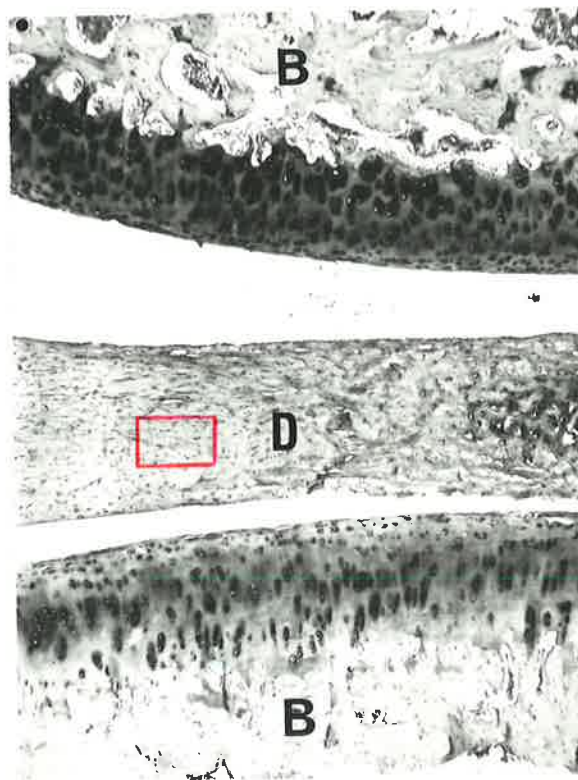


Fig. 41a. x25. Articular surfaces of Rabbit Knee joint.  
The portion of the articular disc outline in red  
is shown overleaf at higher magnification.  
B = bone; D = articular disc.

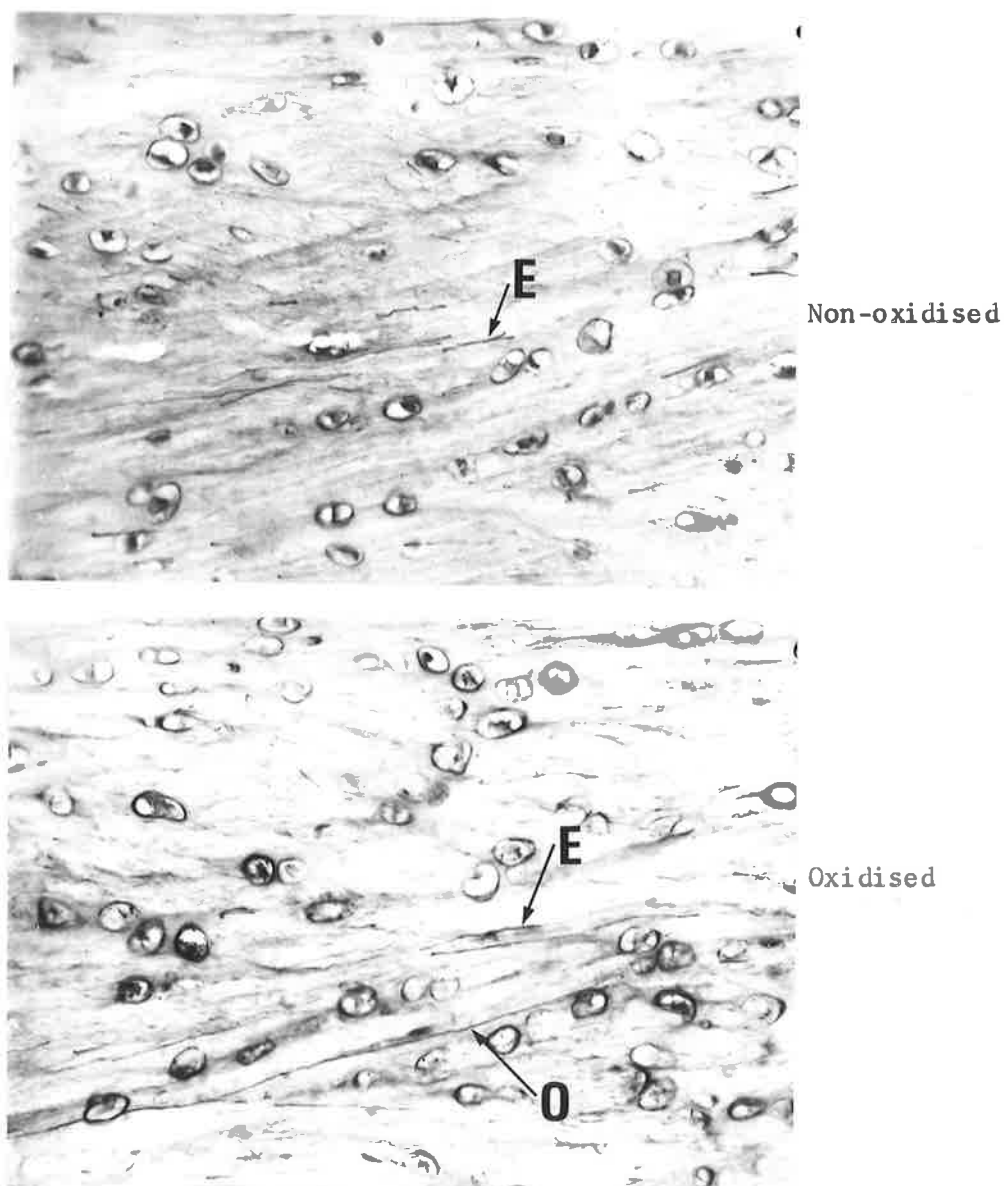


Fig. 41b. x250. Articular disc of Rabbit Knee joint, representing the area enclosed by the red outline in fig. 41a. Oxidised and Non-oxidised, Orcein-Light green stain. Elastic fibres are present in the non-oxidised control section. The additional fibres present in the adjacent oxidised section are oxytalan.  
E = elastic; O = oxytalan fibres.

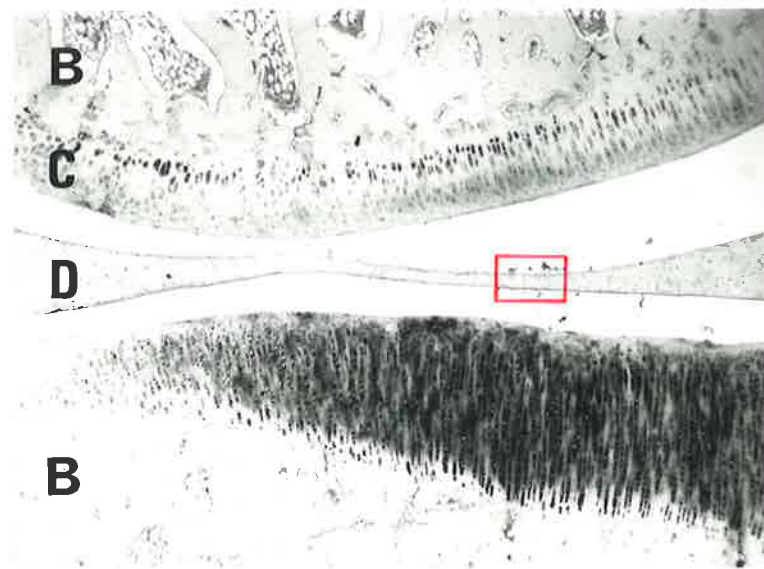

Fig. 42a. x25. Articular surfaces of Rabbit Knee joint.  
The central portion of the articular disc outlined  
in red is shown overleaf at higher magnification.  
C = hyaline cartilage; D = articular disc; B = bone.




Fig. 42b. x250. Articular disc of Rabbit Knee joint, representing the area outlined in fig. 42a. Oxidised and Non-oxidised, Orcein-Light green stain. In the non-oxidised control section elastic fibres are present. Oxytalan fibres, together with elastic fibres occur in the adjacent oxidised section. Both fibre types run parallel with the surface of the disc. E = elastic; O = oxytalan fibres.

(iii) THE CAPSULE OF THE KNEE JOINT

The capsule forms a somewhat barrel-shaped structure enclosing the articular components of the joint. It does not entirely surround the articular cavity, but is augmented in various locations by tendons of muscles and extra-articular ligaments. The capsule attaches to the periosteum of the opposing bones at an area adjacent to the hyaline articular cartilage. Various intra-articular structures, including discs and ligaments, are related to the capsule; while tendons, ligaments and some muscle fibres are attached to its external surface.

The capsule is composed of loose, vascular fibrous tissue. Collagen forms the principal fibre type, but many elastic and oxytalan fibres are also present.

Numerous elastic fibres and few (if any) oxytalan fibres are found in the capsule where it attaches to the disc (fig. 43).

Both elastic and oxytalan fibres are present in the capsular tissue between its attachment to the disc and periosteum. The fibres run in the same direction as the collagen bundles (fig. 44).

The attachment of the capsule to the periosteum is characterised by a large number of oxytalan staining elements and only a few elastic staining fibres (fig. 45).

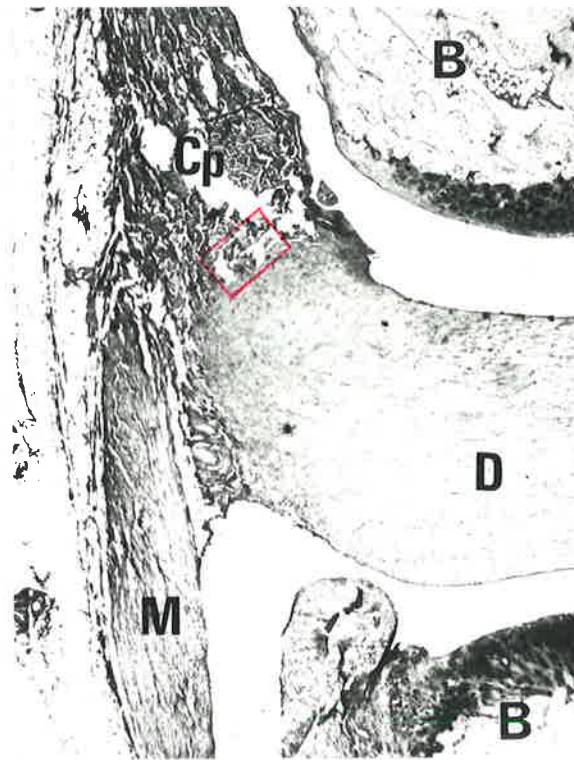


Fig. 43a. x25. Articular components of the Rabbit Knee joint. Antero-posterior longitudinal section. The part of the capsule that attaches to the articular disc has been outlined in red and is shown overleaf at higher magnification.  
 B = bone; D = disc; Cp = capsule; M = muscle.




Fig. 43b. x100. Capsule and Articular disc of Rabbit Knee joint, representing the area outlined in fig. 43a. Oxidised and Non-oxidised, Orcein-Light green stain. Elastic fibres (arrows) are present in the non-oxidised control section. Approximately the same number of fibres are present in the adjacent oxidised section. The fibres stained in this region are therefore elastic.

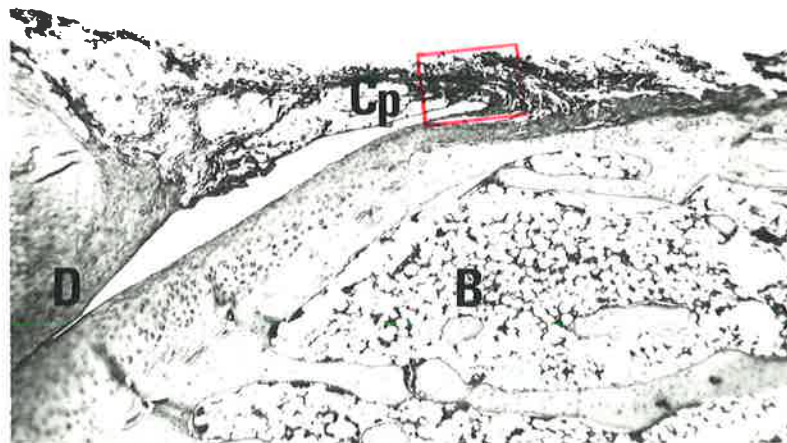


Fig. 44a. x25. Articular components of the Rabbit Knee joint. medio-lateral longitudinal section. The part of the capsule outlined in red is shown overlaid at higher magnification.  
B = bone; D = articular disc; Cp = capsule.

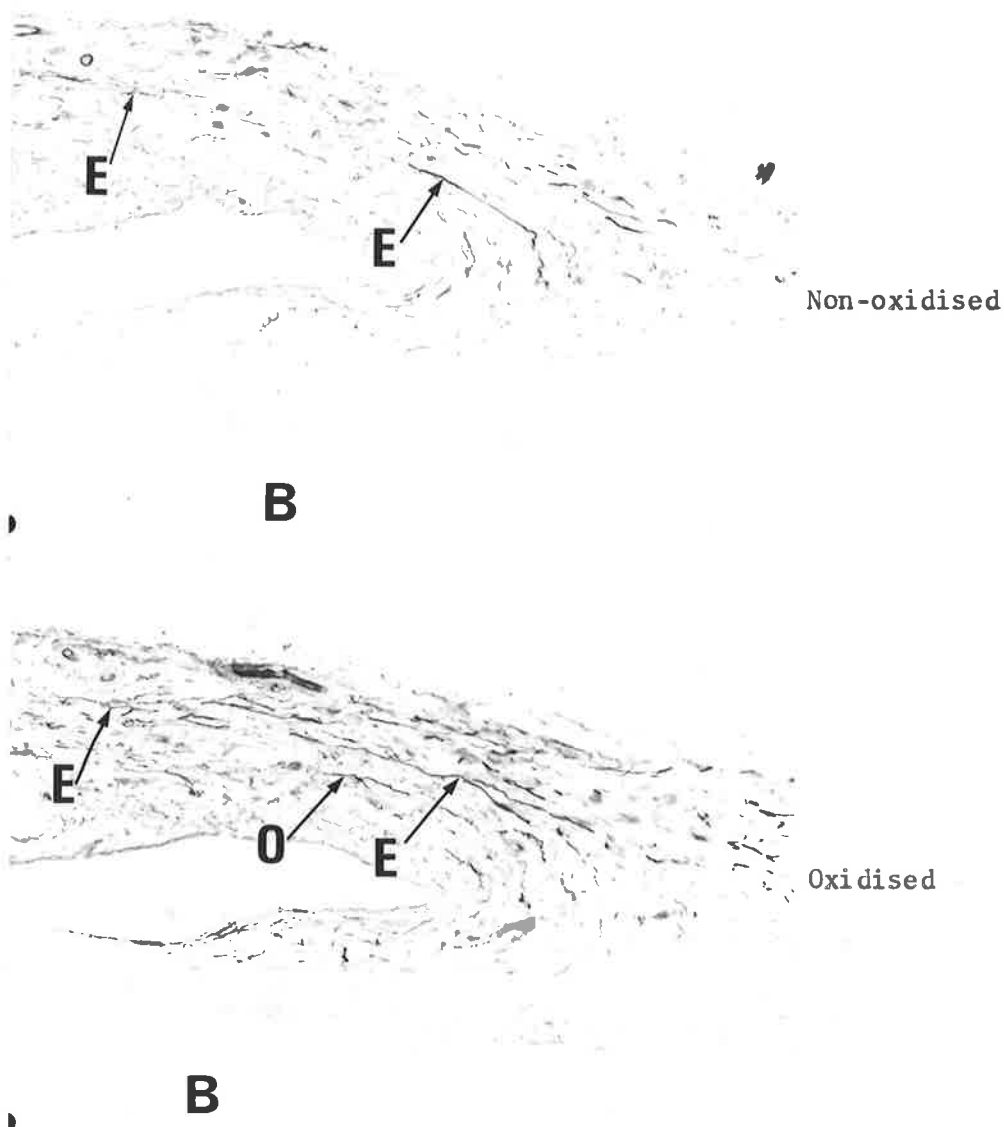


Fig. 44b. x100. Capsule of Rabbit Knee joint, representing the area outlined in fig. 44a. Oxidised and Non-oxidised, Orcein-Light green stain. Elastic fibres are present in the non-oxidised control section. The additional fibres stained in the adjacent oxidised section are oxytalan. Both fibre types run parallel with the length of the capsule. B = bone; E = elastic; O = oxytalan fibres.

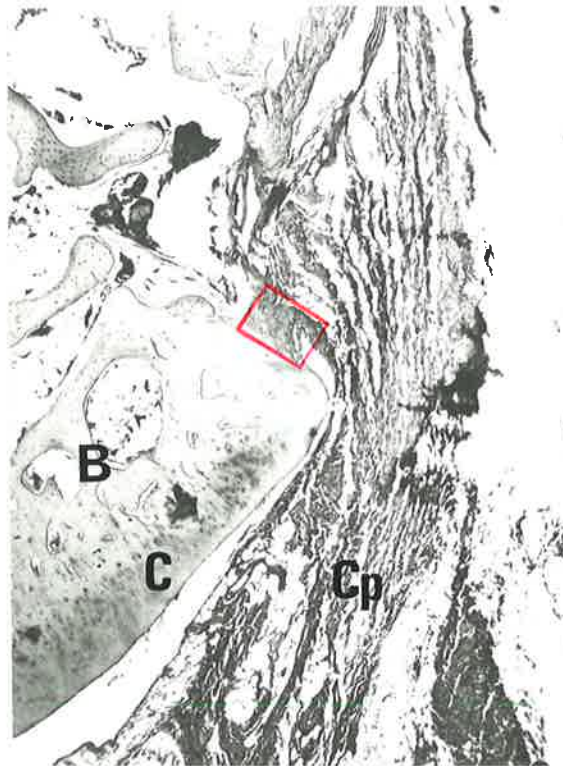

Fig. 45a. x25. Articular components of Rabbit Knee joint.  
Medio-lateral longitudinal section.  
The portion of the capsule attaching to periosteum  
is outlined in red and is shown at higher magnification  
on the following two pages.  
C = hyaline cartilage; B = bone; Cp = capsule.

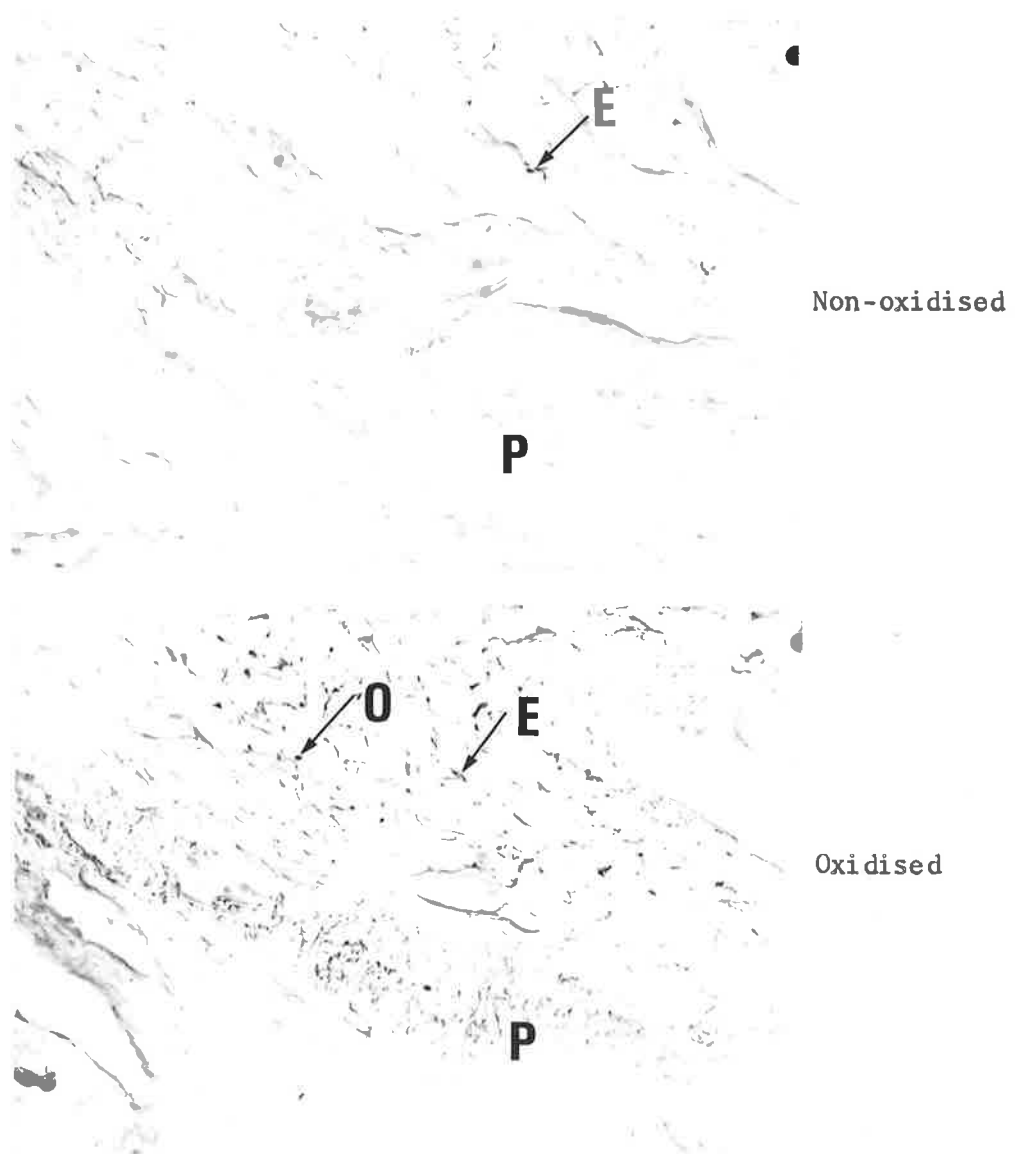


Fig. 45b. x250. Attachment of Capsule, Rabbit Knee joint; representing the area outlined in fig. 45a. Oxidised and Non-oxidised, Orcein-Light green stain. A small number of elastic fibres are present in the non-oxidised control section. Many oxytalan fibres are present in the adjacent oxidised section. E = elastic; O = oxytalan; P = periosteum.

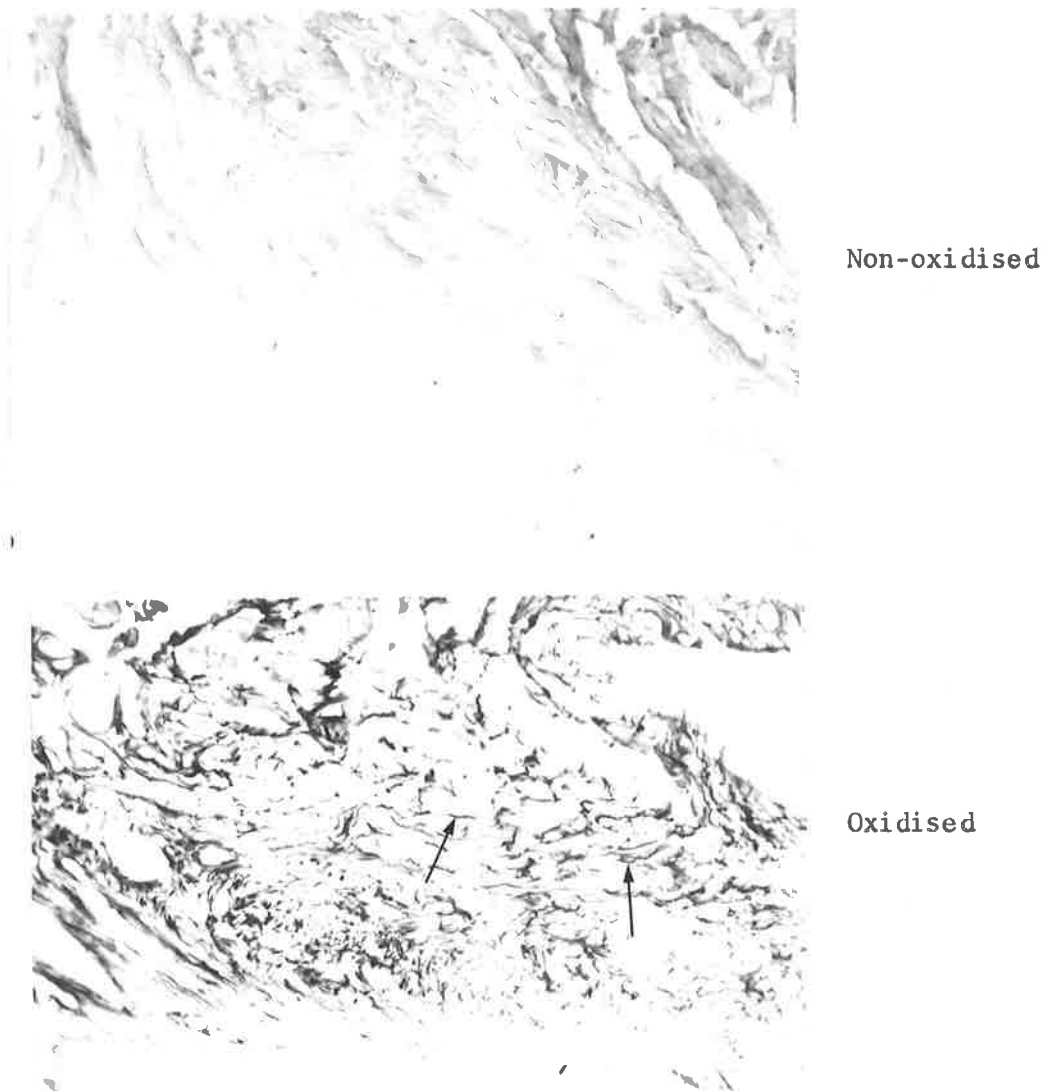


Fig. 45c. x250. Attachment of Capsule, Rabbit Knee joint; representing the area outlined in fig. 45a. Oxidised and Non-oxidised, Aldehyde fuchsin-Halmi stain. Elastic fibres are absent from the non-oxidised control section. The large mass of fibres (arrows) in the adjacent oxidised section are oxytalan-staining elements.

(iv) INTRA-ARTICULAR LIGAMENTS OF THE KNEE JOINT

The cruciate ligaments of the rabbit knee joint lie within the capsule, and extend between non-articular surfaces of the femur and tibia in relation to the longitudinal axis of the limb. They are strong rounded bands that are subjected to considerable tension during the various joint movements.

The ligaments consist chiefly of collagen fibres, but oxytalan and some elastic fibres are also present.

A ligament that was torn near its periosteal attachment during preparation of the slide demonstrates that many oxytalan fibres and only a few elastic fibres occur at the cut end. The oxytalan fibres run parallel with the collagen bundles (fig. 46).

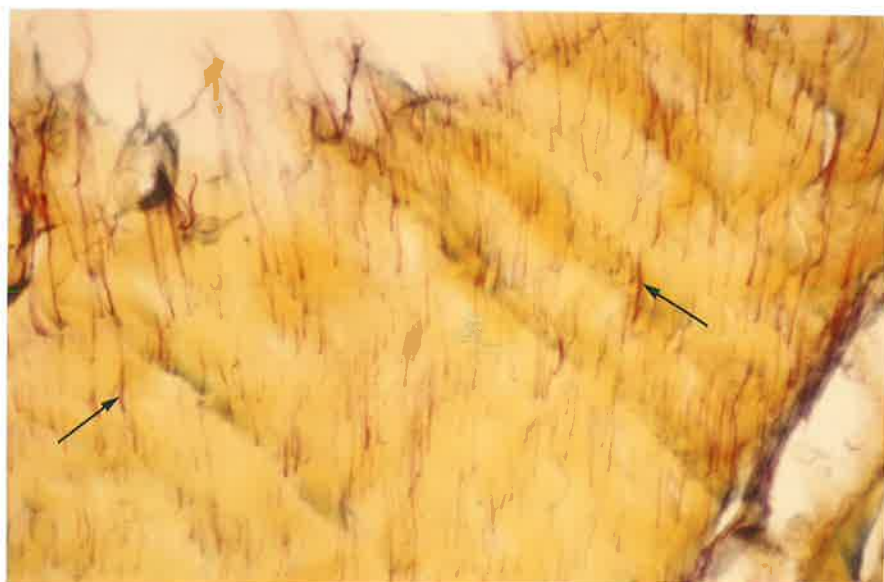
At the termination of an intra-articular ligament numerous oxytalan fibres are present. Some elastic fibres are also found where the ligament inserts into the non-articular part of the opposing bony surfaces. The orientation of the oxytalan fibres in this region appears to be random (fig. 47).

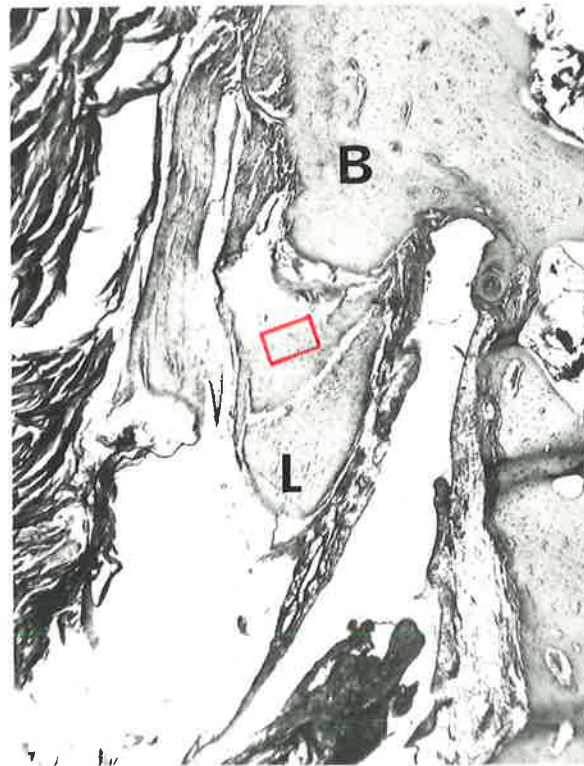
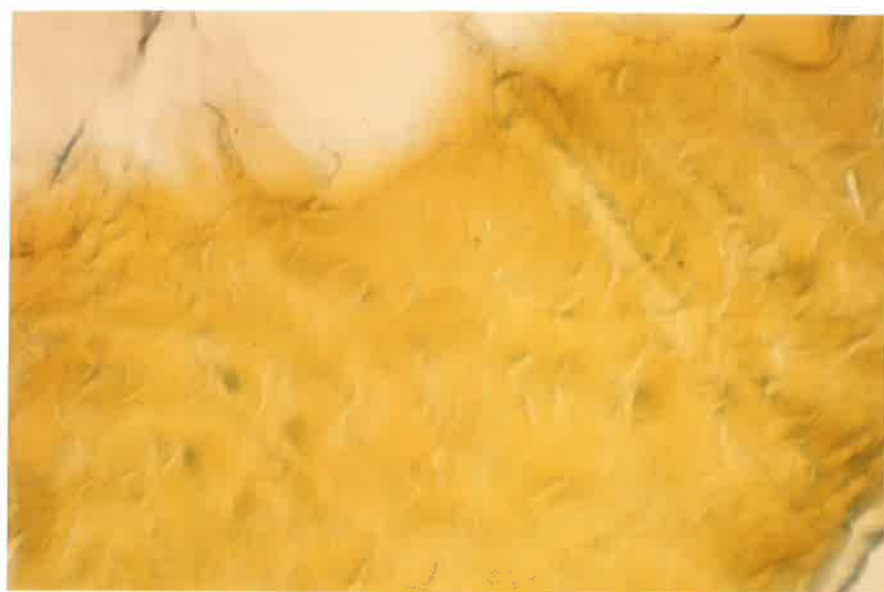
Fig. 46a. x25. Articular components of Rabbit Knee joint.  
Medio-lateral longitudinal section.  
The portion of the intra-articular ligament outlined  
in red is shown at higher magnification on the next  
two pages.  
B = bone; L = ligament.



Non-oxidised

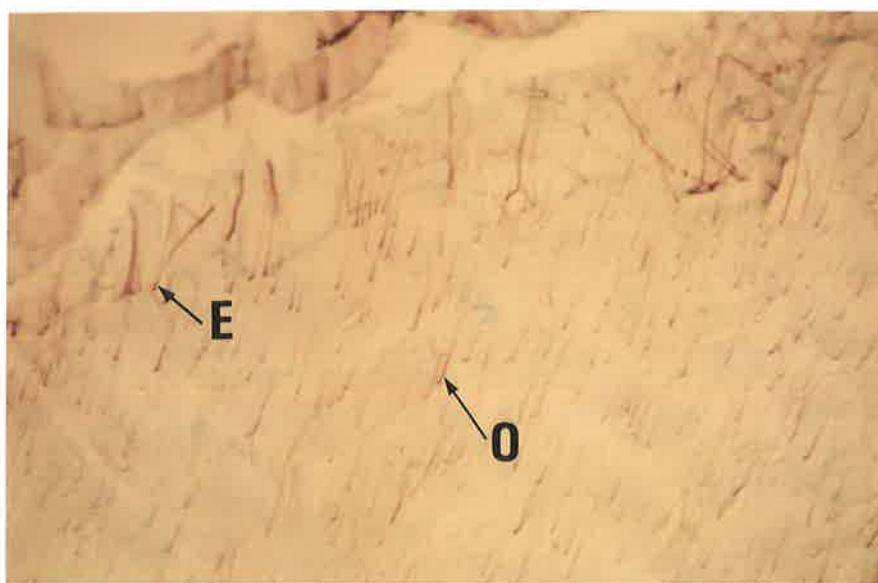


Oxidised

Fig. 46b. x250. Intra-articular Ligament of Rabbit Knee joint, representing the area outlined in fig. 46a. Oxidised and Non-oxidised, Aldehyde fuchsin-Halmi stain. Oxytalan fibres are not present in the non-oxidised control section. The adjacent oxidised section demonstrates many oxytalan fibres (arrows) running parallel with the collagen bundles (stained yellow).



Non-oxidised



Oxidised

Fig. 46c. x250. Intra-articular Ligament of Rabbit Knee joint, representing the area outlined in fig. 46a.

Oxidised and Non-oxidised, Orcein-Light green stain. Some elastic fibres are present in the non-oxidised control section. In the adjacent oxidised section, oxytalan-staining elements are seen together with the elastic fibres.

E = elastic; O = oxytalan fibres.

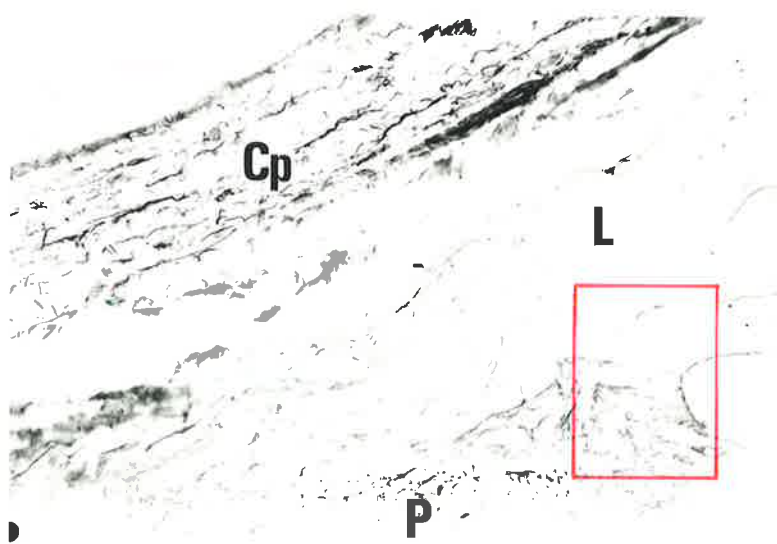


Fig. 47a. x100. Capsule and Intra-articular Ligament of Rabbit Knee joint. Non-oxidised, Orcein-Light green stain.

The portion of the intra-articular ligament outlined in red is shown overleaf at higher magnification.

Cp = capsule; L = ligament; P = periosteum.

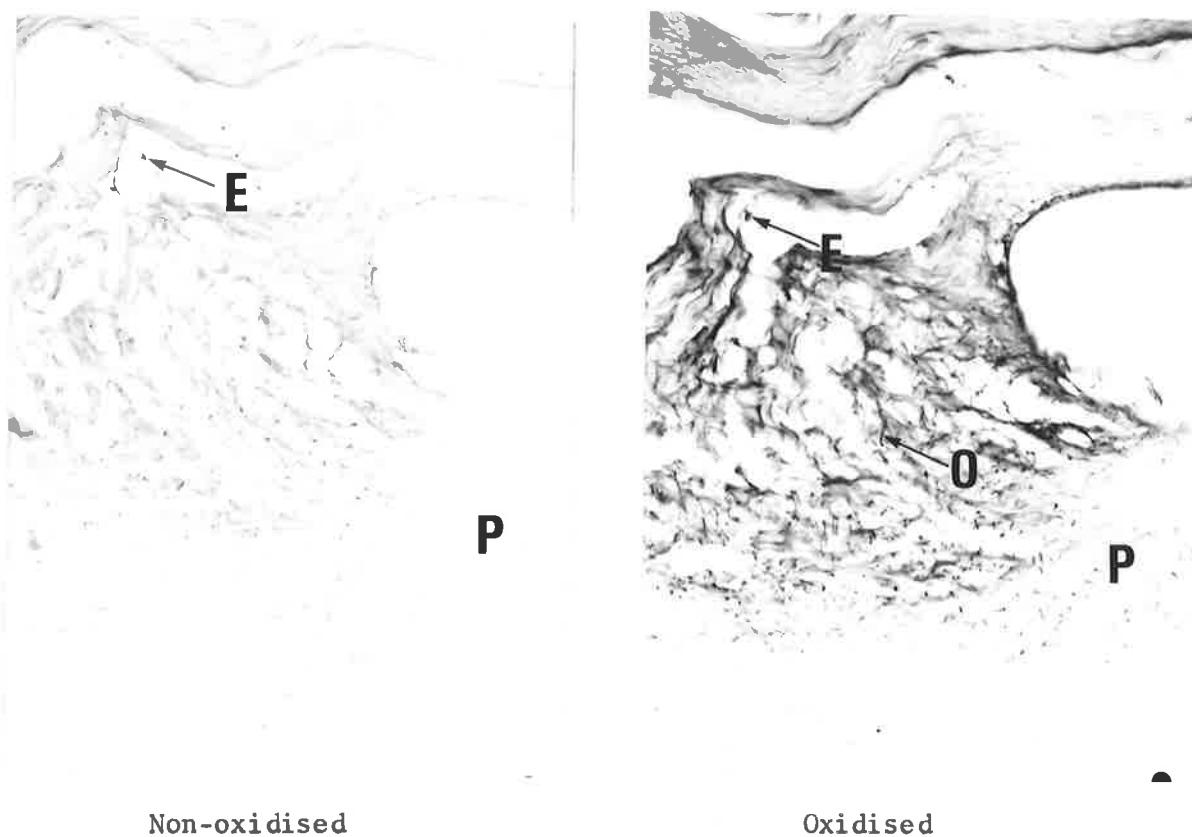


Fig. 47b. x250. Insertion of Intra-articular Ligament of Rabbit Knee joint, representing the area outlined in fig. 47a.

Oxidised and Non-oxidised, Orcein-Light green stain. Some elastic fibres are present in the non-oxidised control section. Many oxytalan fibres are present in the adjacent oxidised section together with the elastic fibres. The oxytalan fibres are orientated at random where they insert into periosteum:  
 E = elastic; O = oxytalan; P = periosteum.

(v) EXTRA-ARTICULAR LIGAMENTS OF THE KNEE JOINT

In addition to the fibrous capsule enclosing the joint, the articulation is further reinforced by ligaments that connect opposing bony surfaces. These extra-articular ligaments vary in their form; some are flat bands, while others are rounded cords. The bulk of a ligament is composed of dense collagen bundles that pursue an oblique or spiral course rather than passing directly between attachments. A large number of oxytalan fibres run parallel with the collagen bundles throughout the length of the ligament, while only a few elastic fibres are present (fig. 48).

There is a transition of the fibrous ligament to a fibro-cartilaginous structure at the region where it inserts into bone. Sections stained by aldehyde fuchsin and orcein demonstrate many oxytalan fibres at the insertion passing parallel with the collagen bundles. Some elastic fibres are present in sections stained by orcein, but are absent when aldehyde fuchsin is used (fig. 49).

A ligament is occasionally seen to unite with a muscle. At the junction of the two different tissues many elastic and oxytalan fibres are present in the ligamentous portion. The fibres are generally orientated at random in this area (fig. 50).




Fig. 48a. x25. Extra-articular Ligament of Rabbit Knee joint. Antero-posterior longitudinal section. The portion of the ligament outlined in red is shown overleaf at higher magnification.  
L = ligament; E = epiphyseal plate of cartilage.

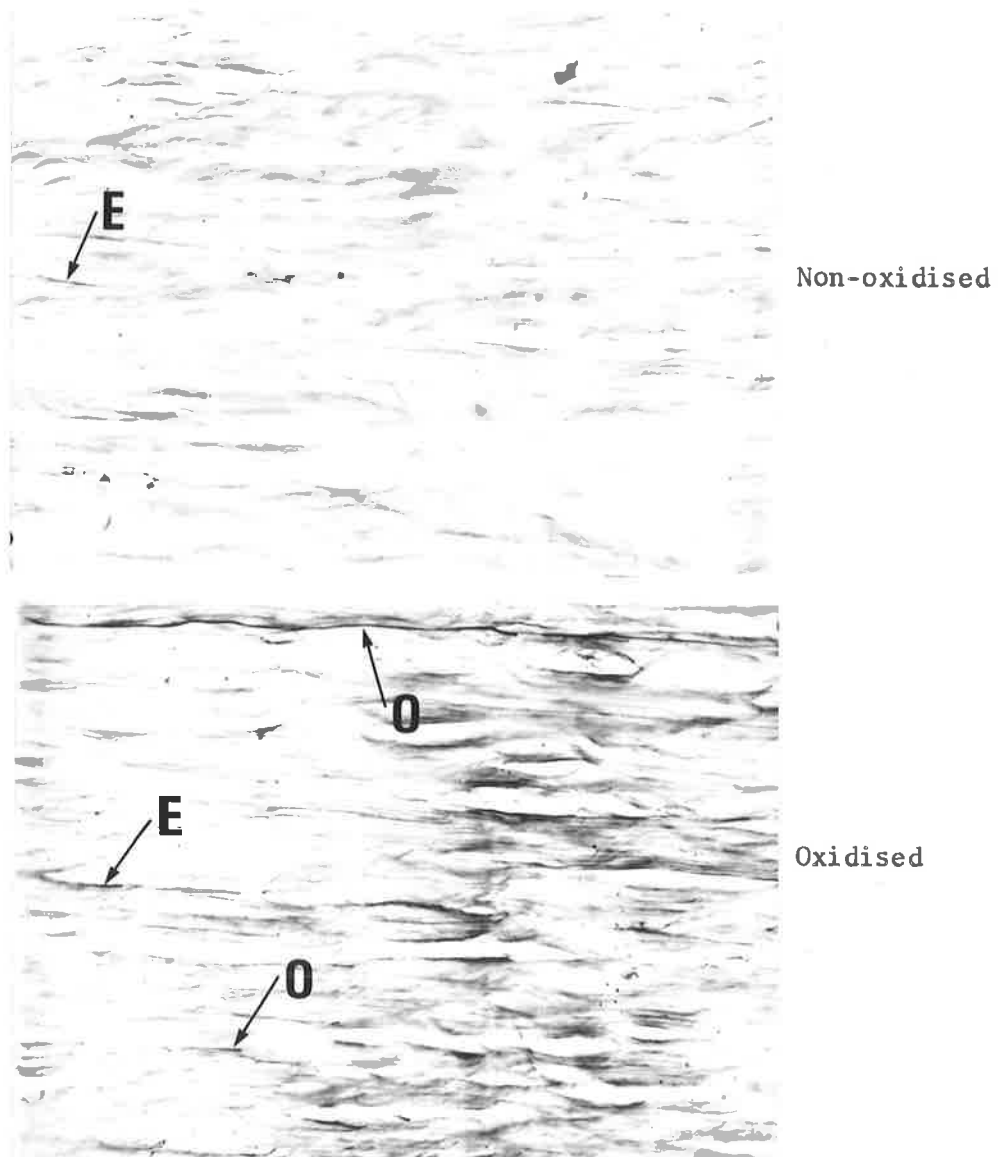


Fig. 48b. x250. Extra-articular Ligament of Rabbit Knee joint, representing the area outlined in fig. 48a. Oxidised and Non-oxidised, Aldehyde fuchsin-Halmi stain. Some elastic fibres are present in the non-oxidised control section. The additional number of fibres present in the adjacent oxidised section are oxytalan. The fibres run parallel with the length of the ligament. E = elastic; O = oxytalan fibres.

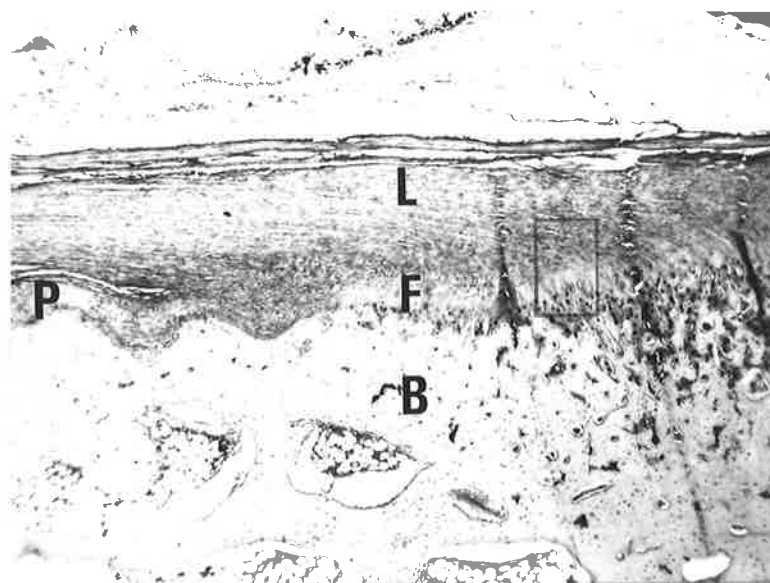


Fig. 49a. x25. Extra-articular Ligament of Rabbit Knee joint. Antero-posterior longitudinal section. The region of ligamentous insertion indicated in red is shown on the next two pages at higher magnification. L = ligament; P = periosteum; F = region of fibrocartilage; B = bone.




Fig. 49b. x250. Insertion of Ligament Rabbit Knee joint, representing the area outlined in fig. 49a. Oxidised and Non-oxidised, Orcein-Light green stain. Some elastic fibres are present in the non-oxidised control section. The additional fibres present in the adjacent oxidised section are oxytalan. E = elastic; O = oxytalan fibres.

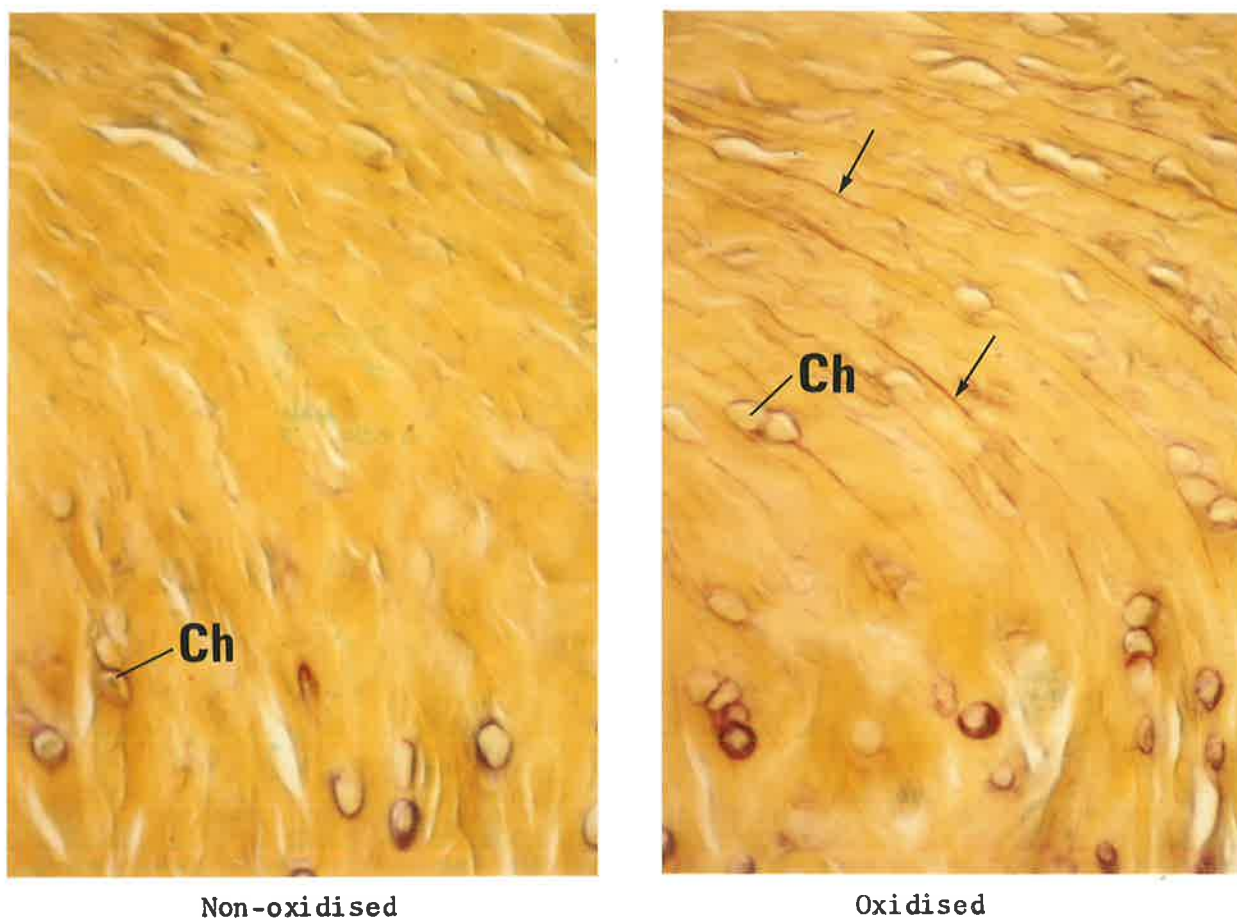


Fig. 49c. x250. Insertion of Ligament Rabbit Knee joint, representing the area outlined in fig. 49a. Oxidised and Non-oxidised, Aldehyde fuchsin-Halmi stain. Oxytalan fibres are absent in the non-oxidised control section, but are present in the adjacent oxidised section. Arrows indicate oxytalan fibres passing into the layer of fibrocartilage. Ch = chondrocyte cells.

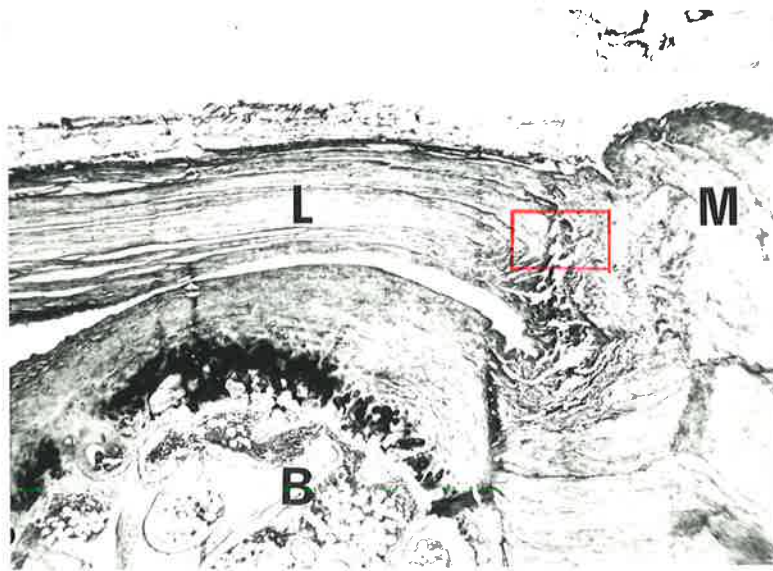


Fig. 50a. x25. Musculo-ligamentous junction, Rabbit Knee joint. Antero-posterior longitudinal section. The part of the ligament outlined in red is shown overleaf at higher magnification.  
L = ligament; M = muscle; B = bone.

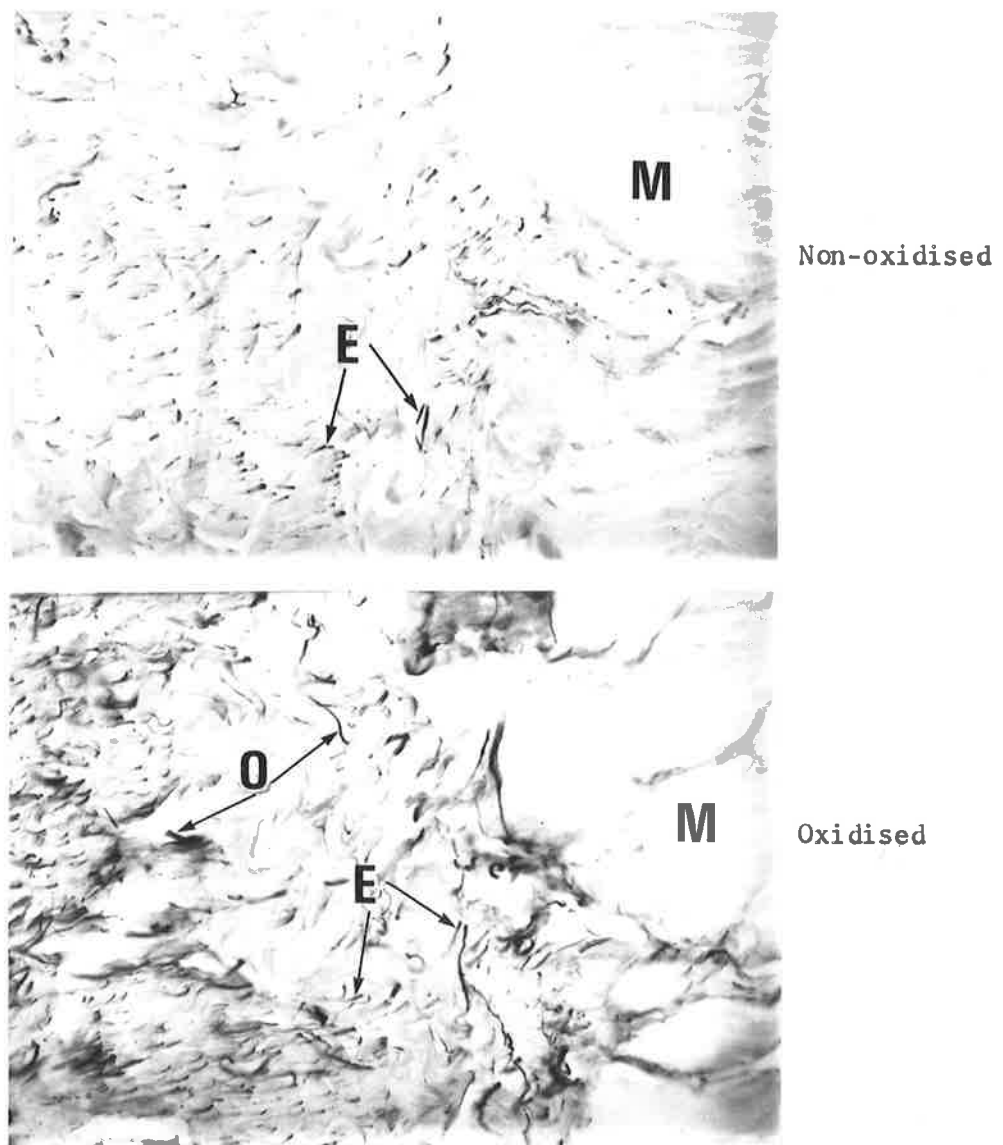


Fig. 50b. x250. Musculo-ligamentous junction Rabbit Knee joint, representing the area outlined in fig. 50a. Oxidised and Non-oxidised, Orcein-Light green stain. Both elastic (E) and oxytalan (O) fibres are present in the ligamentous part of the junction. The orientation of the fibres is irregular. M = muscle.

(vi) TENDONS ADJACENT TO THE KNEE JOINT

Tendons consist mainly of numerous parallel fascicles of collagen fibres that impart flexibility and strength to the tissue. They are relatively inelastic and only slightly extensible.

Oxytalan fibres occur frequently in tendinous tissue running parallel with the collagen bundles, while only occasional elastic fibres are observed (fig. 51).




Fig. 51a. x10. Epiphyseal region Rabbit Knee joint.  
Medio-lateral longitudinal section.  
The portion of the tendon outlined in red is  
shown on the following two pages at higher  
magnification.  
T = tendon; B = bone; C = hyaline articular  
cartilage.

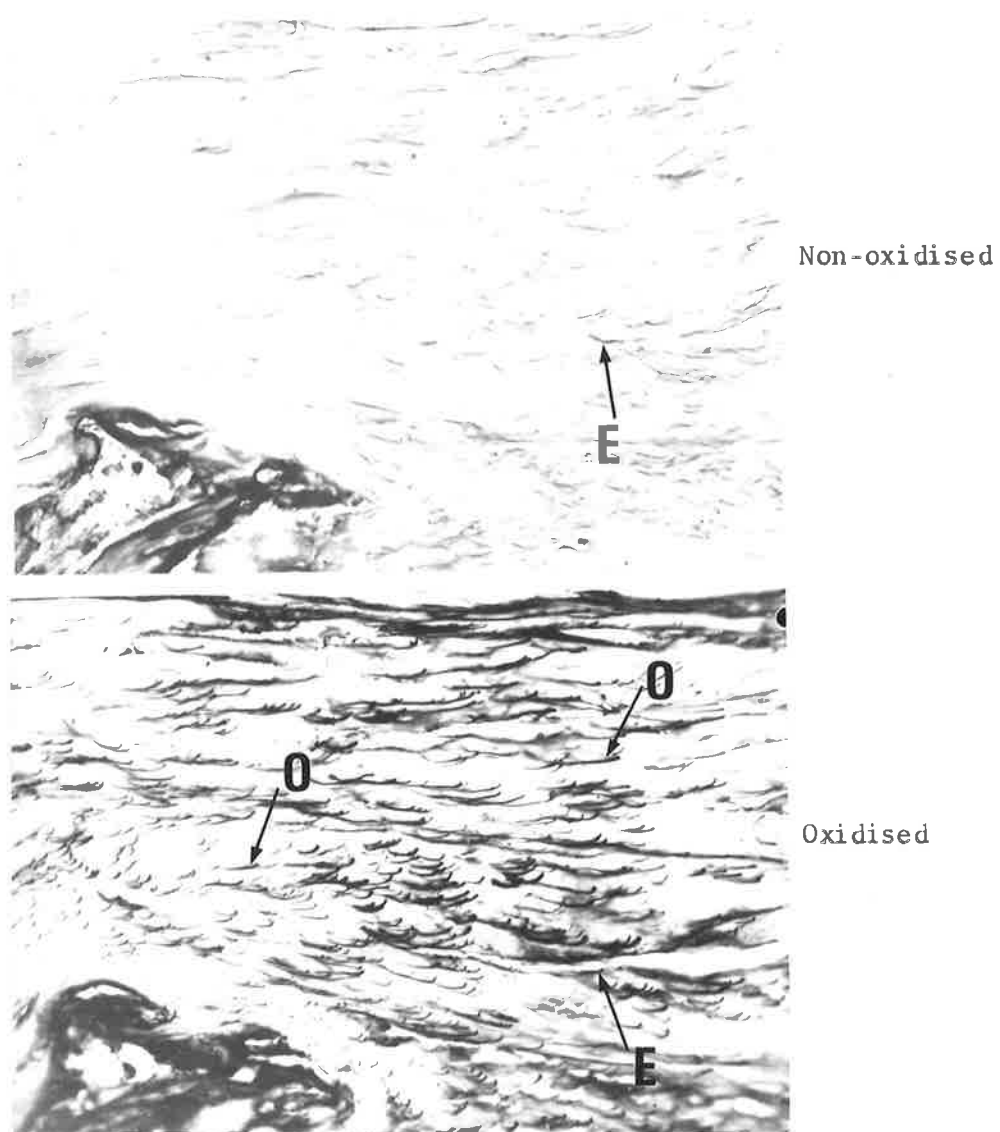


Fig. 51b. x250. Tendon adjacent to Rabbit Knee joint, representing the area outlined in fig. 51a. Oxidised and Non-oxidised, Aldehyde fuchsin-Halmi stain. Only a few elastic fibres are present in the non-oxidised control section. The large number of additional fibres present in the adjacent oxidised section are oxytalan. E = elastic; O = oxytalan fibres.




Fig. 51c. x250. Tendon adjacent to Rabbit Knee joint, representing the area outlined in fig. 51a. Oxidised and Non-oxidised, Orcein-Light green stain. Fibres are absent from the non-oxidised control section. Oxytalan fibres (arrows) are present in the adjacent oxidised section orientated along the length of the tendon.

(vii) PERIOSTEUM ADJACENT TO THE KNEE JOINT

The periosteum covers the surface of the bones but is absent from the cartilage covering their articular surfaces. It consists of vascular collagenous connective tissue that contains some elastic and oxytalan fibres. In periosteum that has no tendinous attachment to its surface, oxytalan fibres outnumber the elastic fibres present. The oxytalan fibres run parallel to the surface in the same direction as the collagen bundles (fig. 52).

Conversely, periosteum that provides attachment for muscle fibres contains abundant elastic fibres but almost no oxytalan-staining elements. The elastic fibres pass parallel to the bony surface (fig. 53).

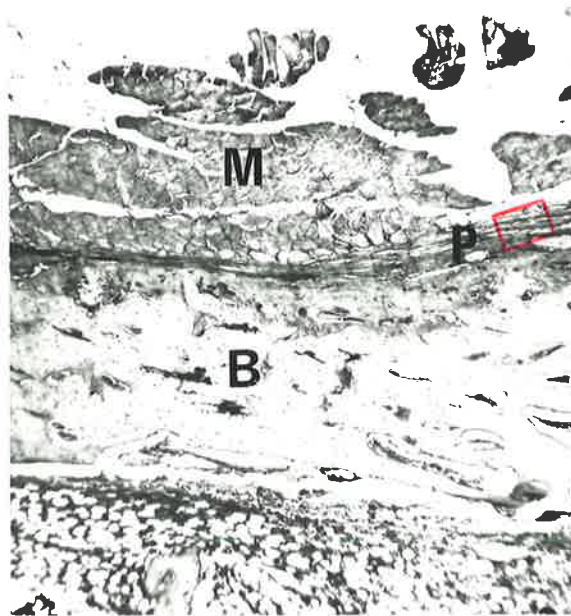


Fig. 52a. x25. Periosteum adjacent to Rabbit Knee joint. Medio-lateral longitudinal section. The portion of the periosteum outlined in red is shown overleaf at higher magnification. B = bone; P = periosteum; M = muscle in transverse section.

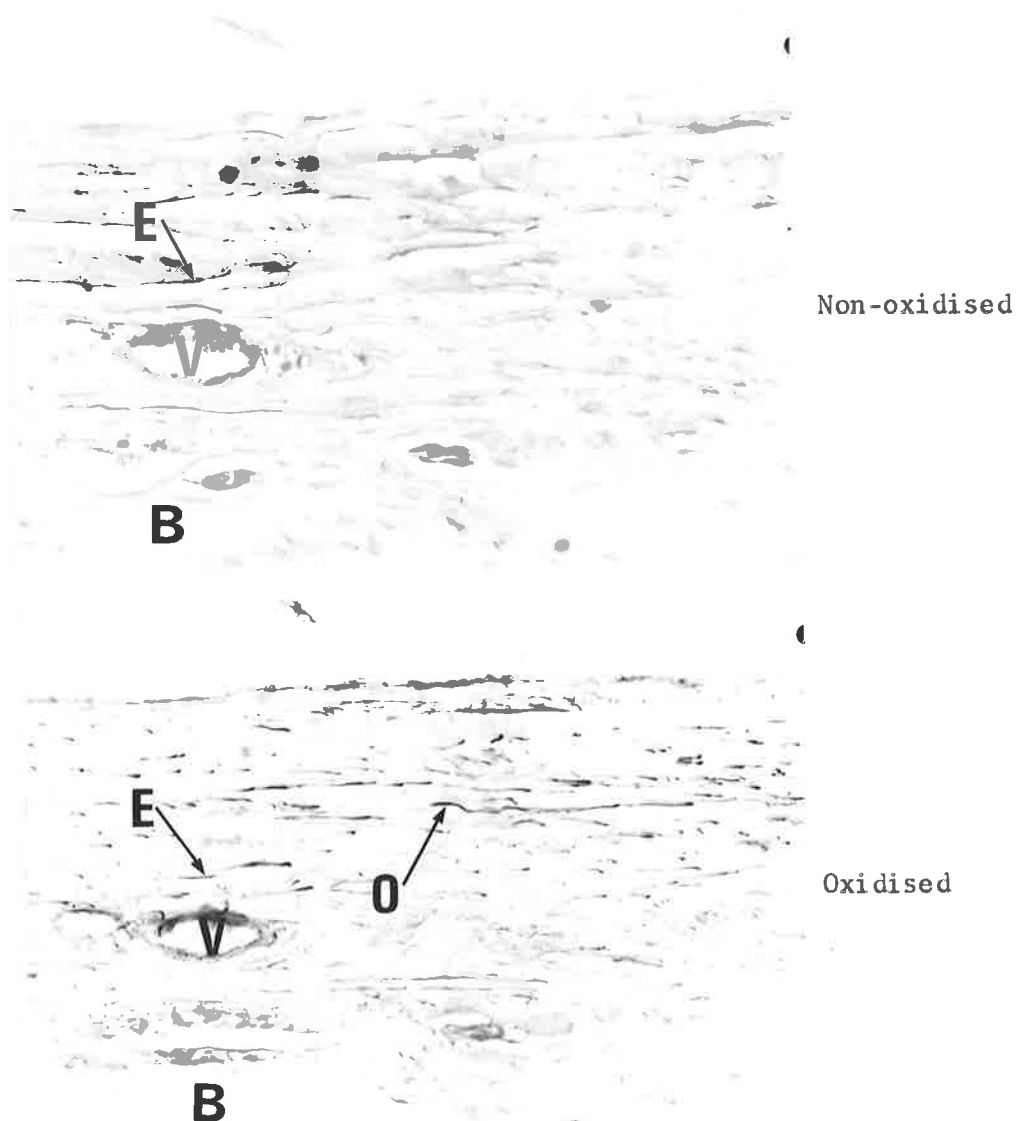


Fig. 52b. x250. Periosteum adjacent to Rabbit Knee joint, outlined in fig. 52a. Oxidised and Non-oxidised, Orcein-Light green stain. Few elastic fibres are present in the non-oxidised control section. The additional fibres present in the adjacent oxidised section are oxytalan. These fibres run parallel with the surface of the periosteum. E = elastic; O = oxytalan; V = blood vessel; B = bone.

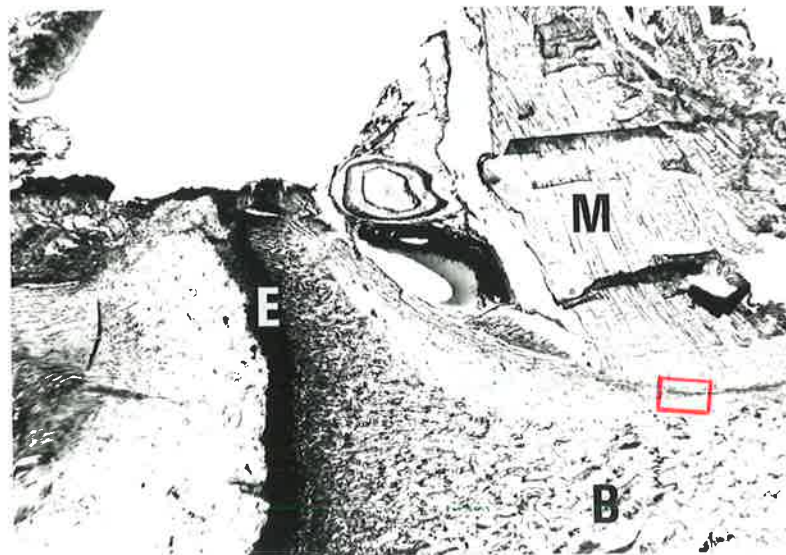


Fig. 53a. x10. Muscle insertion adjacent to Rabbit Knee joint. Antero-posterior longitudinal section. The portion of the periosteum outlined in red is shown overleaf at higher magnification. M = muscle; B = bone; E = epiphyseal plate of cartilage.

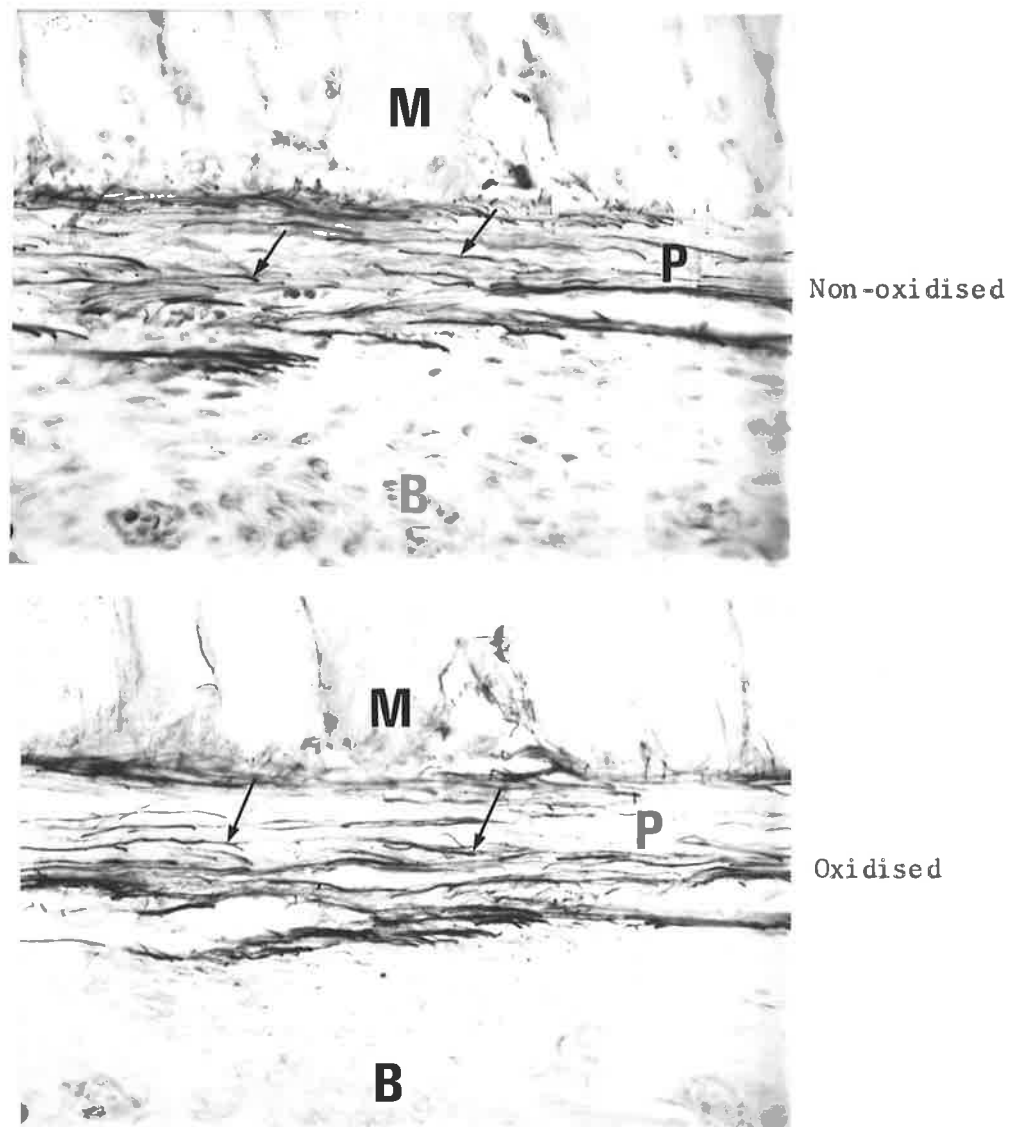


Fig. 53b. x250. Periosteum adjacent to Rabbit Knee joint, outlined in fig. 53a. Oxidised and Non-oxidised, Orcein-Light green stain. Both the serial sections have the same number of stained fibres, therefore the fibres are elastic (arrows).  
M = muscle; B = bone; P = periosteum.

(viii) PATELLA LIGAMENT

This ligament consists of a strong flat collagenous band that runs from the patella to the tibia.

Two aspects of the ligament were studied :

1. The connective tissue fibres comprising the ligament.

The rabbit patella ligament is composed of moderately dense collagenous tissue that contains many oxytalan fibres and some elastic-staining elements. The orientation of the oxytalan and elastic fibres is the same as the bundles of collagen (fig. 54).

2. Attachment to the patella bone.

Oxytalan fibres are observed to pass directly from the ligament into the periosteum. Only an occasional elastic fibre is present in the ligament near its insertion. The general direction of the oxytalan fibres is the same as the collagen bundles (fig. 55).

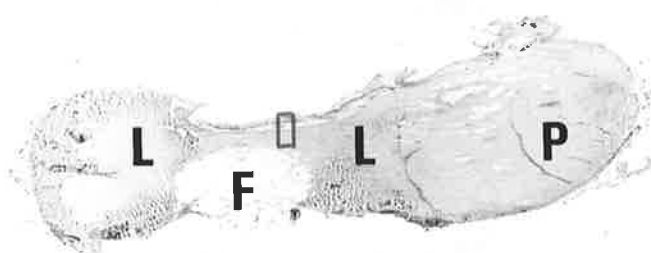


Fig. 54a. x5. Patella, Rabbit Knee joint.  
The region of the ligament outlined in red is  
shown overleaf at higher magnification.  
P = patella bone; L = patella ligament;  
F = fatty tissue.




Fig. 54b. x250. Patella Ligament Rabbit Knee joint, representing the area outlined in fig. 54a. Oxidised and Non-oxidised, Orcein-Light green stain. An occasional elastic fibre is present in the non-oxidised control section. The large number of additional fibres present in the adjacent oxidised section are oxytalan.  
E = elastic; O = oxytalan fibres.

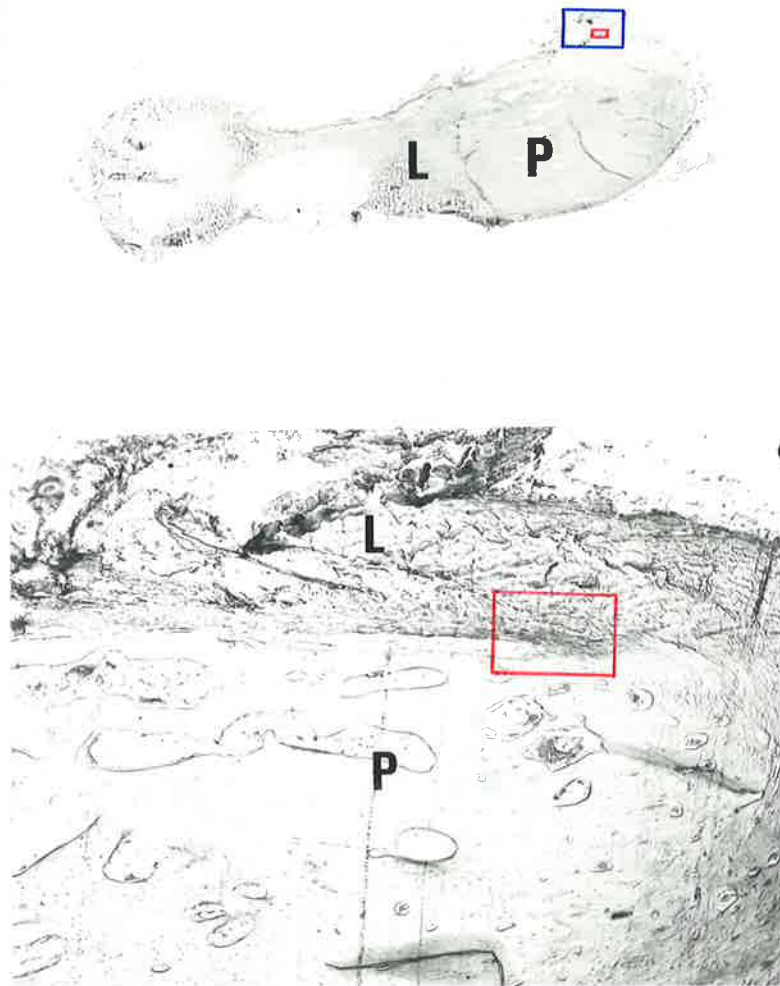


Fig. 55a. Patella, Rabbit Knee joint.

The top photomicrograph (x5) provides an overall impression of the anatomy of the structure.

The lower photomicrograph (x25) illustrates a ligamentous attachment to the patella bone. The portion of the insertion outlined in red is shown overlaid at higher magnification.

P = patella bone; L = patella ligament.

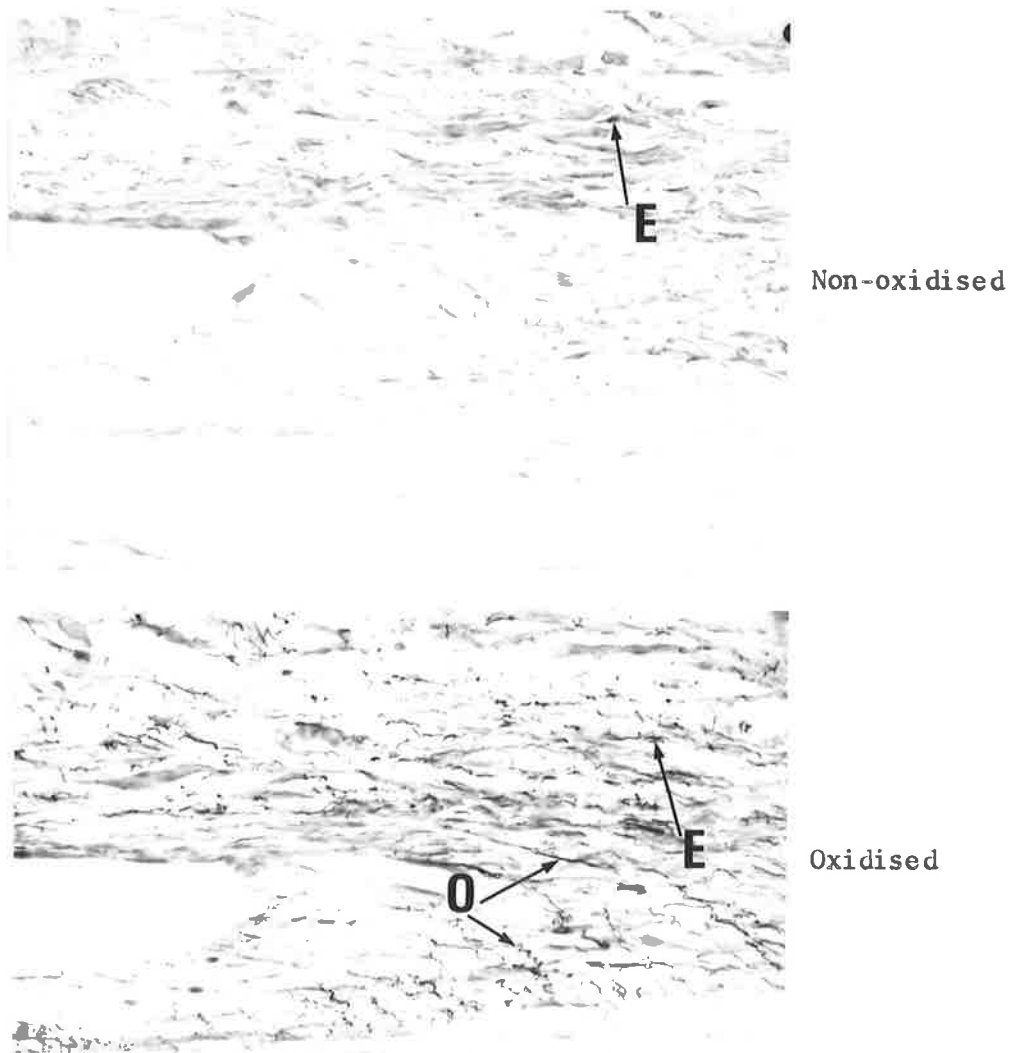


Fig. 55b. x250. Attachment of Ligament to Patella bone, Rabbit Knee joint, representing the area enclosed by the red outline in fig. 55a.

Oxidised and Non-oxidised, Orcein-Light green stain. Some elastic fibres are present in the non-oxidised control section. The additional fibres present in the adjacent oxidised section are oxytalan.

E = elastic; O = oxytalan fibres.

In addition to certain histochemical staining techniques, FULLMER (1960a) noted that enzymatic digestions may also serve to distinguish oxytalan from elastic fibres. He observed that commercial preparations of  $\beta$ -glucuronidase remove mucopolysaccharides and the stainable component from oxytalan, but not elastic, fibres in pre-oxidised tissue sections. The method used by Fullmer was employed in this investigation. (Appendix VII.5).

Representative sections from the temporomandibular and knee joints were subjected to digestion with  $\beta$ -glucuronidase both before and after tissue oxidation.

The following structures were examined for the effects of enzymatic hydrolysis :

#### TEMPOROMANDIBULAR JOINT

1. Articular surface of condyle
2. Articular disc
3. Joint capsule

#### KNEE JOINT

1. Intra-articular ligament
2. Extra-articular ligament
3. Tendon

## TEMPOROMANDIBULAR JOINT

### 1. Articular surface of Condyle

This investigation shows that elastic fibres are absent from the articular fibrous tissue overlying the condyle. However, many oxytalan-staining fibres are present (fig. 10a).

Enzymatic hydrolysis with  $\beta$ -glucuronidase has the effect of digesting the oxytalan-staining elements from the articular surface of the condyle (fig. 56).




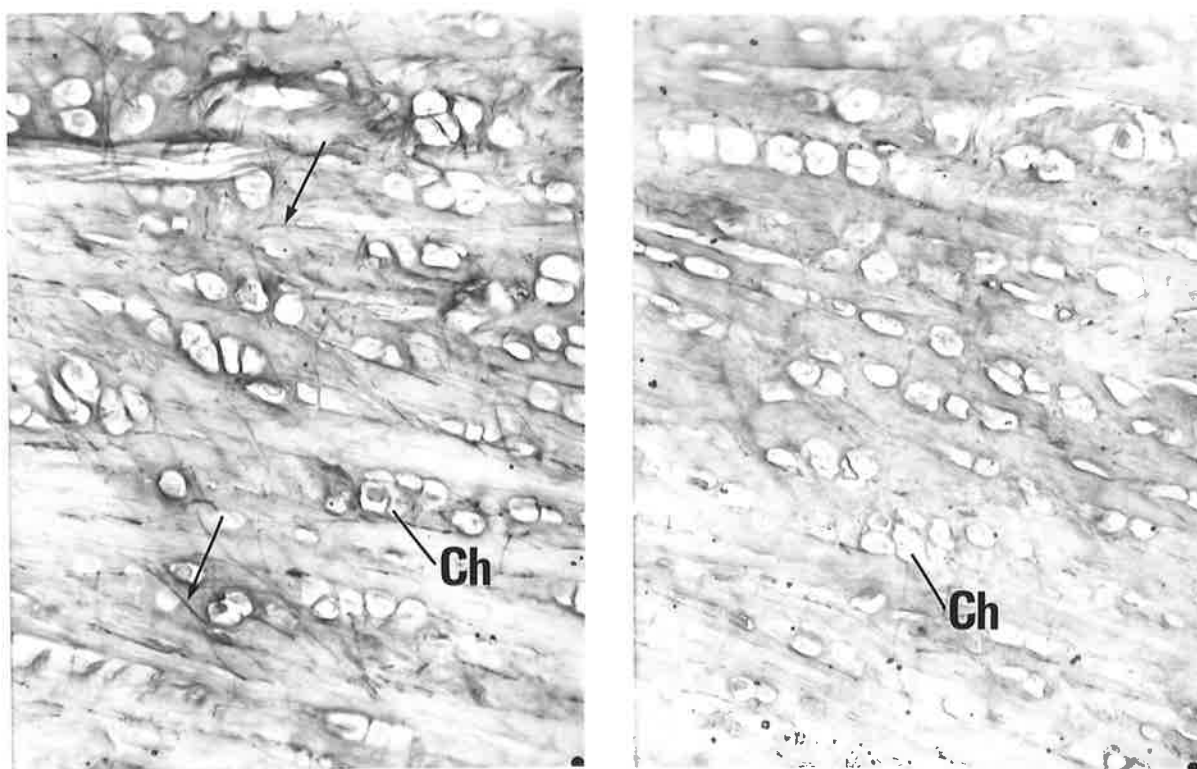
Fig. 56. x400. Articular surface of Condyle, Rabbit Temporo-mandibular joint (Sagittal section). Oxidised, Aldehyde fuchsin-Halmi stain. The control section has been oxidised after enzyme digestion. Oxytalan fibres (arrows) are present. The adjacent slide has been oxidised before enzyme digestion. Some partly digested oxytalan fibres (arrows) are still present, but the bulk has been hydrolysed.

## TEMPOROMANDIBULAR JOINT

### 2. Articular Disc

Histochemical staining with certain elastic stains has demonstrated that the articular disc contains fine oxytalan fibres that are orientated at random throughout the structure. There was an absence of elastic fibres (fig. 19).

Enzymatic hydrolysis digests the oxytalan-staining fibres from the articular disc in tissue sections that have been pre-oxidised (fig. 57).



Enzyme + Oxidation  
(control)

Oxidation + Enzyme

Fig. 57. x250. Articular Disc, Rabbit Temporomandibular joint (Sagittal section).  
Oxidised, Aldehyde fuchsin-Halmi stain.  
The control section has been oxidised after enzyme digestion. Oxytalan fibres (arrows) are distributed at random throughout the structure.  
The adjacent section has been oxidised before enzyme digestion. Some partly digested oxytalan fibres are still present, but the majority of fibres are now missing.  
Ch = chondrocyte-like cells.

## TEMPOROMANDIBULAR JOINT

### 3. Joint Capsule

The posterior part of the capsule has been shown to consist of loose vascular connective tissue containing many elastic fibres, together with some oxytalan-staining elements (fig. 31).

Following enzymatic hydrolysis of pre-oxidised sections, the oxytalan fibres are digested. The difference in the number of fibres stained compared with the control section (enzyme digestion before oxidation) is not dramatic, since few oxytalan fibres occur in this region of the capsule (fig. 58). This demonstrates the specificity of  $\beta$ -glucuronidase for digesting oxytalan, but not elastic, fibres from pre-oxidised sections.

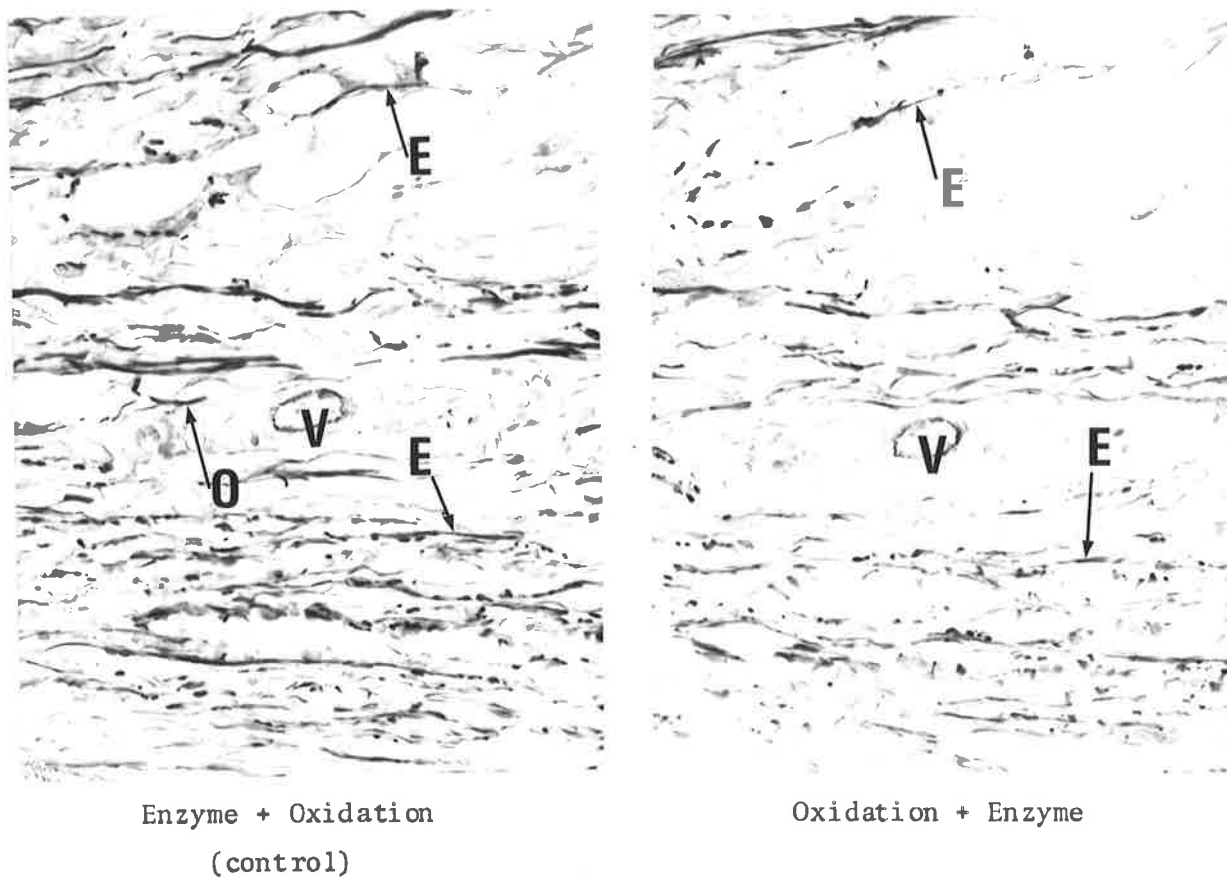



Fig. 58. x250. Posterior part of Capsule, Rabbit Temporomandibular joint (Sagittal section).  
Oxidised, Orcein-Light green stain.  
The control section has been oxidised after enzyme digestion. Both oxytalan and elastic fibres are present.  
The adjacent slide has been oxidised before enzyme digestion. The oxytalan fibres have been digested, since fewer fibres are present.  
O = oxytalan; E = elastic fibres; V = small artery.

## KNEE JOINT

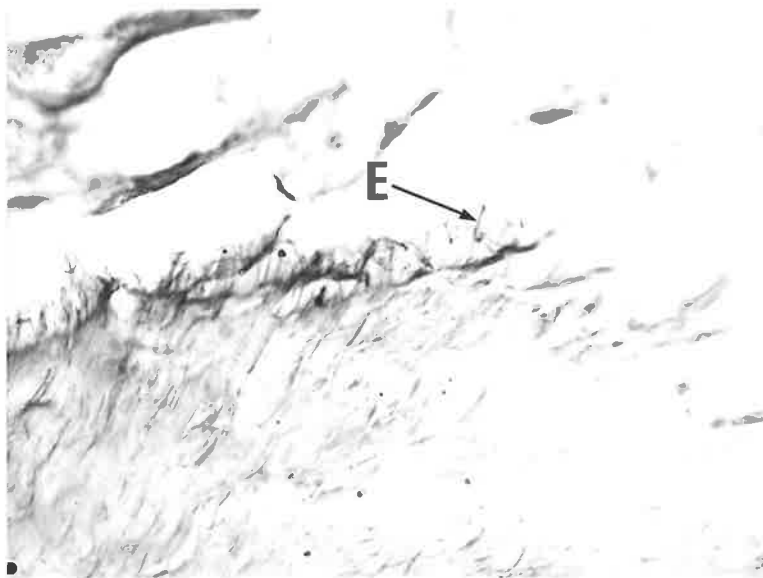
### 1. Intra-articular Ligament

The cruciate ligaments of the rabbit knee joint consist chiefly of collagen and oxytalan fibres. A few elastic fibres are also present (fig. 46).

Following enzymatic hydrolysis of pre-oxidised tissue, most of the oxytalan-staining fibres are digested. The remaining fibres are elastic and partly digested oxytalan elements (fig. 59).



Enzyme + Oxidation  
(control)



Oxidation + Enzyme

Fig. 59. x250. Intra-articular Ligament of Rabbit Knee joint (medio-lateral longitudinal section). Oxidised, Orcein-Light green stain. The control section has been oxidised after enzyme digestion. Numerous oxytalan, and some elastic, fibres are present. In the adjacent slide, oxidised before enzyme treatment, the majority of the oxytalan fibres are absent due to digestion. E = elastic; O = oxytalan fibres.

## KNEE JOINT

### 2. Extra-articular Ligament

Sections specifically stained for oxytalan and elastic fibres have demonstrated many oxytalan fibres where the ligament inserts into bone. Elastic fibres were absent when aldehyde fuchsin stain was used (fig. 49).

The effect of  $\beta$ -glucuronidase hydrolysis is to digest the oxytalan fibres from pre-oxidised sections. Application of the enzyme before oxidation does not digest the oxytalan-staining elements (fig. 60).

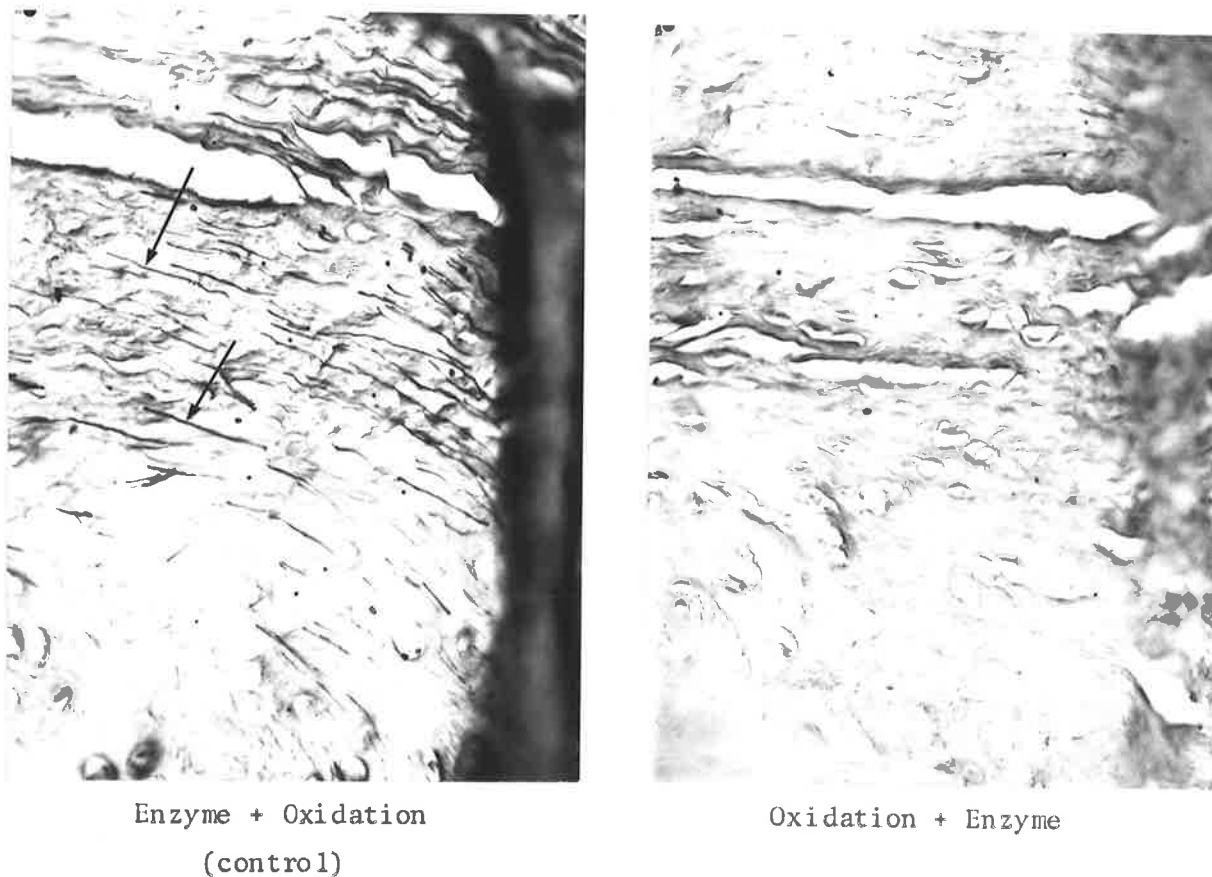


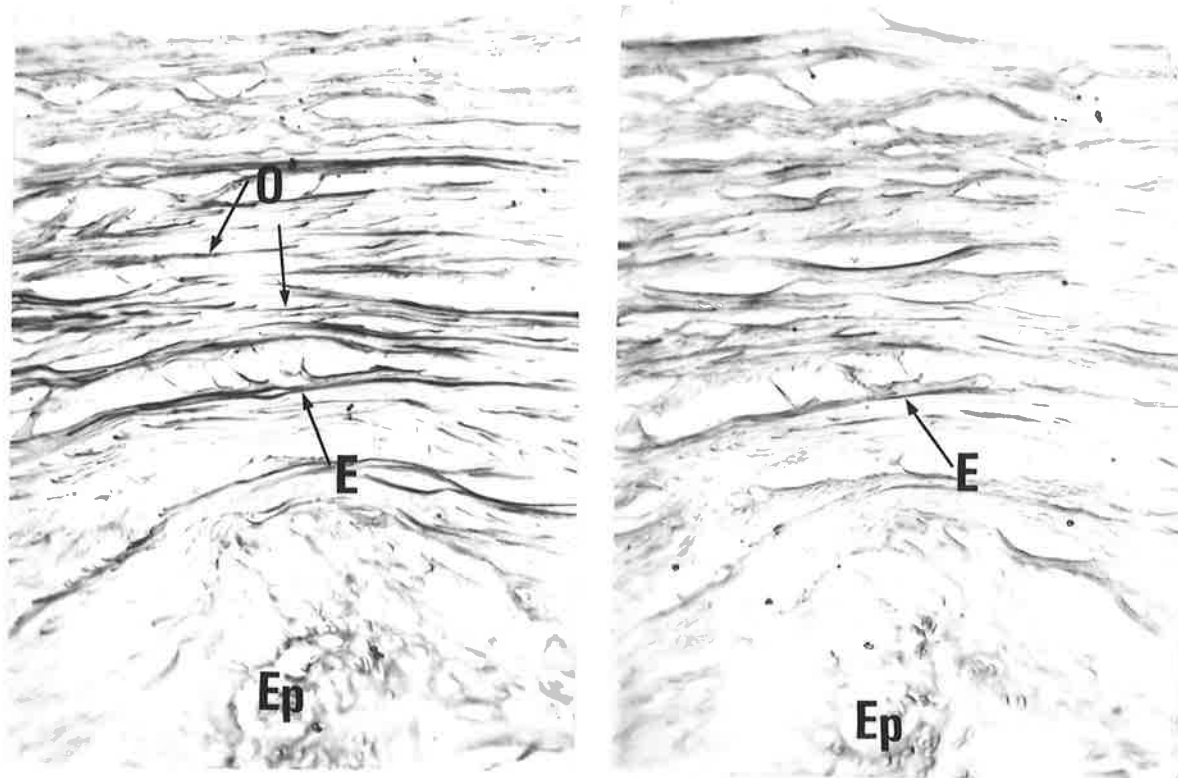
Fig. 60. x250. Extra-articular Ligament of Rabbit Knee joint (antero-posterior longitudinal section). Oxidised, Aldehyde fuchsin-Halmi stain. The control section has been oxidised after enzyme digestion. Numerous oxytalan fibres (arrows) are present. The adjacent section has been oxidised before enzyme hydrolysis. The oxytalan fibres have all been digested.

## KNEE JOINT

### 3. Tendon

It has been demonstrated that oxytalan fibres occur frequently in tendinous tissue running parallel with the collagen bundles, while only occasional elastic fibres are observed (fig. 51).

Incubation of pre-oxidised sections with  $\beta$ -glucuronidase effectively digests most of the oxytalan-staining fibres. The major portion of the fibres remaining are only lightly stained by aldehyde fuchsin and orcein (fig. 61).



Enzyme + Oxidation  
(control)

Oxidation + Enzyme

Fig. 61a. x250. Tendon adjacent to Rabbit Knee joint (medio-lateral longitudinal section).  
Oxidised, Aldehyde fuchsin-Halmi stain.  
The control section has been oxidised after enzyme digestion. Numerous oxytalan fibres and a few elastic fibres are present.  
The adjacent section has been oxidised before enzyme hydrolysis. The elastic fibres are still present, but many of the oxytalan fibres have been digested.  
E = elastic; O = oxytalan; Ep = epiphyseal plate of cartilage.

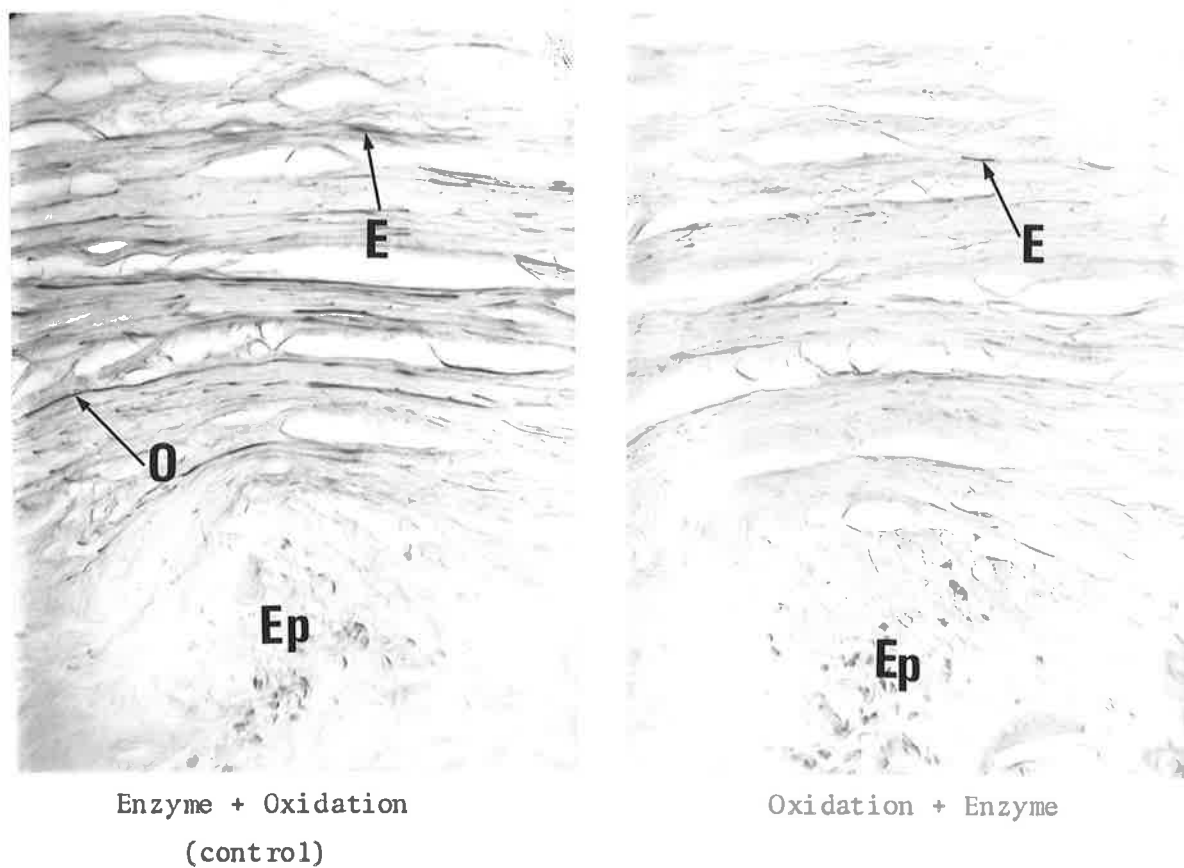


Fig. 61b. x250. Tendon adjacent to Rabbit Knee joint; the same region is shown as in fig. 61a. Oxidised, Orcein-Light green stain. The control section has been oxidised after enzyme digestion. Oxytalan fibres and some elastic-staining elements are present. The adjacent section has been oxidised before enzyme hydrolysis. The oxytalan fibres are now mostly digested. E = elastic; O = oxytalan; Ep = epiphyseal plate of cartilage.

---

TEMPOROMANDIBULAR JOINT

Both elastic and oxytalan fibres are present in the tissues comprising the temporomandibular joint of the rabbit.

Movements of the joint

Elastic fibres are only found in the joint capsule which envelops the articulation.

According to AYER (1964) elastic tissue, in combination with collagen and mucopolysaccharides, has the essential role of allowing a long-range controlled reversible deformation of the soft skeletal framework. In association with muscle this elastic tissue also forms part of a damping mechanism for contraction and stretch. Hence structures exposed to periodic deformity (or deformability) contain large amounts of elastic tissue. HAM (1969) supports this viewpoint and states that elastic fibres in loose connective tissue help to restore the tissue to its original state when a stretching force is removed.

The proportion of elastic fibres to collagen fibres in the capsular tissue suggests that the condyle is capable of a wide range of movement. The articular disc is also able to move since it is attached peripherally to the capsule. However, it has been shown in this investigation that relatively few elastic fibres occur in the

anterior portion of the capsule between the temporal bone and the disc. The head of the condyle is therefore able to move further than the disc in relation to the temporal bone. SPRINZ (1954) also observed that the anterior part of the capsular tissue connecting the disc to the temporal surface was relatively inelastic and had a firm temporal attachment.

Movement of the condyle is mainly antero-posterior, while lateral excursion is limited by the zygomatic arch. The range of anterior movement of the condyle would appear to be restricted only by the limit of elasticity of the capsule attaching to it.

#### Structural importance of the Articular Disc

The articular discs examined from the rabbit temporomandibular joints in this study consist of dense avascular connective tissue containing cartilage-like cells and many fine oxytalan fibres. Elastic fibres are absent from the structure. This histological appearance of the disc suggests that it may be adapted to bear stress during functional movements of the joint. Additional evidence for this viewpoint is derived from an anatomical evaluation of -

- (1) The relation of the mandibular coronoid process (rudimentary in the rabbit) to the joint.

The attachment of the temporalis muscle to the coronoid process is below the level of the zygomatic arch. During closure, therefore, contraction of this muscle, together with the masseter muscle, will act to force the head of the condyle towards the temporal portion of the joint lying adjacent to the

root of the zygoma (fig. 62).

(2) The articular portion of the temporal bone.

The temporal portion of the joint is small in relation to the total condylar surface capable of articulating with it. There is a likelihood, therefore, of some stress concentration at the temporal surface. By acting as a pressure pad, the articular disc may function to dissipate some of this force, and could be assisted in this function by its closer adaptation to the temporal surface than to the condyle during mandibular movements.

It is interesting to compare these findings in the rabbit with those observed for the temporomandibular joint of the domestic cat. The articulation of the cat was examined as part of a preliminary comparative study of joint histomorphology presented for the Master of Dental Surgery Qualifying Examination.

In contrast to the rabbit, the cat disc is composed of loose vascular connective tissue devoid of any cartilage-like cells or oxytalan-staining elements. Elastic fibres, however, are numerous in the structure. This histological appearance suggests that the disc may not be adapted to bear stress. The relation of the coronoid process to the joint is also significant for the following reasons :

The mandibular coronoid process is situated well above the level of the zygomatic arch so that some fibres of the temporalis muscle must travel almost vertically from the root of the zygoma to attach to it (fig. 63). Contraction of these muscle fibres during closure, at the same time as the masseter and medial pterygoid muscles are

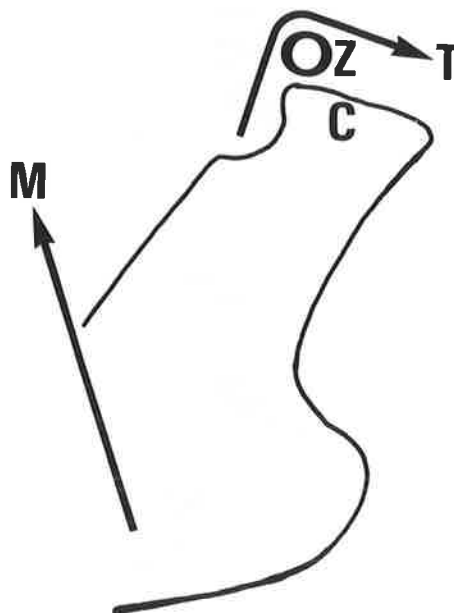


Fig. 62. Diagrammatic representation of the Rabbit Mandibular Ramus.

The arrows indicate the direction of pull of the Masseter (M) and Temporalis (T) muscles. Their combined action is to force the condyle against the temporal surface of the joint.

Z = Root of the Zygoma; C = Condyle.

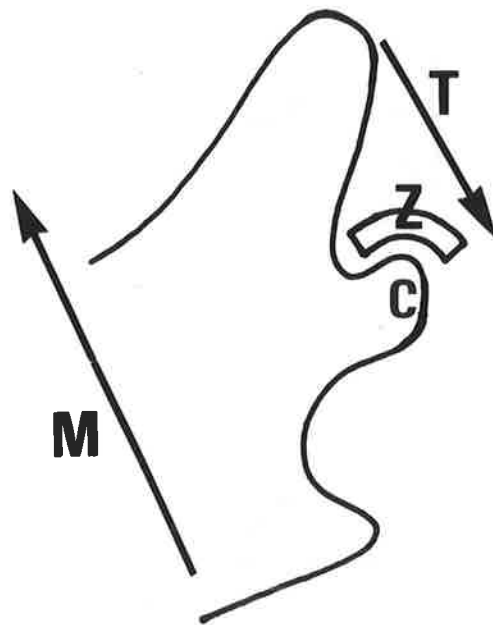


Fig. 63. Diagrammatic representation of the Cat mandibular Ramus. The arrows indicate the direction of pull of the Masseter (M) and Temporalis (T) muscles. Their combined actions tend to relieve pressure at the temporo-mandibular surfaces.  
Z = Root of the Zygoma; C = Condyle.

elevating the condyle, will act to depress the coronoid process and hence the condylar head. The effect of this action will tend to relieve any pressure on the joint structures. This finding supports the opinion of SCOTT (1955) that a similar pressure adjusting mechanism of the temporalis muscle exists in sheep and dogs as well as for man. This opinion is at variance with that of BARNETT (1954) who considered the joint of carnivores as stress-bearing. More recently, BARBENEL (1972) studied the biomechanics of the human temporomandibular joint and concluded that in this particular articulation there is load on the structure during function.

#### The significance of Oxytalan fibres

Oxytalan-staining fibres have been described in the articular surfaces of the condyle and temporal bones as well as the disc and capsule of the rabbit temporomandibular joint.

The fibres are prominent in the articular fibrous tissue covering the condyle and temporal surfaces. In these locations the oxytalan fibres nearest the surface always run parallel with the surface and for the most part are arranged in the same direction as the main functional movement of the condyle; i.e. in an antero-posterior direction. The fibres are therefore orientated in a manner opposed to the functional forces placed upon the articulating structures. The orderly arrangement of oxytalan fibres in the articular portion of the condyle contrasts with their distribution in the non-articular region. In this location oxytalan fibres have no definite orientation and tend to be arranged at random.

A few oxytalan fibres are also located in connective tissues that have elastic tissue components. In the posterior part of the capsule, consisting of relatively loose connective tissue, elastic fibres greatly outnumber the oxytalan fibres present. However, in the anterior division of the capsule connecting the disc with the temporal bone the connective tissue is relatively dense and contains more oxytalan than elastic fibres.

From an examination of the structures comprising the temporomandibular joint of the rabbit, oxytalan fibres are present in fibrous tissue containing few or no elastic fibres. Furthermore, oxytalan fibres are generally arranged similarly to the collagen fibres in a manner which suggests they may resist the stresses imposed on the tissues, whether these forces be pressure or tension. It is possible that the function of oxytalan fibres is to reinforce the resistance of the collagen bundles to distortion, while at the same time imparting some flexibility and strength to the structure.

No satisfactory explanation can be given to account for the presence of oxytalan fibres in the articular disc of the rabbit temporomandibular joint. In place of the orderly functional arrangement observed in a structure subjected to stress, the oxytalan fibres have no definite orientation when compared with the collagen bundles. The oxytalan fibres in the disc may have a different function, since the structure is already adequately strengthened by cartilage-like cells running parallel with the collagen bundles.

## KNEE JOINT

Both elastic and oxytalan fibres are present in the tissues comprising the knee joint of the rabbit.

### Elastic fibres

The distribution of elastic fibres is wider than that found for the temporomandibular joint since they occur, in varying numbers, in all the connective tissues of the extra-articular and intra-articular structures. The presence of elastic fibres in the two articular discs of the knee joint differs from the temporomandibular joint disc, where the fibres are absent. The location of elastic fibres in the disc tissue of the knee joint in its thinnest regions may allow that structure to dissipate functional forces. Elastic fibres also act to unite both discs, thereby providing some independence of movement for each of the structures. The regions of the disc containing abundant elastic fibres possibly have a function analogous to the function provided by the capsule of the temporomandibular joint.

Few elastic fibres are present in tendons and ligaments since these structures are primarily designed to provide strength and flexibility without elasticity.

The capsule of the knee joint, like the temporomandibular joint capsule, contains most elastic fibres. Both the elastic and collagen fibres run parallel with the vertical length of the capsule. Elasticity of this structure is essential since it joins the opposing bony surfaces and must therefore be able to function for the full

range of joint movements without strain.

### Oxytalan fibres

Oxytalan fibres are widely distributed throughout the rabbit knee joint. A large number are located in ligaments and tendons, particularly at their insertion into bone. The presence of oxytalan fibres in these tissues would suggest that they provide a different function to elastic fibres, which are seen infrequently. A possible role of oxytalan fibres in ligaments and tendons is to assist the collagen bundles in resisting potentially deforming forces. In this situation the fibres may be described as reinforcing the action of the collagen fibres. Also, they appear to provide an anchorage effect at the insertion of tendons and ligaments since they pass without interruption into the fibrocartilaginous tissue adjacent to the bone.

In other tissues of the rabbit knee joint the function of oxytalan fibres is not as clearly defined. Some regions of hyaline articular cartilage contain small amounts of oxytalan fibres that demonstrate no functional orientation.

Oxytalan fibres are found throughout the articular disc tissue of the knee joint, sometimes alone and occasionally in combination with elastic fibres. The large number of oxytalan fibres located near the junction of the disc with either capsular or ligamentous tissue may be related to the relatively high functional forces likely to be encountered there. Elastic fibres are absent, and the oxytalan fibres probably provide the necessary strength and flexibility, together with collagen, to resist the tissue distorting forces. In

this manner they may prevent any untoward narrowing of the disc that might impede the smooth action of the opposing condylar heads. In other regions of the disc some oxytalan fibres are found in combination with elastic fibres, and in these situations their specific function cannot be hypothesised. The number of fibres found in combination with elastic fibres, however, is not very large compared with regions where they occur singly.

Oxytalan fibres are also present with elastic fibres in the capsular tissue of the knee joint - a finding similar to that observed for the temporomandibular joint. The number of fibres is very low and their role in this tissue is uncertain.

#### COMPARISON OF FIBRES FROM THE TEMPOROMANDIBULAR AND KNEE JOINTS

The location of elastic fibres in certain temporomandibular and knee joint structures of the rabbit follows the traditional distribution of this fibre type.

Oxytalan fibres also occur in both joints where they may provide different functions in certain tissues. Their main function could be one of reinforcing the existing collagen arrangement of dense connective tissue to resist permanent deformation. In addition, the fibres may provide a degree of supplemental strength and resiliency to the tissue. The oxytalan fibres are typically present in dense avascular connective tissue devoid of elastic fibres. Although some fibres appear with elastic fibres in loose connective tissue their numbers in this situation are generally low and may only play a minor

role by imparting strength to the tissue.

The disc of the rabbit temporomandibular joint contains oxytalan fibres that are not ideally arranged to withstand functional forces. Their function in this tissue is not known. However, the relatively large number and the branching network-like arrangement of the fibres present suggests that they may function as nutrient channels for the circulation of synovial fluids.

The distribution of oxytalan fibres appears to be widespread throughout the connective tissues and although their general morphology resembles elastic fibres, they have different staining properties and enzymatic hydrolysis reactions. Because of their localisation and orientation in dense connective tissue, it is suggested that oxytalan fibres may function by reinforcing the action of collagen, thereby imparting additional strength to the particular structure.

Evidence from an earlier study suggests that the temporomandibular joint of the domestic cat may not be stress-bearing during jaw movements.

The location of oxytalan fibres within the rabbit temporomandibular joint, as well as other anatomical features of the articulation, indicates that this joint is a weight-bearing structure during function.

The findings of this investigation provide additional evidence to support Fullmer's hypothesis that oxytalan fibres are present in tissues subjected to stress.

APPENDIX VII.1Decalcification solution used in this study

Decalcification was carried out using a solution of 40 per cent formic acid, prepared by the following method :

sodium formate	...	7 gms
water	...	100 mls
formic acid	...	40 mls

APPENDIX VII.2

Method of processing tissue used in this study

After neutralising the formic acid used to decalcify the tissues, the specimens were subjected to the following processing at a constant 37°C :

1.	70% alcohol	...	...	overnight
2.	80% alcohol	...	...	1 hour
3.	90% alcohol	...	...	1 hour
4.	95% alcohol	...	...	1 hour
5.	Absolute alcohol	...	...	1 hour
6.	Absolute alcohol	...	...	1 hour
7.	Absolute alcohol	...	...	1 hour
8.	1 part absolute alcohol 1 part methyl salicylate	...	...	1 hour
9.	Methyl salicylate 0.5% celloidin	...	...	2 days
10.	Methyl salicylate 1.0% celloidin	...	...	2 days

Following clearing of the tissues with salicylate they were infused with clean paraffin wax at a constant 56°C :

1.	2/3 methyl salicylate 1/3 paraffin wax	...	...	1 hour
2.	1/2 methyl salicylate 2/2 paraffin wax	...	...	1 hour
3.	1/3 methyl salicylate 2/3 paraffin wax	...	...	1 hour
4.	Paraffin wax (first change)			2 hours
5.	Paraffin wax (second change)			2 hours
6.	Paraffin wax (third change)			overnight

Specimens were then vacuumed in paraffin wax at 56°C for approximately 15 minutes prior to blocking.

APPENDIX VII.3

Method of staining Oxytalan fibres with Aldehyde Fuchsin

The method used was after FULLMER and LILLIE (1958).

1. Deparaffinise and bring sections to water,
2. Oxidise in an aqueous solution of 10% Oxone (DuPont's monopersulphate compound) for 90 minutes,
3. Wash in running water for 2 minutes,
4. Stain with Gomori's aldehyde fuchsin\* for 8 minutes,
5. Rinse slide in two changes of 95% ethanol and leave in a third change for 5 minutes,
6. Rinse sections in 70% ethanol followed by running water,
7. Counterstain in the following solution modified by Halmi for 15 seconds :

Distilled water	...	100 mls
Light green SF	...	0.2 gm
Orange G	...	1.0 gm
Phosphotungstic acid	...	0.5 gm
Glacial acetic acid	..	1.0 ml

8. Rinse briefly in 0.2% glacial acetic acid in 95% ethanol,
9. Dehydrate and mount.

Staining reaction :

Bone and scirrhous connective tissue are stained yellow; collagen and epithelial cells, green to greenish yellow; acid mucopolysaccharides, purple; elastic and oxytalan fibres, brilliant purple.

\*Gomori's Aldehyde Fuchsin :

Add 1.0ml Conc. Hydrochloric acid and 1.0ml of paraldehyde (U.S.P.) to 100ml of a 0.5% solution of basic fuchsin in 60-70% ethanol. Allow to stand at least 24 hours before use.

APPENDIX VII.4Method of staining Oxytalan fibres with Orcein

The method used was after FULLMER (1959b).

1. Deparaffinise and bring sections to water,
2. Oxidise in an aqueous solution of 10% Oxone (DuPont's monopersulphate compound) for 90 minutes,
3. Wash in running water for 2 minutes,
4. Stain with Orcein\* for 20 minutes at 50°C,
5. Differentiate in 70% ethanol for 5 minutes (3 changes),
6. Bring sections to water,
7. Counterstain with Light green# for 10 seconds,
8. Rinse briefly in 0.2% glacial acetic acid in 95% ethanol,
9. Dehydrate and mount.

Staining reaction :

Bone and scirrhus connective tissue are stained light green; collagen and epithelial cells, pale bluish green; elastic and oxytalan fibres, brown to brownish purple.

\*Orcein preparation :

1gm of Natural orcein in 100ml of 70% ethanol, add 1.0ml Conc. Hydrochloric acid.  
Place in 60°C oven for 1hr., then filter.

#Light green preparation :

0.2gm of Light green in 200ml of 95% ethanol.

APPENDIX VII.5Method of Enzymatic Digestion

The method used was after FULLMER (1960a).

$\beta$ -glucuronidase\* was used, 15mg per 50ml 0.1M acetate buffer# (pH 4.5), and incubated for 48 hours at 37°C.

\*Sigma Chemical Company.  $\beta$ -glucuronidase from Bovine Liver.

Type B-I. Activity 530,000 Fishman Units/gm.

#The acetate buffer solution was prepared according to the Buffer Tables in :

BARKA, T. and P.J. ANDERSON 1963 Histochemistry p.405  
Hoeber Medical Division, Harper and Row, Inc. New York.

REFERENCES

- ABBIE, A.A. 1939 A masticatory adaptation peculiar to some  
Diprotodont Marsupials.  
Proc. Zool. Soc. Lond., B109:261-279.
- AYER, J.P. 1964 Elastic tissue.  
Int. Rev. Connective Tissue Res., 2:33-100.
- BAILEY'S TEXTBOOK OF HISTOLOGY 1964  
Revised by W.M. COPENHAVER.  
Ed.15. The Williams and Wilkins Co., Baltimore.
- BARBENEL, J.C. 1972 The biomechanics of the temporomandibular  
joint: A theoretical study.  
J. Biomechanics., 5:251-256.
- BARNETT, C.H. 1954 The structure and functions of fibrocartilages  
within vertebrate joints.  
J. Anat. (London)., 88:363-368.
- BARNETT, C.H., D.V. DAVIES and M.A. MacCONAILL 1961 Synovial  
joints. Their structure and mechanics.  
Longmans, London.
- BENNINGHOFF, A. 1925 Form und Bau der Gelenkknorpel in ihren  
Beziehungen zu Funktion. II Teil: Der Aufbau des Gelenkknorpel  
in seinen Beziehungen zu Funktion.  
Z. Zellforsch., 2:783-862.

- BLACKWOOD, H.J.J. 1966 Cellular remodeling in articular tissue.  
J. Dent. Res., 45:480-489.
- 1969 Pathology of the temporomandibular joint.  
J. Amer. Dent. Assn., 79:118-124.
- BOESE, L.R. 1969 Increased stability of orthodontically rotated  
teeth following gingivectomy in *Macaca nemestrina*.  
Amer. J. Orthodont., 56:273-290.
- CARMICHAEL, G.G. 1968 Observations with the light microscope on  
the distribution and connexions of the oxytalan fibre of the  
lower jaw of the mouse.  
Archs. Oral Biol., 13:765-772.
- CARMICHAEL, G.G. and H.M. FULLMER 1966 The fine structure of the  
oxytalan fibre.  
J. Cell Biol., 28:33-36.
- CARMICHAEL, G.G. and B.W. OAKES 1970 An ultrastructural study of  
elastic fibres in the articular tissue of the rat.  
Abst. Aust. Conf. Elect. Mic. (Canberra)., p.60.
- CHOUKAS, N.C. and H. SICHER 1960 The structure of the temporo-  
mandibular joint.  
Oral Surg. Oral Med. and Oral Path., 13:1203-1213.
- COOPER, R.R. and S. MISOL 1970 Tendon and ligament insertion.  
J. Bone Jt. Surg., 52-A:1-20.

- DIXON, A.D. 1962 Structure and functional significance of the intra-articular disc of the human temporomandibular joint. Oral Surg. Oral Med. and Oral Path., 15:48-61.
- EDWARDS, J.G. 1968 A study of the periodontium during orthodontic rotation of teeth. Amer. J. Orthodont., 54:441-461.
- 1970 A surgical procedure to eliminate rotational relapse. Amer. J. Orthodont., 57:35-46.
- FISHER, A.K. and H.M. FULLMER 1962 Oxytalan fibres in ameloblastomas. Oral Surg. Oral Med. and Oral Path., 15:246-248.
- FULLMER, H.M. 1958 Differential staining of connective tissue fibres in areas of stress. Science., 127:1240.
- 1959a Observations on the development of oxytalan fibres in the periodontium of man. J. Dent. Res., 38:510-518.
- 1959b The peracetic-orcein-Halmi stain: a stain for connective tissues. Stain Technol., 34:81-84.
- 1960a A comparative histochemical study of elastic, pre-elastic and oxytalan connective tissue fibres. J. Histochem. Cytochem., 8:290-295.

- 1960b Observations on the development of oxytalan fibres in dental granulomas and radicular cysts.  
A.M.A. Arch. Path., 70:59-67.
- 1961 A histochemical study of periodontal disease in the maxillary alveolar processes of 135 autopsies.  
J. Periodont., 32:206-218.
- 1965 The histochemistry of the connective tissues.  
Int. Rev. Connective Tissue Res., 3:1-76.
- 1966 Histochemical studies of the periodontium.  
J. Dent. Res., 45:469-477.
- FULLMER, H.M. and R.D. LILLIE 1958 The oxytalan fibre: a previously undescribed connective tissue fibre.  
J. Histochem. Cytochem., 6:425-430.
- FULLMER, H.M. and W.E. WITTE 1962 Periodontal membrane affected by scleroderma. A histochemical study.  
A.M.A. Arch. Path., 73:184-189.
- GOGGINS, J.F. 1966 The distribution of oxytalan connective tissue fibres in periodontal ligaments of deciduous teeth.  
Periodontics., 4:182-186.
- GREENLEE, T.K. Jr., R. ROSS and J.L. HARTMAN 1966 The fine structure of elastic fibres.  
J. Cell Biol., 30:59-71.

- GRIFFIN, C.J. and C.J. SHARPE 1960 The structure of the adult human temporomandibular meniscus.  
Aust. Dent. J., 5:190-195.
- HAM, A.W. 1969 Histology.  
Ed.6. J.B. Lippincott Co., Philadelphia.
- HAMMERMAN, D. and M. SCHUBERT 1962 Diarthrodial joints, an essay.  
Amer. J. Med., 33:555-590.
- HANKEY, G.T. 1954 Temporomandibular arthrosis.  
Brit. Dent. J., 97:249-270.
- KOHL, J. and H. ZANDER 1962 Fibres conjonctives oxytalan dans le tissu gingival interdentaire.  
Paradont., 16:23-30.
- LÖE, H. and K. NUKI 1964 Observations on the peracetic acid-aldehyde fuchsin (oxytalan) positive tissue elements in the periodontium.  
Acta Odont. Scandinav., 22:579-588.
- MACALISTER, A.D. 1954 A microscopic survey of the human temporomandibular joint.  
New Zeal. Dent. J., 50:161-172.
- MILES, A.E.W. and Jennifer A. DAWSON 1962 Elastic fibres in the articular fibrous tissue of some joints.  
Archs. Oral Biol., 7:249-252.

- MILLS, J.R.E. 1967 A comparison of lateral jaw movements in some mammals from wear facets on the teeth.  
Archs. Oral Biol., 12:645-661.
- MOFFETT, B. 1966 The morphogenesis of the temporomandibular joint.  
Amer. J. Orthodont., 52:401-415.
- MOFFETT, B.C. Jr., L.C. JOHNSON, J.B. McCABE and H.C. ASKEW 1964  
Articular remodeling in the adult human temporomandibular joint.  
Amer. J. Anat., 115:119-142.
- ÖBERG, T., G.E. CARLSSON, C.M. FAJERS and F. BERGMAN 1966 Ageing of the human temporomandibular disc with special reference to the occurrence of cartilaginous cells.  
Odont. Tidskrift., 74:122-129.
- ORBAN, B. 1944 Oral histology and embryology.  
The C.V. Mosby Co., St. Louis.
- PARSONS, F.J. 1899 The joints of mammals compared with those of man. Part 1.  
J. Anat. (London)., 34:41-68.
- RANNIE, I. 1963 Observations on the oxytalan fibre of the periodontal membrane.  
Trans. Europ. Orthodont. Soc., p.127-136.
- REES, L.A. 1954 The structure and function of the mandibular joint.  
Brit. Dent. J., 96:125-133.

- ROYDHOUSE, R. 1955 The temporomandibular joint: Upward force of the condyles on the cranium.  
J. Amer. Dent. Assn., 50:166-172.
- SCOTT, J.H. 1955 A contribution to the study of mandibular joint function.  
Brit. Dent. J., 98:345-348.
- SICHER, H. 1951 Functional anatomy of the temporomandibular articulation.  
Aust. J. Dent., 55:73-85.
- SOULE, J.D. 1967 Oxytalan fibres in the periodontal ligament of the Caiman and the Alligator (Crocodylia, Reptilia).  
J. Morph., 122:169-174.
- SPRINZ, R. 1954 Temporo-mandibular meniscectomy in rabbits.  
J. Anat. (London)., 88:514-519.
- 1965 A note on the mandibular intra-articular disc in the joints of Marsupialia and Monotremata.  
Proc. Zool. Soc. Lond., 144:327-338.
- STILWELL, D.L. Jr. and D.J. GRAY 1960 The microscopic structure of periosteum in areas of tendinous contact.  
Anat. Record., 120:663-677.
- SYMONS, N.B.B. 1952 The development of the human mandibular joint.  
J. Anat. (London)., 86:326-332.

THILANDER, B. 1964 The structure of the collagen of the  
temporo-mandibular joint in man.

Acta Odont. Scandinav., 22:135-149.