UNIVERSITY OF ADELAIDE LIBRARY
14.9.99

CHARACTERIZATION OF ISOLATED LYMPHOID AGGREGATIONS IN THE MUCOSA OF THE SMALL INTESTINE

Mahin Moghaddami

Department of Microbiology and Immunology

University of Adelaide

Adelaide, South Australia

A thesis submitted to the University of Adelaide in fulfilment of the requirement for the degree of Doctor of Philosophy.

April 1999

ABSTRACT

Novel lymphoid structures which may be sites of T-cell differentiation have been identified in rat and mouse small intestine. These structures have been designated as lymphocyte-filled villi (LFV). They are present in conventional and in mutant mice (nude, scid mice, RAG-1, LTα, LTβ, TNF α and TNF/LT knockout mice). Similar structures have been identified in the small intestine from Syrian hamsters.

The main population of lymphocytes in LFV in mice, expressed the CD45 and Thy-1 antigens. The majority of them did not stain with antibodies against either T cell (CD4, CD8, CD3, α/βTCR, γ/δTCR), B cell (B220 and anti-Ig) or natural killer (NK1.1) markers. They were located in the centers and bases of LFV and they expressed the IL-2Rα and the antigens TSA-1, Sca-2, HSA and Pgp-1. They were sensitive to hydrocortisone and a significant proportion of them were actively dividing cells.

A subset of $CD4^+$ cells was identified in the center of LFV. The lack of CD3 expression implies that they were not mature $CD4^+$ T cells. These $CD4^+$ cells were Sca-2^+, TSA-1^+ and IL-$2R^+$ and they may be early committed T cell progenitors.

Large non-lymphoid cells with irregular morphology were identified in LFV. They bear the surface markers CD11c and MHC class II molecules and they are believed to be dendritic cells. They were present in subepithelial region and also between the lymphocytes.

This thesis explored the hypothesis that structures similar to lymphocyte-filled villi in rats and mice are present in the human small intestine. Resection specimens of apparently normal human small intestine have been examined histologically and by immuno-histochemistry. Structures that resemble rodent LFV were identified in all of the specimens. The LFV contained MHC class II-positive dendritic cells, a majority of memory T cells, a variable B cell component and no evidence of immature lymphocytes

that expressed either c-kit or CD1a. The absence of HEV in these structures suggests that they are not sites of lymphocyte recirculation. LFV in adult humans do not appear to be sites of primary T cell development.

Two other isolated lymphoid aggregations (isolated lymphoid follicles and submucosal lymphoid aggregations) were also identified in these specimens. They have been shown to be components of a single structure. The complete structure contains a B cell follicle, T cells with mainly memory (CD45RO-positive) phenotype, high endothelial venules and no detectable population of immature lymphocytes. These structures appear to be related to Peyer's patches.

PRESENTATIONS AND PUBLICATIONS ARISING

Conference Presentation

Moghaddami M, Cummins A and Mayrhofer G (1995). (Oral) Histological and Immunohistological Characterization of Isolated Lymphoid Aggregations in the Mucosa of the Human Small Intestine. Australian Society for Immunology, Gold Coast, Queensland, Australia.

Moghaddami M and Mayrhofer G (1996). (Oral) Characterization of Isolated Lymphoid Aggregations in the Mucosa of the Mouse Small Intestine. First Congress of the Federation of Immunological Societies of Asia-Oceania (FIMSA), Adelaide, Australia.

Moghaddami M and Mayrhofer G (1997). (Oral) Characterization of Isolated Lymphoid Aggregations in the Mucosa of the Mouse Small Intestine. 9th International Congress of Mucosal Immunology, Sydney, Australia.

Moghaddami M, Cummins A and Mayrhofer G (1997). (Oral) Histological and Immunohistological Characterization of Isolated Lymphoid Aggregations in the Mucosa of the Human Small Intestine. 9th International Congress of Mucosal Immunology, Sydney, Australia.

Moghaddami M, Cummins A and Mayrhofer G (1998). Lymphocyte Filled Villi: Novel Lymphoid Aggregations in the Mucosa of the Human Small Intestine. 10th International Congress of Immunology, New Delhi, India.

Moghaddami M, Mayrhofer G (1999). Lymphocyte filled villi: Extrathymic T cell development in the small intestine. 10th International Congress of Mucosal Immunology, The Netherlands (submitted).

Publications

Moghaddami M, Cummins A, Mayrhofer G (1998). Lymphocyte-filled villi: comparison with other lymphoid aggregations in the mucosa of the human small intestine. Gastroenterology; 115: 1414-1425.

Moghaddami M, Mayrhofer G. $CD4^+$ immature T cells in the mouse small intestine. (in preparation).

Moghaddami M, Mayrhofer G. Lymphocyte filled villi: Extrathymic T cell development in the mouse small intestine. (in preparation).

Moghaddami M, Mayrhofer G. Lymphocyte-filled villi in scid, nude and RAG-1 gene knockout mice and in mice deficient in TNFα, LTα, LTβ or TNF plus LTα. (in preparation).

DECLARATION OF ORIGINALITY

This thesis contains no material which has been accepted for the award of any other degree or diploma in any university and, to the best of my knowledge and belief, contains no material previously published or written by another person, except where due reference is given in the text.

I give my consent to this copy of my thesis, when deposited in the university library, being made available for loan and photocopying.

MAHIN MOGHADDAMI

ACKNOWLEDGMENTS

I wish to express my sincere thanks to my supervisor Associate Professor Graham Mayrhofer for his continued support, guidance and encouragement throughout this study. I am grateful to the University of Adelaide for the University of Adelaide Postgraduate Research Award that made this study possible. I would also like to thank Dr Adrian Cummins (Gastroenterology Department, Queen Elizabeth Hospital, Adelaide, South Australia) for providing human tissues. Thanks to Dr Ken Shortman (Walter and Eliza Hall Institute of Medical Research of Melbourne, Australia) for providing the PC61, M1/69, IM7.8.1, E13 161.7 and E13 81-204 monoclonal antibodies. I am grateful to Dr Richard Boyd (Monash Medical School, Melbourne, Australia) for providing the MTS panel of monoclonal antibodies, Dr Cheng Smart (Discipline of Surgical Science, Faculty of Medicine, Newcastle, Australia) for providing P136 monoclonal antibody and Dr Tony Simmons (Institute of Medical & Veterinary Science, South Australia) for providing YTS.169.4 monoclonal antibody. Thanks to Dr John Sedgwick (Centenary Institute of Cancer Medicine and Cell Biology, University of Sydney, Australia) for providing RAG-1, LTα, LTβ, TNFα and TNF/LT knockout mice.

I am also grateful to Craig Murphy (Dept Microbiology & Immunology, University of Adelaide) for providing RAG-1 riboprobe, Llew Spargo (Institute of Medical & Veterinary Science, South Australia) for his advice on Enzyme Histochemistry.

I also wish to thank the following people for the contributions they have made to this thesis:

Marj Quin and Hans Schoppe (Department of Pathology, University of Adelaide) for their assistance in preparing lots of histological sections.

John Macrill, Shelley Pezy and Gail Bezuidenhoudt for their assistance and encouragement.

Finally, I would like to thank my husband Vira and my daughters Mahroo and Golroo for all their support and patience.

TABLE OF CONTENTS

CHAPTER 1 INTRODUCTION

1.1	INTRODUCTION AND LITERATURE REVIEW	1
1.1.1	General Organization of the Gastrointestinal Tract	2
1.1.2	The Gut-Associated Lymphoid Tissues (GALT)	5
1.1.2.1	Intraepithelial lymphocytes (IEL)	5
1.1.2.2	Lamina propria lymphocytes (LPL)	8
1.1.2.3	Peyer's patches(PP)	10
1.1.2.4	Isolated lymphoid follicles (ILF)	15
1.1.3	The Effect of Lymphotoxin alpha, Lymphotoxin beta, Tumor Necrosis Factor alpha , Tumor Necrosis Factor and Lymphotoxin alpha in the Development of Lymphoid Organs	17
1.1.3.1	Abnormal development of peripheral lymphoid organs in lymphotoxin alpha (LT-α) deficient mice	17
1.1.3.2	Abnormal development of secondary lymphoid tissues in lymphotoxin beta (LT-β) deficient mice	19
1.1.3.3	Role of TNF in development of peripheral lymphoid organs	19
1.1.3.4	Role of TNF-α and LT-α in lymphoid organogenesis	20
1.1.4	Molecular and Cellular Events of T cell Development	22
I.1.4.1	Early progenitors of T cells in the thymus	22
1.1.4.2	Role of IL-2 and IL-7 in T cell development in the thymus	30
1.1.4.3	T cell receptor gene rearrangement and thymocyte differentiation	33
1.1.4.4	Phenotypic analysis of thymocytes in immunodeficient mice	37
1.1.4.4.1	Severe Combined Immunodeficient (scid) Mice	37
1.1.4.4.2	RAG-1 Knockout Mice	38
1.1.5	Extrathymic T cell Differentiation	39
1.1.5.1	Characteristics of thymus-independent T cells	43
1.1.5.1.1	Hepatic Mononuclear Cells (MNC)	43
1.1.5.1.2	Intraepithelial Lymphocytes (IEL) in the Mouse Intestine	46
1.1.5.1.3	Lymphocyte-filled Villi (LFV) and Cryptopatches	54

CHAPTER 2 MATERIALS AND METHODS

2.1	STUDIES IN MICE AND HAMSTERS	57
2.1.1	Animals	57
2.1.1.1	Mice	57
2.1.1.2	Hamsters	57

2.1.2	Procedure for killing animals	58
2.1.3	Immunological Reagents	58
2.1.3.1	Monoclonal antibodies	58
2.1.3.2	Polyclonal antisera	58
2.1.3.3	Tyramide signal amplification in immunohistochemistry	59
2.1.4	Histology	60
2.1.4.1	Tissue preparation	60
2.1.4.2	Counting of lymphocyte-filled villi	60
2.1.4.3	Measuring the diameter of LFV	60
2.1.5	Immunohistochemistry	61
2.1.5.1	Tissue Processing	61
2.1.5.2	Immunohistochemical Methods	61
2.1.5.2.1	Immunoperoxidase Staining	61
2.1.5.2.2	Single Colour Conventional Immunofluorescence Staining	62
2.1.5.2.3	Single Colour Immunofluorescence (Signal Amplification Method)	62
2.1.5.2.4	Dual-colour Immunofluorescence Staining (Conventional Method)	63
2.1.5.2.5	Dual-colour Immunofluorescence staining with Signal Amplification	64
2.1.6	Photography	64
2.1.7	Enzyme Histochemistry	65
2.1.7.1	Procedure for detecting acid phosphatase	65
2.1.7.2	Procedure for detecting non-specific esterase	66
2.1.8	Cortisone Resistance of Lymphocytes in Lymphocyte-filled Villi	66
2.1.8.1	Hydrocortisone treatment	66
2.1.8.2	Statistical analysis	66
2.1.9	Labelling in vivo with ^{3}H Thymidine	66
2.2	STUDIES IN HUMAN	67
2.2.1	Small Bowel Specimens	67
2.2.2	Immunological & immunohistochemical reagents	68
2.2.3	Histology	69
2.2.4	Immunohistochemistry	69
2.2.5	Combined histochemistry & Immuno-histochemistry	70
2.2.6	Intraepithelial Lymphocyte (IEL) Counts	70
2.2.7	Statistical analysis	70
2.2.8	Photography	71
2.2.9	Magnification	71

CHAPTER 3 CHARACTERISATION OF ISOLATED LYMPHOID AGGREGATIONS IN THE MUCOSA OF THE MOUSE AND HAMSTER SMALL INTESTINE

3.1	INTRODUCTION	72
3.2	RESULTS	72
3.2.1	Histological Observations in Normal Mice and Hamsters	72
3.2.1.1	Mice	72
3.2.1.2	Hamsters	74
3.2.2	Histological Observations in Nude Mice, Scid Mice and RAG-1 Gene Knockout Mice	74
3.2.3	Histological Observations in Mice Deficient in TNFα, LTα, LTβ or TNF plus LTα	74
3.2.4	Identification the Surface Antigen Phenotype of the Cells in LFV in Normal Mice by Immunohistochemistry and Single-Colour Immunofluorescence	77
3.2.5	Characterization of Large and Irregular Cells in LFV	78
3.2.5.1	Single-colour immunohistochemistry	78
3.2.5.2	Histochemical analysis of acid phosphatase and non-specific esterase activities in the LFV	79
3.2.6	Comparison between the Antigens Expressed by Cells in the LFV, Bone Marrow Haematopoietic Stem Cells and Thymocytes	80
3.2.6.1	Expression of CD25	80
3.2.6.2	Expression of stem cell antigen 2 (Sca-2)	81
3.2.6.3	Expression of stem cell antigen 1 (Sca-1)	81
3.2.6.4	Expression of heat stable antigen (HSA)	82
3.2.6.5	Expression of Pgp-1 antigen (CD44)	82
3.2.6.6	Expression of antigens detected by the MTS panel of monoclonal antibodies	83
3.2.7	Expression of Thymic Stromal Antigens on the Non-lymphoid Cells in LFV	84
3.2.8	Expression of Some T cell Markers by Dendritic Cells in LFV and Comparison with Thymic Dendritic Cells by Dual-colour Immunofluorescence Staining	85
3.3	DISCUSSION	88

CHAPTER 4 IDENTIFICATION OF CELL SURFACE MARKERS IN THE LYMPHOCYTE-FILLED VILLI (LFV) OF T CELL-DEFICIENT MUTANT MICE

4.1 INTRODUCTION 95

4.2 The Surface Antigen Phenotype of Lymphocytes in LFV in Nude Mice 97

4.3 The Surface Antigen Phenotype of Lymphocytes in LFV in Scid Mice 98

4.4 The Surface Antigen Phenotype of Lymphocytes in LFV in RAG-1 Gene Knockout Mice 99

4.5 DISCUSSION 102

CHAPTER 5 FURTHER CHARACTERIZATION OF THE LYMPHOCYTES IN LFV BY DUAL COLOUR IMMUNOFLUORESCENCE AND OTHER BIOLOGICAL PROPERTIES

5.1 INTRODUCTION 105

5.2 Further Characterization of Cell Surface Markers by Dual Colour Immunofluorescence 107

5.3 Cortisone Resistance of Lymphocytes in LFV 110

5.4 Cell Division by Lymphocytes in LFV 111

5.5 Assessment of RAG-1 Gene Expression by Lymphocytes in LFV 112

5.6 DISCUSSION 114

CHAPTER 6 CHARACTERIZATION OF ISOLATED LYMPHOID AGGREGATIONS IN THE MUCOSA OF THE HUMAN SMALL INTESTINE

6.1 INTRODUCTION 119

6.2 RESULTS 120

6.2.1 Histological Observations 120

6.2.1.1 Peyer's patches (PP) 120

6.2.1.2 Structure of isolated lymphoid follicles (ILF) and submucosal lymphoid aggregates (SLA) 121

6.2.1.3 Lymphocyte-filled villi (LFV) 122
6.2.1.4 Intraepithelial lymphocytes (IEL) in the epithelium covering ILF and LFV 122

6.2.2 Identification of Cell Surface Markers by Immunohistochemistry 123
6.2.2.1 Peyer's patches (PP) and classical villi 123
6.2.2.2 Isolated lymphoid follicles (ILF) 124
6.2.2.3 Lymphocyte-filled villi (LFV) 125

6.2.3 Subsets of Intraepithelial Lymphocytes (IEL) in the Epithelium of Lymphoid Aggregations 128

6.4 DISCUSSION 130

CHAPTER 7 CONCLUSION

7.1 SUMMARY AND CONCLUSION 138

7.1.1 LFV in Mice 138

7.1.2 LFV in Humans 142

7.2 CONCLUSION AND FUTURE DIRECTIONS 145

REFERENCES 147

CHAPTER 1

INTRODUCTION

UNIVERSITY OF ADELAIDE LIBRARY

1.1 INTRODUCTION AND LITERATURE REVIEW

The gut is a major site of initial contact between foreign antigenic materials and immunologically competent cells. The intrinsic gut associated lymphoid tissues (GALT) are comprised of non-organized (diffuse) lymphoid cells in the intestinal mucosa and organized lymphoid aggregations, the most prominent of which are Peyer's patches (PP). The mesenteric lymph nodes are extrinsic components of the GALT (Keren, 1992).

The lymphoid aggregations (LA) which have received most attention are the small intestinal Peyer's patches. The structure and the cellular composition of human (Owen & Jones, 1974; Spencer *et al.*, 1986a; Farstad *et al.*, 1993) and mouse (Smith & Peacock, 1980; Rowinski *et al.*, 1984; Ermak & Owen, 1986; Ruedl *et al.*, 1996; Ruedl & Hubele, 1997) PP have been studied by several groups of workers. Other forms of lymphoid aggregations that have been described in the wall of the human small intestine are isolated lymphoid follicles (ILF), which lie within the mucosa and submucosal lymphoid aggregations (SLA), which lie external to the muscularis mucosa (Morson & Dawson, 1979). There is little published information regarding the histological organization of either ILF or SLA, or about their relationships to PP. All of these structures are believed to be secondary lymphoid organs (Keren, 1992).

In the chicken, an additional specialized lympho-epithelial organ can be found as an outgrowth of the hind gut. This is the bursa of Fabricius. The fact that the bursa of Fabricius is part of the intestine led to speculation that mammalian GALT might serve as a site of primary lymphoid development (reviewed by Croitoru & Bienenstock, 1994). However, despite early claims that Peyer's patches in rabbits had primary lymphoid functions (Good & Finstad, 1967), only the large Peyer's patch in the distal ileum of young ruminants appears to be a site of primary lymphocyte (B cell) development in mammals (Reynolds & Morris, 1983). In contrast, recent evidence (Lefrancois & Pudding, 1995;

Rocha *et al.*, 1995) suggests that the epithelium of the human (Latthe *et al.*, 1994; Lynch *et al.*, 1995; Lundqvist *et al.*, 1995) and mouse (Guy-Grand *et al.*, 1991; Guy-Grand *et al.*, 1992) small intestine may be a site of diffuse primary extrathymic T cell differentiation.

1.1.1 General Organization of the Gastrointestinal Tract

The small intestine extends from the pylorus to the caecum. It may be divided into three parts: the duodenum, the jejunum and the ileum. All segments of the small intestine are organized into four layers (Fig 1), of which the innermost is the mucosa, which is structurally and functionally the most complex area. The mucosa rests on the submucosa, beneath which is the muscularis externa. The outermost layer is termed the serosa (Antonioli & Madara, 1992).

The mucosa consists of three elements: an epithelial lining, a supporting lamina propria and a thin layer of smooth muscle, the muscularis mucosa. The epithelium varies in composition in different parts of the gut (Antonioli & Madara, 1992). The epithelial cells covering the villi are columnar absorptive cells (the enterocytes). They have refractile brush borders and basally located nuclei (Perera *et al.*, 1975). Goblet cells are scattered among the enterocytes but they decrease in number progressively towards the villous tip (Whitehead, 1990). The numbers of goblet cells increase towards the ileum, where the villi become proportionately taller (Price, 1985). At the bases of the villi are the crypts of Lieberkühn, which extend radially to the level of the muscularis mucosa. These contain the enteroblasts, which give rise to new enterocytes. The enterocytes mature as they migrate onto the villous surface. Paneth cells are also found within the crypts (Price, 1985). The presence of HLA-DR antigens on the villus enterocytes but not on the immature enterocytes in the crypts of healthy tissue in the small intestine has been well documented in humans (Scott *et al.*, 1980; Spencer *et al.*, 1986b), rats (Mason *et al.*, 1981; Barclay & Mason, 1982; Mayerhofer *et al.*, 1983) and mice (Bland, 1988; Wilson *et al.*, 1990).

The epithelium rests on a mesenchymal compartment termed the lamina propria; it contains connective tissue, smooth muscle fibres in some areas, nerve fibres, and blood vessels (Antonioli & Madara, 1992). The normal lamina propria also contains macrophages, dendritic cells, mast cells, plasma cells, lymphocytes and eosinophils (Morson & Dawson, 1979; Selby *et al.*, 1983; Cerf-Bensussan *et al.*, 1983; Hume *et al.*, 1984; Pavli *et al.*, 1990). The third and deepest layer of the mucosa is the muscularis mucosa, a double layer of smooth muscle consisting of an inner circular and outer longitudinal band or spiral, that separates the lamina propria from the submucosa (Antonioli & Madara, 1992).

The submucosa is an area where larger blood vessels and nerve ganglion cells (Meissner's plexus) can be appraised and where lymphoid cells and lymphatics may be seen (Perera *et al.*, 1975). The muscularis externa consists of continuous inner circular and outer longitudinal layers of smooth muscle and it is present throughout the length of the small intestine. Between the two muscle coats lies the ganglion cells of the myenteric autonomic plexus (Auerbach's plexus) (Morson & Dawson, 1979).

The intestine is covered on its outer surface by a protective layer, the serosa. The serosa is formed of mesenchymal elements (fibro-adipose tissue, vessels), on which lies a single layer of mesothelial cells. The serosa forms a natural barrier to the spread of inflammatory and malignant processes. A small number of mononuclear inflammatory cells may normally be identified in this layer (Antonioli & Madara, 1992).

Fig 1-The general plan of the gastrointestinal tract

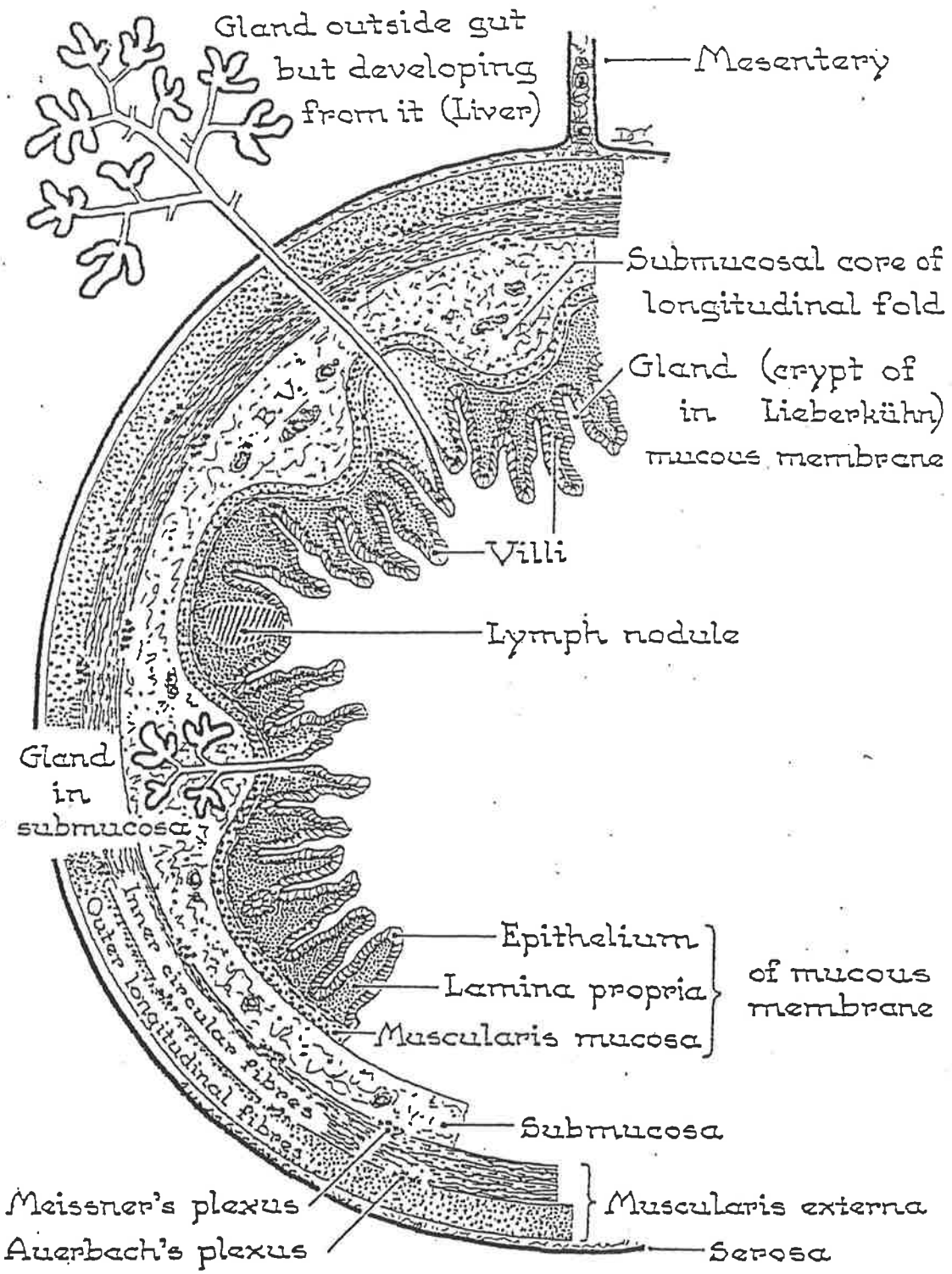

(Ham AW. Histology 5th ed. Philadelphia & Montreal: Lippincott, 1965)

1.1.2 The Gut-Associated Lymphoid Tissues (GALT)

The lymphoid tissues of the wall of the human gastrointestinal tract have four recognized anatomical components:

Lymphocytes situated basally between the epithelial cells of the mucous membranes: the *intraepithelial lymphocytes (IEL).*

Lymphocytes arranged loosely in the connective tissues of the mucosal lamina propria: the *lamina propria lymphocytes (LPL).*

Specialized nodules of lymphoid tissue in the mucosa of the small intestine, particularly the ileum. In the small intestine, these consist of *Peyer's patches (PP)* and *solitary mucosal lymphoid follicles.*

Important additional features of the immunological apparatus of the extended gastrointestinal tract are the pharyngeal tonsils, the regional lymph nodes and the reticuloendothelial tissues of the liver (Shorter & Tomasi, 1982).

1.1.2.1 Intraepithelial lymphocytes (IEL)

Intestinal intraepithelial lymphocytes are a phenotypically distinct T cell population of unknown function. They are located normally within the epithelial layer, near the basement membrane. Unlike epithelial cells, the IEL do not migrate along the villi (Marsh, 1975a) but they are capable of crossing the basement membrane to enter the lamina propria (Meader & Landers, 1967; Lundqvist *et al.*, 1995), suggesting transmigration.

The origin of most cells in the IEL compartment is not clear. Blumberg *et al.* (1993) have shown that in humans at any particular time, the majority of IEL are derived from the expansion of a relatively few T cell clones and that these clones can utilize a large number of different Vβ genes. IEL appear by 11-20 weeks of gestation in humans (Orlic &

Lev, 1977). Counts of IEL in adult human small bowel range from 6-40 per 100 villous epithelial cells (Ferguson & Murray, 1971).

IEL vary considerably in size and shape and display moderately stained nuclei and pale cytoplasm (Marsh, 1975b). Approximately 30 to 50% of IEL have been shown to contain cytoplasmic granules (Rudzick & Bienenstock, 1974; Cerf-Bensussan *et al.*, 1985). In rats, IEL are present at birth (Mayrhofer & Pitts, 1986) but in mice, they have been reported to appear in the 3rd week after birth. Thereafter, the number of lymphocytes increases weekly (Ferguson & Parrott, 1972). The number of IEL are reduced markedly in the intestines of adult germ free mice (Crabbe *et al.*, 1970) and in grafts of fetal intestine that were placed under the kidney capsule (Ferguson & Parrott, 1972). The numbers of IEL are influenced considerably by the presence of food and bacterial antigens in the intestine (Kagnoff, 1987). The number of IEL increases during infancy in rats and humans (Cummins *et al.*, 1988a; Machado *et al.*, 1994). After microbial colonization, in germ free mice, the numbers of α/β TCR^+ intestinal IEL that express the CD8 molecule increase gradually, but the numbers of γ/δ TCR^+ IEL remain nearly constant (Umesaki *et al.*, 1993). In addition, *in vitro* stimulation of IEL with staphylococcal enterotoxin B (SEB) results in the expansion of IEL expressing the α/β TCR and the CD8 α/β heterodimer (thymus dependent) but expansion is not seen the IEL bearing the $CD8^+\alpha\alpha$ homodimer (thymus independent cells) (Siebrecht *et al.*, 1993). Similarly, following intraduodenal infection of mice with reovirus, $CD8^+$ cells that express the α/β TCR (T dependent cells) appear rapidly in PP and in the IEL compartment (Cuff *et al.*, 1993).

The intestinal IEL have been classified into two groups; those that are derived from migrants of thymic origin (Guy-Grand *et al.*, 1978) and those that are thought to arise from precursors which have undergone differentiation in the small intestine (Guy-Grand *et al.*, 1991). The thymus-derived IEL appear to be the progeny of blasts that are induced by

antigenic stimulation in the Peyer's patches (Guy-Grand *et al.*, 1978; Dunkley & Husband, 1987). These blasts, after passage through the mesenteric lymph node and thoracic duct lymph, disseminate through the blood to the intestinal mucosa (Guy-Grand *et al.*, 1978). In the rat, Mayrhofer and Whately (1983) showed that some IEL in radiation chimeras arise from donor bone marrow in athymic recipients, indicating their independence of the thymus. At least 60% of IEL in mouse small intestine are thymus-independent and do not express either surface or cytoplasmic immunoglobulin (Ernst *et al.*, 1985).

Most of the intraepithelial lymphocytes in humans (Cerf-Bensussan *et al.*, 1983), mice (Guy-Grand *et al.*, 1978), rats (Lyscom & Brueton, 1982) and guinea-pigs (Arnaud-Battandier *et al.*, 1978) express pan T cell markers. The majority of IEL from the small intestine of mice are $CD3^+$ T cells (Boll *et al.*, 1995). These cells express the $\gamma\delta$ TCR molecule (Goodman & Lefrancois, 1988; Bonneville *et al.*, 1988). However, in humans and in rats the majority of intestinal IEL are $CD8^+$, α/β TCR^+ cells (Jarry *et al.*, 1990; Fangmann *et al.*, 1991). About 10% of intestinal IEL in adult human express the α chain but not the β chain of CD8 (Jarry *et al.*, 1990) but although $CD8\alpha\beta$ cells predominate in post-natal intestine, many $CD8\alpha\alpha$ cells can be identified in the epithelium in human fetal intestine (16-24 weeks gestation). The $CD8\alpha\alpha$ cells are virtually all $TCR\alpha/\beta^+$ and these cells in the fetal intestine may be thymus-independent and differentiate in the gut mucosa (Latthe *et al.*, 1994). In addition, a small fraction of adult human intestinal IEL express the CD $8\alpha\alpha$ homodimer and most of these cells also use the α/β T-cell receptor (Taplin *et al.*, 1996). The source of TCR γ/δ^+ IEL in human is unknown, but they are unlikely to originate from PP (Farstad *et al.*, 1993). The expression of CD1a, a marker of immature cortical thymocytes, by a significant proportion of the cells suggests that they may differentiate locally in the epithelium (Robijn *et al.*, 1993).

Most IEL in the human small intestine bear the memory T cell marker CD45RO (Jarry *et al.*, 1990) and less than 2% of the $CD3^+$ IEL are found to express $CD45RA^+$ (marker of naive T cells) (Halstensen *et al.*, 1990). Few intestinal intraepithelial T lymphocytes in normal individuals express the Ki-67 antigen (expressed by cells in cell cycle) or CD25 (IL-2R) (Halstensen & Brandtzaeg, 1993). In mice also, few IEL express CD25 (Lefrancois, 1987; Mosley *et al.*, 1991), implying that IEL are not activated. Intestinal IEL proliferate weakly to CD3/TCR ligation and they do not respond to stimulation with the mitogen Con A or calcium ionophore plus PMA by either proliferation or expression of CD25 (Sydora *et al.*, 1993). The IEL compartment in mouse (Guy-Grand *et al.*, 1978), rat (Lyscom & Brueton, 1982) and human (Selby *et al.*, 1981; Cerf-Bensussan *et al.*, 1985) small intestine contain virtually no surface immunoglobulin-bearing B cells (less than 1%) or plasma cells and only rare cells express class II MHC antigens (Selby *et al.*, 1981).

The biological functions of IEL remain unknown. Some evidence for cytolytic activity directed against epithelial cells by human $CD8^+$ IEL has been presented, and their possible contribution to local oral tolerance is also of interest (Brandtzaeg, 1996).

1.1.2.2 Lamina propria lymphocytes (LPL)

The lymphocytes in lamina propria are at least in part derived from the blood. They enter the mucosa by extravasating from venules within the lamina propria. The normal intestinal lamina propria contains macrophages, dendritic cells, mast cells, plasma cells, lymphocytes and eosinophils (Morson & Dawson, 1979; Selby *et al.*, 1983; Cerf-Bensussan *et al.*, 1983; Hume *et al.*, 1984; Pavli *et al.*, 1990). In mice, the lamina propria contains 22% Ig-containing (cIg) cells, 18% B cells, 41% T cells, 10% granulocytes (Tseng, 1982) and relatively large numbers of macrophages (Hume *et al.*, 1984; Witmer & Steinman, 1984). The cIg cells are composed of plasma cells and plasmablasts, most of

which produce antibodies of the IgA isotype. B lymphoblasts originating in Peyer's patches are precursors of the IgA-producing cells (Pierce & Gowans, 1975; Husband & Gowans, 1978; Kagnoff, 1987). Isolated eosinophilic leukocytes are relatively common in the lamina propria (Perera *et al.*, 1975).

Lamina propria T cells appear to originate from lymphocytes in the organized lymphoid follicles of the mucosa. Here they first encounter antigen, thereupon enter the circulation, and home back to the mucosa (Zeitz *et al.*, 1991). The phenotypic analysis of lymphocytes obtained from Ly5 congenic parabionts reveals that peripheral T cells migrate rapidly to the Peyer's patches and lamina propria (Poussier *et al.*, 1992). Thy-1.2$^+$ cells are numerous in the mouse intestinal lamina propria (Ermak & Owen, 1986). CD3$^+$ T cells represent about 40% of the LPL from the small or the large intestine of normal mice and of these, 85% express the α/β TCR and 15% express the $\gamma\delta$ TCR (Boll & Reimann, 1995). Similarly, in humans more than 95% of intestinal lamina propria T cells bear the $\alpha\beta$ TCR (Ullrich *et al.*, 1990). Most T lymphocytes in the human lamina propria express CD4, the phenotype usually associated with helper/inducer T cells (Cerf-Bensussan *et al.*, 1983). In mice, CD4$^+$ T cells constitute 40% of the lamina propria T cells in the small intestine (Harriman *et al.*, 1992; Boll & Reimann, 1995).

There is a population of double negative CD4$^-$ CD8$^-$ cells which express the Thy-1 molecule in the LP of the mouse small intestine. Some of these cells express CD3 but the majority are CD3$^-$ (Harriman *et al.*, 1992). Boll & Reimann (1995) found that double negative (DN) CD4$^-$CD8$^-$ T cells constitute about 15% to 20% of all CD3$^+$ T cells from the lamina propria in the small and the large intestine in euthymic and athymic mice. T cells with this phenotype are mostly $\gamma\delta$ TCR$^+$ T cells, the remainder of the $\gamma\delta$ T-cells

having a $\gamma\delta$ TCR$^+$ CD8 $\alpha^+\beta^-$ phenotype (Boll & Reimann, 1995). The remaining CD4$^-$, CD8$^-$, CD3$^-$, Thy1$^+$ cells are presumed to be natural killer (NK) cells.

Only minority of lamina propria T cells express the CD45RA antigen (Zeitz *et al.*, 1991). The vast majority of T lymphocytes in the normal human lamina propria are likely to have gone through prior antigen-driven activation and differentiation and hence, are effector memory lymphocytes (Harriman *et al.* 1992; James & Zeitz, 1994) that express the CD45RO isoform (Zeitz *et al.*, 1991; De Maria *et al.*, 1993). The majority of CD4$^+$ and CD8$^+$ LPL in human large bowel express MHC class II and/or CD25 molecules, suggesting that they are activated constitutively (Deusch *et al.*, 1991). In contrast, in jejunal mucosa there are few or no CD25$^+$ cells that can be detected by immunohistochemistry (Halstensen & Brandtzaeg, 1993; Halstensen *et al.*, 1993).

Studies of the immunoregulatory potential of lamina propria T cells *in vitro* indicate that such cells have a high potential for helper activity. This is consistent with their phenotypic characteristics and their potential for lymphokine gene expression (James & Zeitz, 1994).

1.1.2.3 Peyer's patches (PP)

Peyer's patches are aggregations of lymphoid follicles which generally have an anti-mesenteric distribution. However, in humans they are situated occasionally at random around circumference of the gut wall (Cornes, 1965a). They are present throughout the small bowel, particularly in the ileum (Shorter & Tomasi, 1982).

In the human foetus, PP are developed by 16 weeks gestation, when distinct follicles of B cells with surrounding T cells are present in the ileum (Spencer *et al.*, 1986c). By 19 weeks of gestation, primary B-cell follicles are detected and T cells occupy the inter-follicular zones (MacDonald & Spencer, 1994a). In a study by Cornes, the average number

of PP was found to range from 45 at 24 weeks gestation to 98 in term infants (Cornes, 1965a). After birth, the number and size of PP increases for at least the first 10 years and reaches about 240 at puberty. The number of follicles in each patch varies from as few as 5 to several hundreds. With increasing age, there is a loss of follicles from the Peyer's patches (Cornes, 1965b).

In mice (Ferguson & Parrott, 1972) and rats (Mayrhofer *et al.*, 1983), Peyer's patches can be detected in foetal intestine at the 18th day of gestation. At this stage, they contain mostly MHC class II positive dendritic cells, with a few lymphocytes (Mayrhofer *et al.*, 1983). Germinal centers start to appear in mice at 4 weeks after birth (Ferguson & Parrott, 1972).

The increase in numbers of Peyer's patches in humans after birth probably reflects the initial response of the host immune system to the wide variety of environmental antigens that pass through the gastrointestinal tract (Keren, 1992). Experiments in animals have suggested that both thymus-derived lymphocytes and luminal antigens are necessary for normal development of PP (Crabbé *et al.*, 1970; Joel *et al.*, 1971; Ferguson & Parrott, 1972).

The Peyer's patches in rats (Mayrhofer *et al.*, 1983), mice (Joel *et al.*, 1971) and humans (Cornes, 1965b) are considered to be secondary lymphoid organs whose development is completed postnatally, whereas in sheep they are well developed at the end of gestation (Reynolds & Morris, 1983). Furthermore, B cell proliferation in ileal PP follicles of sheep is antigen independent (Reynolds & Morris, 1984; Griebel *et al.*, 1991). These ileal PP involute at a young age (Reynolds & Morris, 1983). This and other evidence suggests that the ileal PP of sheep may be primary sites of B cell development, and that they are essential for the normal development of the B cell pool in this species (Reynolds *et al.*, 1991).

The structure and the cellular composition of human PP have been studied by several groups of workers (Owen & Jones, 1974; Spencer *et al.*, 1986a; Spencer *et al.* 1986c, Bjerke *et al.,* 1988; Brandtzaeg & Bjerke, 1990; Farstad *et al.*, 1993; Farstad *et al.*, 1994; Farstad *et al.*, 1997). The most obvious component of the PP is the follicle, consisting of a germinal center (GC) and a corona. The corona is composed mainly of resting B cells. Germinal centers contain activated B lymphocytes and in PP, are sites of switching to the IgA isotype. Plasma cells are rare in germinal centers (Kagnoff, 1987) but within PP, germinal centers are considered to be the site of generation of precursors of the IgA-secreting plasma cells (Butcher *et al.*, 1982) and memory cells (Coico *et al.*, 1983). Peyer's patches are an enriched source of precursors which can give rise to the IgA-secreting plasma cells that populate the various mucosal tissues (Craig & Cebra, 1971). Recently, it has been demonstrated in humans also that the plasma cells in the lamina propria originate from germinal centers of Peyer's patches (Spencer *et al.*, 1997; Dunn-Walters & Spencer, 1997).

As with GC in other sites, those in PP contain follicular dendritic cells and a specialized subset of $CD4^+$ T cells that may be involved in regulation of isotype switching (Klaus *et al.*, 1980; Butcher *et al.*, 1982; Kiyono *et al.*, 1984; Kosco *et al.*, 1986; Bowen *et al.*, 1991). Treatment of young Balb/c mice with anti-L3T4 mAb resulted in a selective depletion of $CD4^+$ T cells in PP. The depletion of $CD4^+$ T cells was accompanied by reduction in the numbers of mature IgA plasma cells present in the LP of the gut and reduced overall size of the PP, including the GC (Mega *et al.*, 1991).

Overlying the follicle is the dome region, consisting of B cells, T helper cells, macrophages, MHC class II-positive accessory cells (Ermak & Owen, 1986), occasional plasma cells and the specialized follicle-associated epithelium (FAE). MHC class II-positive cells in the subepithelial dome region that extend into the FAE appear to be DC (Mayrhofer *et al.*, 1983; Wilders *et al.,* 1983). In mouse PP, the phenotype of DC in the

follicle dome is different from that of DC in the interfollicular T cell region (Kelsall & Strober, 1996; Ruedl *et al.*, 1996). It can be argued that there are two different populations of DCs in the PP or, alternatively, that the DC in sub-epithelial dome are less differentiated than those in interfollicular region (Kelsall & Strober, 1996). The presence of DC in the dome, immediately underlying the M cells, suggests that in Peyer's patches most antigen uptake takes place in the dome region (MacDonald & Spencer, 1994b). It is suggested that DC migrate from the dome region to the T-dependent inter-follicular regions (Wilders *et al.*, 1983; Kelsall & Strober, 1996), carrying with them processed antigens and undergoing phenotypic maturation.

The FAE lacks villi (Brandtzaeg & Bjerke, 1990) and goblet cells are quite rare in comparison with the epithelium covering adjacent villi (Owen & Jones, 1974). It contains specialized microfold (M) cells (Owen *et al.*, 1986; Brandtzaeg & Bjerke; 1990; Fujimura *et al.*, 1990) which have been shown in mice to transport macromolecules and infectious agents from the gut lumen into the PP (Owen, 1977; Wolf *et al.*, 1981; reviewed by Kraehenbuhl & Neutra, 1992). M cells are different from the adjacent columnar enterocytes in that they lack fully developed microvilli and in some species microvilli are replaced with small folds. The M cells also contain numerous vesicles, and are pinocytotic (Fig 2). Furthermore, M cells form cytoplasmic bridges that separate the underlying lymphocytes from the intestinal lumen (Owen & Jones, 1974). Leukocytes present in the pockets of human M cells contain approximately equal proportions of B lymphocytes and T lymphocytes (mainly $CD45RO^{+}$), with occasional plasma blasts or plasma cells, and a few macrophages (Farstad *et al.*, 1994). FAE covering human PP expresses MHC class II (HLA-DR) determinants (Bjerke & Brandtzaeg, 1983; Bjerke *et al.*, 1988; Spencer *et al.*, 1986b; Bjerke & Brandtzaeg, 1988; Brandtzaeg & Bjerke, 1990). The presence of class II MHC molecules on intestinal epithelium has been suggested to functional by binding processed peptides (Mayrhofer & Spargo, 1989; Mayrhofer, 1994; Mayer *et al.*, 1997). In

humans, the epithelial cells may, therefore, be involved directly in presentation of processed antigen to the numerous intraepithelial T cells (Bjerke & Brandtzaeg, 1988). However, FAE in the rat gut does not express MHC class II molecules (Mayrhofer *et al.*, 1983) and antigen presentation by FAE can not be an essential function in all species.

The distribution of IEL in the FAE differs from that in the villus epithelium. IEL are more numerous in FAE than in villus epithelium. In FAE, lymphocytes are often clustered into groups and they are situated at all levels of the epithelium. In contrast, the IEL in the villi are scattered along the epithelium and most of them are situated close to the basement membrane (Rowinski *et al.*, 1984; Bjerke *et al.*, 1988). The ratio of $CD4^+$ to $CD8^+$ T cells is significantly higher in the FAE than in the villous epithelium (Bjerke *et al.*, 1988). This difference might reflect differences in capacity for positive and negative regulation of immune responses at the two sites (Bjerke *et al.*, 1988). Dome epithelium contains also scattered B cells. They are grouped sometimes in clusters of several cells (Ermak & Owen, 1986).

The interfollicular regions of PP contain T cells, interdigitating cells, macrophages (Witmer & Steinman, 1984) and high endothelial venules (HEV). PP are important sites of lymphocyte recirculation (Keren, 1992). It is often claimed that PP lack afferent lymphatics (Shorter & Tomasi, 1982) and that specific interactions between recirculating lymphocytes and high endothelial venules must, therefore, determine the lymphocyte subset composition of Peyer's patches (Rouse *et al.*, 1984; Nagura & Sumi, 1987; Westermann *et al.*, 1994). T-cells are present in the greatest density in the areas surrounding the high endothelial venules. However, afferent lymphatics enter the interfollicular areas of PP from the overlying patch-associated villi and their contribution of lymphocytes and dendritic cells to PP has not been assessed. Interleukin 2 (IL-2) receptor-

positive T cells are present in the interfollicular areas (MacDonald & Spencer, 1994b), presumably reflecting ongoing immune responses to lumenal antigens, even in normal PP.

1.1.2.4 Isolated lymphoid follicles (ILF)

Two other forms of lymphoid aggregations that have been described in the wall of the human small intestine are isolated lymphoid follicles (ILF), which lie within the mucosa and submucosal lymphocyte aggregations (SLA), which lie within the muscularis mucosa (Morson & Dawson, 1979). These are seen commonly on histologic examination, but they are not visible macroscopically (Shorter & Tomasi, 1982; price, 1985; Whitehead, 1990). The number of these lymphoid aggregations increases in the more distal parts of the small intestine (Whitehead, 1990).

Both ILF and SLA are accepted as normal components of the small intestinal mucosa (Price, 1985) but their functions are unknown. There is some indirect evidence that supports the hypotheses that ILF have an important role in the intestinal immune responses (Keren *et al.*, 1978; Heatley *et al.*, 1981; Hamilton *et al.*, 1981). ILF have been described briefly in both eutherian and marsupial mice (Poskitt *et al.*, 1984), in rats (Mayrhofer, 1984) and in rabbits (Keren *et al.*, 1978) where they are assumed to represent solitary PP follicles. The presence of M cells in the FAE overlying similar structures in guinea pigs (Rosner & Keren, 1984) supports this view.

Fig 2- Ultrastructure of enterocytes, M cells, and intraepithelial lymphocytes in follicle epithelium of mouse ileal Peyer's patch (From Ref. Owen, 1977).

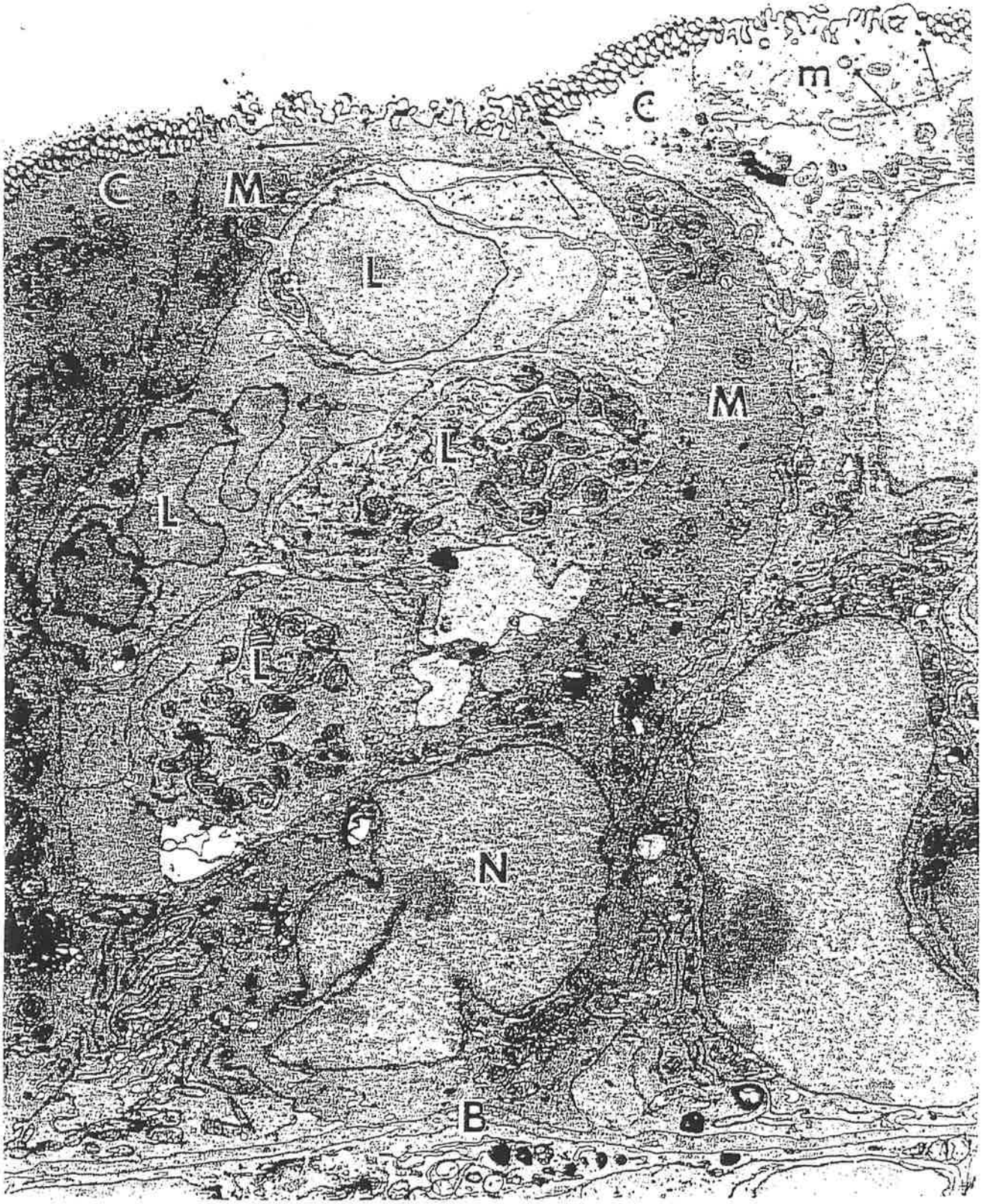

Epithelium over the dome of a lymphoid follicle from a mouse ileal Peyer's patch. An M cell (*M*) with an irregular nucleus (*N*) surrounded by Golgi apparatus and mitochondria, rests on the basal lamina (*B*), interdigitates with columnar cells (*C*) on each side, and is invaginated from the left by lymphoid cells (*L*). The M cell cytoplasm is attenuated at the luminal surface as it stretches above the group of lymphoid cells. Irregular surface projections cover the central M cell and a portion of another M cell (*m*) in the *upper right corner*. Horseradish peroxidase (HRP) reaction product coats the luminal surface of all cells and can also be seen filling vesicles (*arrows*) after 1 hr of exposure to HRP (× 9200).

1.1.3 The Effect of Lymphotoxin alpha, Lymphotoxin beta, Tumor Necrosis Factor alpha , Tumor Necrosis Factor and Lymphotoxin alpha in the Development of Lymphoid Organs

1.1.3.1 Abnormal development of peripheral lymphoid organs in lymphotoxin alpha (LT-α) deficient mice

Lymphotoxin (LT, also known as LT-α or TNF-β) is a soluble product of activated T-cells, B-cells, and monocytes (Androlewicz *et al.*, 1992; Browning *et al.*, 1993; Browning *et al.*, 1997). The biological effects of soluble LT and TNF-α are mediated by two receptors, designated TNF-R55 and TNF-R75. Both of these receptors have been demonstrated to be co-expresses on a variety of cell types and tissues (Brockhaus *et al.*, 1990; Loetscher *et al.*, 1990; Schall *et al.*, 1990). The TNF and TNFR families of molecules consist of the ligands TNF, lymphotoxins alpha and beta (LT-α, LT-β), nerve growth factor (NGF), Fas ligand (FasL), CD27 ligand, CD30 ligand, CD40 ligand, OX40 (CD134) ligand, and 4-1BB ligand and their receptors (Mayrhofer, 1997).

LT has been identified in two different molecular forms: a secreted form consisting of a homotrimer composed of LTα subunits, and a membrane-bound form composed of both LT-α and LT-β subunits (heterotrimer) (Browning *et al.*, 1995). The soluble form, like TNF-α, binds to TNF-R55 or TNF-R75 (Beutler & van Huffel, 1994; Gruss & Dower, 1995), whereas the cell surface form binds specifically to the novel LTβ receptor (LTβ-R) (Crowe *et al.*, 1994).

In addition to a role in inflammation and cytotoxicity, LT appears to have an essential function in the development of peripheral lymphoid organs (De Togni *et al.*,

1994). The importance of LT-α in the development/organization of peripheral lymphoid organs has been demonstrated in LT-$\alpha^{-/-}$ mice. These mice exhibit abnormal development of secondary lymphoid organs, including absence of normal lymph nodes and Peyer's patches, and disruption of normal splenic architecture (De Togni *et al.*, 1994; Banks *et al.*, 1995). In LT-$\alpha^{-/-}$ mice, the neutrophil, monocyte and platelet counts are normal and B lymphocytopoiesis appears normal. Moreover, the thymus has normal morphology and cellularity and development of T cells does not appear to be disturbed. Intraepithelial lymphocytes are present with apparently normal distribution in the small intestine (De Togni *et al.*, 1994; Banks *et al.*, 1995). Nevertheless, lymphotoxin may activate extrathymic T-cells in the liver and it can also induce thymic involution (Kusumi *et al.*, 1992). The abilities of LT-$\alpha^{-/-}$ lymphocytes to enter secondary lymphoid organs is intact (Banks *et al.*, 1995) but the humoral immune responses are markedly deficient (Banks *et al.*, 1995). This may be related to failure in organogenesis of Peyer's patches and lymph nodes and to the disruption of the lymphoid follicles in the spleens of these mice.

Mice in which the genes encoding the TNF-R55 are disrupted have rudimentary Peyer's patches and both lymph nodes and spleen are present in these mutants (Neumann *et al.*, 1996; Le Hir *et al.*, 1996; Matsumoto *et al.*, 1997). However, in all of these organs organization of follicular structures is disorganized and there appears to be a lack of follicular dendritic cells (FDC). These defects are not observed in mice deficient for TNF-R75 (Erickson *et al.*, 1994). In contrast, the formation of peripheral lymph nodes and Peyer's patches are both disrupted in mice born of mothers treated during pregnancy with soluble LTβ-R-immunoglobulin (Rennert *et al.*, 1996). These results suggest that cell surface LT-αβ heterotrimers, acting via the LTβ-R, mediate most aspects of organogenesis that are defective in the LTα knockout mice. The existence of this unique receptor specific for surface LT was reported by Crowe *et al.* (1994).

1.1.3.2 Abnormal development of secondary lymphoid tissues in lymphotoxin beta (LT-β) deficient mice

Most of the surface LT-β monomers are found in complexes with LT-α. LT-β has not been detected in a secreted form, nor as a homotrimer (Browning *et al.*, 1993; Browning *et al.*, 1995). Mice deficient in LT-β reveal several defects in organogenesis of the lymphoid system that are similar to those of LT alpha$^{-/-}$ mice. However, most LT-β$^{-/-}$ mice contain mesenteric and cervical LN (Alimzhanov *et al.*, 1997), although they lack Peyer's patches, other peripheral lymph nodes, splenic germinal centers and follicular dendritic cells (Koni *et al.*, 1997).

As mentioned earlier, blocking of the LTβ-R by gestational treatment with LTβ-R-immunoglobulin (Ig) prevents the development of lymph nodes and Peyer's patches but it does not affect the development of the spleen or the thymus (Rennert *et al.*, 1996).

1.1.3.3 Role of TNF in development of peripheral lymphoid organs

Tumor necrosis factor alpha (TNF-α) is produced by activated macrophages, monocytes, T-cells, B-cells and NK cells (Vassalli, 1992). This cytokine may be involved in the regulation of infectious, inflammatory and autoimmune conditions (Vassalli, 1992).

Two distinct membrane receptors for TNF-α of molecular weight 55-kDa and 75-kDa have been identified (Lewis *et al.*, 1991; Smith *et al.*, 1994). The biological activities of TNF-α (and TNF-β) is apparently mediated via the TNF-R55 and -R75 receptors (Aggarwal *et al.*, 1985).

The role of TNF-α in organogenesis of lymphoid organs has been studied in TNF-α-deficient mice. Studies in these mutant mice revealed that TNF-α does not have a critical role for lymphoid organogenesis (Pasparakis *et al.*, 1996). In TNFα$^{-/-}$ mice, the cellular content and the structural organization of peripheral lymphoid organs (spleen and lymph nodes) and thymus was similar to that observed in wild type mice (Pasparakis *et al.*, 1997). However, although the PP were present in TNFα$^{-/-}$ mice (Pasparakis *et al.*, 1996), they were reduced both in size and number (Pasparakis *et al.*, 1997). The mice appear to lack follicular dendritic cells (FDC) and they fail to form either splenic primary B cell follicles or germinal centres (Pasparikis *et al.*, 1996). Moreover, complete lack of organized B lymphocyte follicles and FDC networks in Peyer's patches indicate that TNF-α has an essential role in directing the formation of FDC networks and normal B-cell follicles (Pasparakis *et al.*, 1997).

1.1.3.4 Role of TNF-α and LT-α in lymphoid organogenesis

To investigate the roles of TNF-α and LT-α in the development and function of the immune system, TNF-α/LT-α double-deficient mice have been used (Amiot *et al.*, 1997; Korner *et al.*, 1997). The combined genetic inactivation of TNF and LT-α leads to distinct morphological and functional defects of the peripheral immune system. Double-deficient mice lack both LN and PP (Eugster *et al.*, 1996; Korner *et al.*, 1997). The only peripheral lymphoid organ present in the mutant mice is the spleen, which has normal weight, size and cellularity but shows an altered microarchitecture (Eugster *et al.*, 1996; Korner *et al.*, 1997). By using mice that are deficient in both TNF-α and LT-α, it has been shown that the TNF-α and/or LT-α are essential for development of a normal splenic microarchitecture as well as for an antibody response against sheep red blood cells (SRBC) (Le Hir *et al.*, 1996). Importantly, TNFα and/or LTα are not necessary for

normal thymus development (Eugster *et al.*, 1996). The immunodeficiency due to TNF-α/LT-α deletion can be corrected by the transfer of wild type bone marrow cells, suggesting that the TNF-α and LT-α-producing cells that are important in splenic function are bone marrow derived (Muller *et al.*, 1996). As might be expected from the discussion of LT-α-/-, LT-β-/-, TNF-α-/- and TNF-α/LT-α double-deficient mice, membrane bound LT is vital in the organogenesis of secondary lymphoid organs, including PP (Mayrhofer, 1997).

The respective roles of TNF-α and LT-α/β in the development of peripheral lymphoid organs also has been studied by using either LTβ-R-Ig or a monoclonal antibody against murine LT-β and by the use of TNF-R55-Ig. Although blocking of the LTβ-R by gestational treatment with LTβ-R-immunoglobulin (Ig) prevents the development of lymph nodes and Peyer's patches (Rennert *et al.*, 1996), prolonged treatment of normal adult mice with LTβR-Ig does not effect the microarchitecture of lymph nodes and Peyer's patches (Mackay *et al.*, 1997). Similarly, inhibition of the TNF/LT-α pathway in adult mice with TNF-R55-Ig did not affect the microarchitecture of lymph nodes and Peyer's patches (Mackay *et al.*, 1997). The effect of deletion of TNF/LT, TNF-R55 and LTβR on secondary lymphoid organs have been summarized in Table 1.

Table 1. Phenotypic comparison between TNF, LT, TNF/LT and TNF-R55 knockout and normal mice treated with TNF-R55-Ig or LTβR-Ig (modified from Mackay *et al.*, 1997).

	Splenic T/B cells compartments	Ab responses to TD antigens	Lymph nodes PP
Knockout mice:			
TNF-α-/-	Disrupted	Impaired	Normal
TNF-R55-/-	Disrupted	Impaired	Present
LT-α-/-	Disrupted	Impaired	Absent
LTβ-/-	Disrupted	Impaired	Absent, except MLN and cervical
TNF/LT-/-	Disrupted	Impaired	Absent
Treatment with soluble R-Ig			
LTβR-Ig			
During development	Disrupted	ND	Absent, except MLN, lumbar, cervical and sacral
In adult mice	Disrupted	Impaired	Normal
Human TNF-R55-Ig			
During development	Disrupted	ND	Normal
In adult mice	Normal	Normal	Normal

TD: Thymus dependent
MLN: Mesenteric lymph node
LTβR: LT beta receptor
ND: not described
TNFR: TNF receptor

1.1.4 Molecular and Cellular Events of T cell Development

I.1.4.1 Early progenitors of T cells in the thymus

It is well known that T cell precursors migrate from the bone marrow to the thymus microenvironment where they expand and differentiate into mature T cells. The murine embryonic thymus is first colonized by hematopoietic cells on the eleventh day of gestation (Moore & Owen, 1967). The first cells that appear in the embryonic thymus have been reported to have the phenotype $CD3^-$, $CD4^-$, $CD8^-$ (Mathieson *et al.*, 1981) but

more recent evidence indicates that very early thymocytes express low levels of CD4 (Wu *et al.*, 1991a; Wu *et al.*, 1991b). Day 14-15 fetal thymocytes are predominantly $CD4^-$ $CD8^-$ double negative. Less than 1% of these cells are $CD3^-$ (Zúñiga-Pflücker *et al.*, 1993). Although $\gamma\delta$ TCR^+ DN cells are present in the thymus at day 14-15 (Havran & Allison, 1988), the vast majority of double-negative cells at that time have not yet begun to rearrange genes that encode the α and β chains of the TCR (Zúñiga-Pflücker *et al.*, 1993). At this stage, only a very small subset of $CD4^-CD8^-$ thymocytes (~ 5%) express the α/β TCR molecule (Held *et al.*, 1990), although the $\alpha\beta$ TCR was not detected by Havran & Allison (1988) until day-17 of gestation.

The earliest intrathytmic precursors found within the adult mouse thymus have been defined (Fowlkes *et al.*, 1985) as $CD4^-$ $CD8^-$ thymocytes which express low levels of CD5 (Ly1). Double negative $CD4^-$ $CD8^-$cells comprise only 3-5% of thymocytes in adult mice (many of them are dividing). They have the capacity to give rise to the other subsets in irradiated Ly5 congenic hosts (Fowlkes *et al.*, 1985) after they are injected intrathymically (Petrie *et al.*, 1990) or when they are used to re-constitute foetal thymic organ cultures (FTOC) (Takahama *et al.*, 1994). Anatomically, immature thymocyte precursors first colonize the subcapsular region of the outer cortex of the thymus. As thymocytes mature, they migrate toward the medulla as illustrated in Figure 3 (Boyd & Hugo, 1991). It has been shown that large lymphocytes in the outer thymic cortex are labelled by a pulse of tritiated thymidine and that small- and medium-sized lymphocytes are labelled throughout the cortex and medulla 2-4 days later (Weissman, 1973).

Immature thymocytes are cortisone sensitive (Hugo *et al.*, 1990). Injection of mice with cortisone results in pyknosis of cortical thymocytes within 24 hours, with only minimal effect on medullary thymocytes (Weissman, 1973). Moreover, it has been shown that by 36 hours after cortisone treatment, the immature thymocytes are depleted and the

thymus contains a large number of single positive cells that express either CD4 or CD8 (Godfrey *et al.*, 1992). This confirmed earlier work which showed that cortisone resistant thymocytes (CRT) are mainly single positive (Shortman *et al.*, 1988).

Fig 3-Simplified scheme of the thymic distribution of lymphoid and epithelial cell populations (From Ref. Ritter & Boyd, 1993).

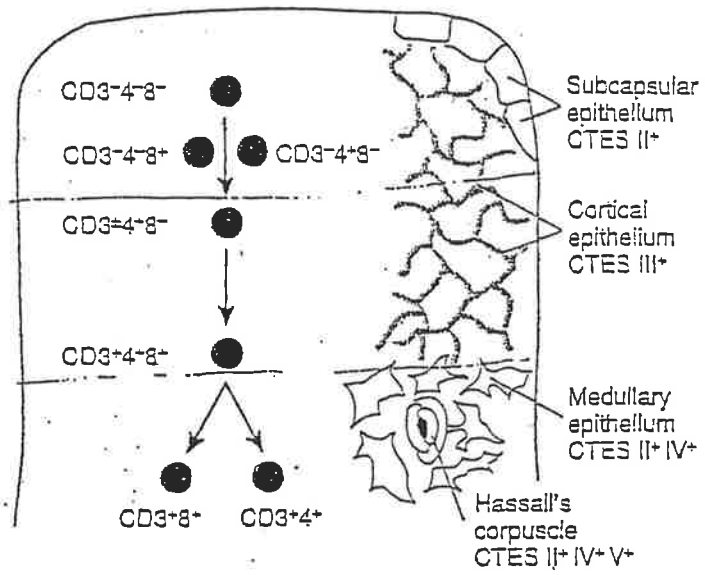

CTES: Clusters of thymic epithelium staining

CTES I-VI: mAbs stain types 1-6 epithelium (Six subsets of thymic epithelium have been identified on the basis of differing morphology and cytoplasmic electron lucency).

Thy-1 is a major cell surface molecule expressed on murine thymocytes and peripheral T cells. However, not all mouse thymocytes are Thy-1$^+$ (Scollay *et al.*, 1988). This molecule is expressed very early in T cell development (Palacios *et al.*, 1987) and a subset of CD4$^-$ CD8$^-$ cells bear the antigen Thy-1 (Crispe *et al.*, 1987). At days 15 and 16 of gestation, 80% of the fetal thymocytes are Thy-1$^+$, whereas at later times, > 97% are positive for Thy-1 (Mathieson *et al.*, 1981). Thy-1 is also expressed by thymic epithelial cells (Tucek & Boyd, 1990). The *in vivo* function of Thy-1 is unknown. *In vitro*, anti-Thy-1 mAbs induce proliferation and lymphokine secretion in both fetal thymocytes (Tentori *et al.*, 1988a) and peripheral T cells (Kroczek *et al.*, 1986). Thy-1 may also be involved in potentially important interactions between developing thymocytes and the epithelial stroma of the thymus. It has been shown that Thy-1 is involved in the adhesion of mouse thymocytes to thymic epithelial cells through a specific interaction with a heterophilic ligand expressed on the epithelial cell surface (He *et al.*, 1991). Thy-1-mediated adhesion of thymocytes to thymic epithelial cells can be blocked by sulfated glycans (Hueber *et al.*, 1992). It seems that in addition to the role of Thy-1 in T cell triggering, it might play a role during the early T cell maturation by promoting thymocyte adhesion to thymic stroma.

One of the differentiation antigens that is potentially important in T cell development is thymic shared Ag-1 (TSA-1). TSA-1 is detected by mAb MTS 35, first reported by Godfrey *et al.*(1992) as a marker of immature thymocytes. TSA-1 has high expression on TN (CD3$^-$ CD4$^-$ CD8$^-$), and on DP (CD4$^+$ CD8$^+$) thymocytes but it is not detectable on mature CD4$^+$ CD8$^-$ or CD4$^-$ CD8$^+$ thymocytes (Godfrey *et al.*, 1992). TSA-1 is not expressed by peripheral T cells, but it is present on virtually all peripheral B cells and on precursors of B lineage cells in the bone marrow (Godfrey *et al.*, 1992). It is also

present on thymic dendritic cells (Vremec *et al.*, 1992) and on thymic epithelium (Godfrey *et al.*, 1992).

TSA-1 is a functionally important molecule in early thymocyte differentiation (Randle *et al.*, 1993). In FTOC, anti-TSA-1 mAb inhibits the development of DP thymocytes and TCR$\alpha\beta^+$ mature thymocytes (Randle *et al.*, 1993). It was suggested originally that the effect of anti-TSA-1 was directly on the developing thymocytes. However, more recent studies (Boyd, 1998) indicate that the effect of the antibody may be more complex and involve the interaction between the lymphoid and stromal components of the developing thymus. Nevertheless, TSA-1 may be involved in negative selection in thymus. Negative selection of thymocytes is generally considered to be caused by TCR-mediated apoptosis (von Boehmer, 1992). In experiments *in vitro*, anti-TSA-1 blocks anti-CD3-induced death of T cell hybridomas. *In vivo*, anti TSA-1 together with anti-CD3ε or anti-TCR-β blocked almost completely TCR/CD3-mediated apoptosis of thymocytes (Noda *et al.*, 1996). TSA-1 may also play a role during positive selection and in the transition of CD4$^+$ CD8$^+$ thymocytes to the mature CD4$^+$ CD8$^-$ and CD4$^-$ CD8$^+$ subsets (MacNeil *et al.*, 1993). Moreover, in addition to its role in T cell differentiation, TSA-1 may be involved in a regulatory role in the TCR signalling pathway of activated T cells (Saitoh *et al.* 1995). Although freshly isolated T cells do not express TSA-1 on the cell surface, stimulation of T cells with Con A *in vitro* induces TSA-1 expression on T cells (Kosugi *et al.*, 1994). However, the role of TSA-1 in T cell activation remains obscure.

Stem cell antigens 1 and 2 are so named because of their expression by mouse bone marrow stem cells (Spangrude *et al.*, 1988a; Spangrude *et al.*, 1989). They are expressed by two bone marrow populations, both of which can repopulate the thymus after transfer intravenously into irradiated mice (Spangrude *et al.*, 1989). Stem cell

antigen-2 (Sca-2) is a member of the Ly-6 family (Classon & Coverdale, 1994). The nucleotide sequence of Sca-2 cDNA is identical to the TSA-1 cDNA in the GenBank data base (Kosugi *et al.*, 1994). As might be expected from the discussion of TSA-1, Sca-2 is a differentiation Ag expressed on early thymic precursor cells (Spangrude, *et al.*, 1988b). Sca-2 expression is limited to the thymic cortex, where it is associated with large cycling thymic blast cells (Spangrude *et al.*, 1988b). This marker is observed on a phenotypically immature subpopulation of $CD4^-$ $CD8^+$ thymocytes (Spangrude *et al.*, 1988b). Sca-2 expression is not observed on peripheral T lymphocytes, but seems limited to sub-populations of B lymphocytes in peripheral lymphoid tissues (Spangrude *et al.*, 1988b). As mentioned above, a population of bone marrow stem cells expresses Sca-2 and they develop into T lymphocytes if they are transferred into thymuses of irradiated mice (Antica *et al.*, 1994). The functions of the Sca-2 molecule and the TSA-1 antigen in the process of thymocyte development are similar (Noda *et al.*, 1996), supporting the identity of Sca-2 and TSA-1.

Sca-1 is expressed by thymic medullary thymocytes and by some subcapsular blast cells ($CD4^-$ $CD8^-$), as well as by the thymic blood vessels and the thymic capsule (Spangrude *et al.*, 1988b). Most of the Sca-1 antigen expressed in the thymus is associated with connective tissue rather than with the cell surfaces of thymocytes (Spangrude *et al.*, 1988b). The distribution of Sca-1 antigen has similarities with another thymic antigen, the Pgp-1 (CD44) molecule (Spangrude *et al.*, 1988b). As with Sca-1, Pgp-1 is expressed throughout the thymic medulla and stains cortical blood vessels and the thymic capsule weakly (Spangrude *et al.*, 1988b). Thymic progenitors of T lymphocytes (Hyman *et al.*, 1986) and bone marrow stem cells (Trowbridge *et al.*, 1982) are also Pgp-1^+. The earliest thymic precursors are thought to be $CD44^+CD25^-TN$. The next step in the developmental sequence is $CD44^+CD25^+TN$, which then differentiate in to the $CD44^-CD25^+TN$ subset (Godfrey & Zlotnik, 1993). A $CD44^-CD25^-TN$ stage occurs

before the expression of CD4 and CD8 molecules (Pearse *et al* , 1989). Both Sca-1 and Pgp-1 molecules are expressed by the majority of lymph node lymphocytes (Spangrude *et al.*, 1988b). Upregulation of surface Pgp-1 is found to be a stable differentiation event occurring concomitantly with primary antigenic stimulation. Hence, high expression of Pgp-1 among peripheral T cells is an important differentiation marker for identifying antigen-stimulated memory-T cells (Budd *et al.*, 1987).

Most of the $CD3^- 4^- 8^-$ subset of thymocytes in adult mice express high levels of the heat stable antigen (HSAhi) recognized by mAb B2A2 (Scollay *et al.*, 1984; Wilson *et al.*, 1988). In the day-14 embryonic thymus, the majority of $CD4^- CD8^-$ cells are found to be HSA^+ (Pearse *et al.*, 1989). This antigen is, therefore, expressed during the initial stages of T cell development (Scollay *et al.*, 1984; Crispe & Bevan, 1987; Crispe *et al.*, 1987; Nikolic-Zugic, 1991). HSA is also found on nearly all bone marrow cells (91.8%) (Miller *et al.*, 1985). Moreover, most DP thymocytes are HSA^+ (Crispe & Bevan, 1987), while maturation of the DP thymocytes into $CD4^+$ or $CD8^+$ single positive (SP) thymocytes is accompanied by loss of HSA expression (Takei *et al.*, 1981; Pearse *et al.*, 1989). Recent thymic emigrants and mature peripheral T cells do not express HSA (Takei *et al.*, 1981). In HSA transgenic mice, where HSA is expressed highly on all subsets of thymocytes, a marked reduction is observed in the numbers of double positive and single positive thymocytes. Therefore, downregulation of HSA expression at the double positive stage is a critical event in thymocyte development (Hough *et al.*, 1994). HSA, together with other markers including CD4 and CD8, are downregulated when thymocytes undergo spontaneous apoptosis in tissue culture (Kishimoto *et al.*, 1995).

A small subset of thymocytes, constituting approximately 1% of the total in adult mice, has the phenotype $CD4^+ CD8^- CD3^-$ (see above). These cells, which are mainly blasts and situated in the outer cortex, are cortisone-sensitive. They appear to

precede the $CD4^-$ $CD8^-$ $CD3^-$ subset but are earlier than $CD4^+$ $CD8^+$ $CD3^-$ subset (Hugo *et al.*, 1990). It is suggested that the $CD4^+$ $CD8^-$ $CD3^-$ subset represents a transient intermediate between the $CD4^-$ $CD8^-$ $CD3^-$ and the $CD4^+$ $CD8^+$ cells (Hugo *et al.*, 1990). Moreover, a thymocyte subset representing the earliest T precursor cells in the adult mouse thymus is reported by Wu *et al.* (1991a). This sub-population has been shown to be similar in surface antigenic phenotype to bone marrow haematopoietic stem cells. The thymic subset expresses Sca-2 and moderate levels of CD4 and many of the cells are in cell-cycle (Wu *et al.*, 1991a). These authors believe that this subset is less mature than the established $CD3^-$ $CD4^-$ 8^- precursors, both in reconstitution behaviour and in TCR gene-rearrangement status (Wu *et al.*, 1991a). When this population is transferred intravenously into lethally irradiated mice, it displays the capacity to develop into both B and T lymphoid cells but does not appear to possess any myeloid or erythroid precursor potential. These observations suggest that the Sca-2^+ $CD4^+$ cells are lymphoid-committed stem cells (Wu *et al.*, 1991b). Interestingly, the $CD4^+$ precursors can also generate thymic dendritic cells (Ardavin *et al.*, 1993). Although the CD4 molecule is usually considered a marker of more mature T cells, it also expressed by a proportion of mouse bone marrow cells (Wineman *et al.*, 1992; Antica *et al.*, 1994).

Another subpopulation of immature thymocytes has been reported to have the surface antigen phenotype $CD3^-$ 4^- 8^+. Most of these cells express high levels of HSA and they are cortisone sensitive and rapidly cycling *in situ* (MacDonald *et al.*, 1988; Shortman *et al.*, 1988). Similarly, Boyer *et al* (1989) have reported that a significant fraction of $CD4^-$ $CD8^+$ thymocytes are unresponsive to the phorbol ester and calcium ionophore and that they are dividing cells. It is suggested that $CD3^-4^-8^+$ thymocytes represent a transitional stage of thymus differentiation between the $CD4^-8^-$ and $CD4^+8^+$ compartments (MacDonald *et al.*, 1988; Boyer *et al.*, 1989).

1.1.4.2 Role of IL-2 and IL-7 in T cell development in the thymus

Immature T cells express various differentiation antigens in the process of intrathytmic development (Fowlkes & Pardoll, 1989). A substantial subpopulation of $CD3^- 4^- 8^-$ cells in the fetal and adult thymus expresses CD25, the interleukin-2 receptor (IL-2R) (Ceredig *et al.*, 1985; Raulet, 1985; Wilson *et al.*, 1994a). This marker is associated typically with T cell activation by antigen (Hemler *et al.*, 1984) or mitogen (Cantrell & Smith, 1983). The earliest thymocytes that enter into the thymus are $CD4^{lo}$, $CD8^-$, $CD3^-$, $CD25^-$ (Fowlkes & Pardoll, 1989) and the most actively proliferating subpopulations of DN thymocytes are $CD25^-$ (pearse *et al.*, 1989). The majority of 14-15-day-old embryonic thymocytes are $CD4^-$, $CD8^-$, $CD3^-$, $CD25^+$, whereas only about 5% of adult thymocytes express CD25 (von Boehmer *et al.*, 1985). Prior to the transition from triple negative to the double positive ($CD4^+$ $CD8^+$) stage, thymocytes downregulate CD25. Double positive thymocytes do not express IL-2R (Fowlkes & Pardoll, 1989). It has been shown that a large amount of IL-2 mRNA is present in the fetal thymus at day 14.5 of gestation and that this decreases by day 15 and 16 of gestation. IL-2 production is also present in the day 15 fetal thymus in scid mice, indicating that this response is likely to be TCR^- independent (Yang-Snyder & Rothenberg, 1993). The role of IL-2 during T-cell differentiation remains controversial. The IL-2/IL-2R interaction may play an important role in growth and/or maturation of immature thymocytes, as shown that the treatment of FTOC with anti-CD25 mAb in *in vitro* (Jenkinson *et al.*, 1987). Administration of anti-CD25 mAb *in vivo* (Tentori *et al.*, 1988b) also inhibited the development of mature T cells in murine fetal thymus. Moreover, the growth of activated immature thymocytes from either fetal or adult mice is inhibited by a monoclonal antibody (PC61) against mouse CD25 (Palacios & von Boehmer, 1986). In addition, $CD25^+$ DN thymocytes have a greater potential to differentiate into phenotypically mature

T lymphocytes after intrathymic injection than do $CD25^-$ thymocytes (Shimonkevitz *et al.*, 1987).

The expression of CD25 by only the $CD4^-$ $CD8^-$ $CD3^-$ (triple negative, TN) thymocytes further suggested the importance of this pathway in T-cell development (Rothenberg, 1992). The spontaneous proliferation of TN thymocytes, which can be blocked by anti-CD25 mAb, is evidence for a role of IL-2 and IL-2R in regulating cell growth at this early ontogenic stage (Toribio *et al.*, 1989). However, CD25 expression is also upregulated on thymocytes undergoing spontaneous apoptosis in tissue culture (Kishimoto *et al.*, 1995). IL-2 can lead T cell death following activation, suggesting that it may also have a negative regulatory role in maintaining the balance between the expansion and deletion of lymphocyte clones in response to antigenic stimuli (Lenardo, 1991; Critchfield *et al.*, 1994).

On the other hand, disruption of the IL-2 gene has no major effect on thymocyte subset composition in the resulting IL-$2^{-/-}$ mice (Schorle *et al.*, 1991). Both immature and mature thymocyte subsets were present at normal levels in animals homozygous for the inactivated IL-2 gene (Schorle *et al.*, 1991). Moreover, immune responses were relatively normal in the IL-$2^{-/-}$ mice (Kundig *et al.*, 1993). Mice with disruption of the gene encoding CD25 (IL-2R$\alpha^{-/-}$) also have phenotypically normal development of thymocytes (Willerford *et al.*, 1995). Furthermore, thymocyte subsets in IL-2R$\beta^{-/-}$ mice at 1 and 3 weeks of age is normal. By 6 weeks of age, the absolute numbers of thymocytes was decreased in comparison with heterozygous littermates and there was also reduction in numbers of $CD4^+CD8^+$ cells (Suzuki *et al.*, 1995). Overall, these data suggest that neither IL-2Rα nor IL-2Rβ is required for essentially normal T cell development in the thymus.

The thymus in IL-2R$\gamma^{-/-}$ mice is markedly diminished in size and cellularity (DiSanto *et al.*, 1995). The absolute numbers of all thymic T cell populations are significantly diminished. Nevertheless, thymocyte differentiation does not appear to be arrested, as the cells exhibit normal patterns of expression for CD4 and CD8, CD3 and the TCR $\alpha\beta$ heterodimer (DiSanto *et al.*, 1995). However, TCR $\gamma\delta$ are not detected in these mice (Cao *et al.*, 1995). It is significant that the IL-2Rγ chain has an essential role in more than one cytokine system. IL-2Rγ is not only a necessary component of the functional high affinity IL-2R. It has been demonstrated that the IL-2Rγ chain is also a functional component of the IL-7 receptor (Noguchi *et al.*, 1993; Kondo *et al.*, 1994). Studies with mAbs specific for the IL-2R γ chain indicate that the γ chain is necessary for formation of high-affinity IL-7 receptor complexes (Kondo *et al.*, 1994).

IL-7 is expressed in the thymus. IL-7 is able to stimulate the growth of immature $CD4^-CD8^-$ adult and fetal thymocytes (Conlon *et al.*, 1989; Watson *et al.*, 1989; Vissinga *et al.*, 1992). IL-7 induces rearrangement of the TCR β gene and sustains expression of the RAG-1 and RAG-2 genes (Muegge *et al.*, 1993). In addition, treatment of mice with anti-IL-7 antibody produces a reduction in the cellularity of the thymus. The double negative population is the the least affected, being reduced by only 43% compared with a reduction by 80% in the double positive subpopulation, 60% in the $CD8^+$ subpopulation, and 83% in the $CD4^+$ subpopulation (Grabstein *et al.*, 1993). These data suggested that IL-7 was important for proliferative expansion but did not prove that it was essential for T cell differentiation (Grabstein *et al.*, 1993). Mice treated with a blocking antibody (A7R34) that recognizes the high-affinity IL-7Rα exhibit thymic hypoplasia (Sudo *et al.*, 1993), affecting most profoundly the $CD4^+8^+$ cells (Sudo *et al.*, 1993). In contrast, transgenic mice that over-express IL-7 display more of all subsets of thymocytes (Samaridis *et al.*, 1991). IL-7R-deficient mice (IL-7R$^{-/-}$) display a marked reduction in

thymocyte cellularity. In this mutant, T cell development is affected during early thymocyte development (Peschon *et al.*, 1994). The major thymocyte subpopulations that express the IL-7R are the $CD4^-CD8^-$ double negative subset and the single positive ($CD4^+8^-$ and $CD4^-8^+$) subset (Sudo *et al.*, 1993). The IL-7R has a critical role in early thymocyte expansion prior to the acquisition of rearranged T cell receptor genes (Peschon *et al.*, 1994), in addition to its role in producing T cell receptor gene re-arrangement.

1.1.4.3 T cell receptor gene rearrangement and thymocyte differentiation

During T cell development in the thymus, T cell receptor (TCR) α, β, γ, and δ genes are rearranged and expressed. TCR rearrangement depends strictly upon the coordinate activity of two recombinase activating genes, RAG-1 and RAG-2 (Schatz *et al.*, 1989; Oettinger *et al.*, 1990). In cell lines and *in vivo*, the products of RAG-1 and RAG-2 are both required for V(D) J recombination (Lin & Desiderio, 1995). There are two periods of high RAG-1 and RAG-2 mRNA expression during different stages of intrathymic development. The first wave peaks early at the $CD25^+$ $CD4^-$ $CD8^-$ $CD3^-$ stage of development and the second wave occurs later at the $CD4^+$ $CD8^+$ stage (Wilson *et al.*, 1994b). Expression of RAG-1 and RAG-2 occurs in the thymic cortex but not in the medullary region (Boehm *et al.*, 1991). Expression of both genes is normally terminated during subsequent maturation and neither $CD4^+$ $CD8^-$ or $CD4^-$ $CD8^+$ (single positive) subpopulations express either RAG-1 or RAG-2 genes (Turka *et al.*, 1991).

During T cell development, the TCR β chain is expressed before the TCR α chain. There is evidence that the rearrangement of the TCR β locus is necessary before the transition from TN to the DP stage of development can occur (Godfrey & Zlotnik, 1993; Palmer *et al.*, 1993). It has been shown that TCR β can be expressed on the cell surface before rearrangement of the TCR α chain (Groettrup & von Boehmer 1993).

Surface expression of TCR β on thymocytes may occur in the form of a dimer (von Boehmer, 1992; Groettrup & von Boehmer 1993), either as a homodimer or paired with the surrogate α chain (von Boehmer, 1992; Lin & Desiderio, 1995). TCR α is not expressed at the $CD25^+$ TN stage (Pearse *et al.*, 1989; Nikolic-Zugic & Moore 1989). The β chain is expressed very highly in the cortical region of thymus, particularly in the subcapsular region (Held *et al.*, 1990). The $CD25^+$ TN cells produce full-length 1.3 kb TCR-β transcripts (Pearse *et al.*, 1989). These cells with functional TCR-β chains are selected and allowed to progress to the DP stage (Godfrey & Zlotnik, 1993), where most TCR α rearrangement occurs (Lin & Desiderio, 1995). It has been suggested that the complex of TCR β with the surrogate α chain may promote cell survival rather than proliferation of the developing T cells (Lin & Desiderio, 1995).

DP thymocytes make up about 85% of lymphoid cells within the thymus (Nikolic-Zugic, 1991) and they have a cortical location (Fowlkes & Pardoll, 1989). The earlier large DP cells (10-15% of all thymocytes) divide several times before they stop proliferating and become small DP cells (70% of all thymocytes) (Scollay & Godfrey, 1995). Approximately 20% of DP cells are large and dividing cells (Fowlkes & Pardoll, 1989). The phenotype of DP thymocytes is predominantly $CD4^+$, $CD8^+$, Thy-1^{hi}, HSA^+, PgP^-, IL-$2R^-$ (Fowlkes & Pardoll, 1989). A small proportion of DP cells survives the processes of selection and becomes $CD4^+CD8^-$ or $CD4^-CD8^+$ 'single-positive' (SP) thymocytes (Scollay & Godfrey, 1995). T cells having reactivity to self antigens expressed in the thymus are deleted by negative selection (Kappler *et al.*, 1987). Positive selection is the process whereby potentially useful (self MHC-restricted) T cells (Kisielow *et al.*, 1988) are selected within the thymus, probably by interaction with MHC molecules expressed by cortical epithelial cells (Nikolic-Zugic, 1991). Most thymocytes die in the thymus (McPhee *et al.*, 1979; Scollay *et al.*, 1980) and this phenomenon

probably results from a combination of nonproductive TCR gene rearrangements (Kronenberg *et al.*, 1986) and the processes of positive and negative selection (Sprent *et al.*, 1988).

The next population to appear in fetal development after the double positives are $CD4^+ 8^-$, followed shortly by the $CD4^- 8^+$ thymocytes. The single positive thymocytes constitute about 10-15% of the lymphocytes in the adult thymus. They are generally intermediate in size and reside mainly in the medulla (Fowlkes & Pardoll, 1989). Single-positive thymocytes are similar to peripheral $CD4^+$ and $CD8^+$ T cells in both phenotype and function (Fowlkes & Pardoll, 1989). In young adult mice, about 1% of thymocytes leave the thymus per day (Scollay *et al.*, 1980). The overall rate of emigration is not affected grossly by large doses of intravenous protein antigens (Scollay & Shortman, 1984). Recent thymic emigrants, like thymocytes with mature phenotypes, are slightly larger on average than peripheral T cells, but this differential is lost within 24 hours of migration (Kelly & Scollay 1990).

The stromal cell content of the thymus provides a microenvironment that is optimal for thymopoiesis (Boyd *et al.*, 1993; Ritter & Boyd, 1993). Thymic epithelial cells (TEC), fibroblasts, macrophages, B cells and dendritic cells (DC) are all known to interact with developing thymocytes. Different types of epithelial cells occupy different anatomical locations (De Maagd *et al.*, 1985; Boyd & Hugo, 1991; Boyd *et al.*, 1993). Thymic stromal elements can be divided into bone-marrow-derived and non-bone-marrow-derived components. The major non-bone-marrow-derived stromal elements consist of cortical and medullary epithelial cells. The major bone-marrow-derived cells are dendritic cells and macrophages (Barclay & Mayrhofer, 1981; Fowlkes & Pardoll, 1989). Thymic dendritic cells are involved in the deletion of self-reactive T lymphocytes (Sprent *et al.*, 1988) and are found predominantly in the medulla (Barclay & Mayrhofer

1981; Adkins *et al.* 1987). The mouse thymic dendritic cells express HSA, the adhesion molecule Pgp-1 (CD44), and leukocyte common antigen (CD45). Moreover, 20-30% of dendritic cells are positive for interleukin 2 receptor α chain (CD25) (Ardavin & Shortman, 1992). Thymic dendritic cells are negative for the granulocyte marker Gr-1, the macrophage marker F4/80, and the B cell marker B220 (Vremec *et al.*, 1992). They express some T cell markers, moderate levels of Thy-1, CD2, and a range of levels of CD8 and MTS 35 (Vremec *et al.*, 1992).

The maturation of $CD4^-$ $CD8^-$ thymocytes is dependent both upon major histocompatibility complex (MHC) II^+ thymic epithelial cells and mesenchymal cells (Anderson & Jenkinson, 1997). The $CD4^-$ $CD8^-$ T cell subsets differ in their stromal cell requirements for maturation to the $CD4^+8^+$ stage. $CD25^+$ $CD44^+$ DN T cells require epithelial cells and fibroblasts, while $CD25^+44^-$ precursors require thymic epithelial cells alone (Anderson *et al.*, 1997). At the $CD4^+8^+$ stage, thymic epithelial cells have been shown to possess unique properties essential for positive selection (Anderson *et al.*, 1996). $CD4^+8^+$ cortical thymocytes are dependent on interaction with the thymic epithelium to undergo positive selection and maturation into $CD4^+$ or $CD8^+$ T cells (Wilkinson *et al.*, 1995). Cortical epithelial cells are unique in their ability to mediate this maturation (Anderson *et al.*, 1994).

Several antigens have been identified (Tucek *et al.*, 1992) that are shared between thymocytes, lymphocytes and thymic stromal cells (TSC). One of these, which is recognised by MTS32 mAb, is present on both cortical thymocytes and epithelial cells (Godfrey *et al.*, 1990). Essentially all medullary thymocytes appeared to be $MTS32^-$ (Godfrey *et al.*, 1990). The vast majority of $CD4^+CD8^+$ and $CD4^-CD8^+$ thymocytes are $MTS32^+$ but the antigen is absent from the $CD4^+CD8^-$ subset (Tucek *et al.*, 1992). MTS32 mAb detected all $CD8^+$ and a subset of $CD4^+$ peripheral T cells but it did not

stain B cells (Tucek *et al.*, 1992). MTS32 is also present on a minor population of bone marrow cells (Tucek *et al.*, 1992). In addition, CD4 and Thy-1, characteristic markers of T lymphocytes in mice, are also expressed by subpopulations of freshly isolated and cultured TSC (Tucek & Boyd 1990).

1.1.4.4 Phenotypic analysis of thymocytes in immunodeficient mice

1.1.4.4.1 *Severe Combined Immunodeficient (scid) Mice*

Mice homozygous for the autosomal recessive mutation, *scid* are severely deficient in mature lymphocytes (Bosma *et al.*, 1983). The immunodeficiency appears to result from a defect in recombination enzymes, leading to a failure to rearrange genes encoding the antigen receptors of T and B cells efficiently (Schuler *et al.*, 1986; Malynn *et al.*, 1988; Lieber *et al.*, 1988). V(D)J recombination is initiated by specific DNA cleavage at recombinational signal sequences and requires components of the general machinery used for double-strand (DS)-break repair (Lin & Desiderio, 1995). The murine scid mutation affects both V (D) J recombination and double-strand break repair (Fulop & Phillips, 1990; Biedermann *et al.*, 1991; Hendrickson *et al.*, 1991). It has been shown that the factor defective in the autosomal recessive severe combined immunodeficiency of Arabian foals is required for V(D)J recombination, resistance to ionizing radiation and DNA-dependent protein kinase activity (Wiler *et al.*, 1995). Irradiation of scid mice promotes both thymocyte development and rescue of rearrangements at the T-cell receptor β (TCR β) locus (Danska *et al.*, 1994; Murphy *et al.*, 1994). Furthermore, it has been shown that irradiation, rescues rearrangements at multiple TCR loci (Bogue *et al.*, 1996). Several gene products are presumed to mediate the recombination of V, D and J elements (Lewis & Gellert, 1989). The products of two genes, RAG-1 and RAG-2,

activate VDJ rearrangement (Schatz *et al.*, 1989; Oettinger *et al.*, 1990). However, the *scid* mutation is not located within the structural genes encoding these recombinases.

Early cells commited to the T-lineage are present in scid thymus (Schuler *et al.*, 1988) but they are unable to differentiate into functional T lymphocytes. Rearrangement of TCR δ , but not γ and β genes, is observed in DNA from scid thymocytes, which indicates that T cell development is arrested at early stage (Carroll & Bosma, 1991). This early block in thymocyte development can be relieved partially by treatment with agents that cause double-strand breaks (DSB), including γ-irradiation (Danska *et al.*, 1994; Murphy *et al.*, 1994). The phenotypes of thymocytes in young adult scid mice resemble those in normal fetal mice in that they are large, Thy-1.2$^+$, CD4$^-$, CD8$^-$, TCR$^-$, IL-2Rα^+, Pgp-1$^+$ and HSA$^+$ cells (Shores *et al.*, 1990; Rothenberg *et al.*, 1993). The vast majority (96%) of these cells expresses the TSA-1 marker (Godfrey *et al.*, 1992).

1.1.4.4.2 *RAG-1 Knockout Mice*

The recombinase activation genes, RAG-1 and RAG-2, are expressed together in immature precursors of T lymphocytes (Wilson *et al.*, 1994b) and B lymphocytes (Ben-Yehuda *et al.*, 1994). Coordinate expression of these two genes is necessary for activation of V(D)J rearrangement to form functional genes that encode the polypeptides that form the T cell receptor and the B cell receptor (immunoglobulin) (Thompson, 1995). Mice that lack functional copies of either the RAG-1 or RAG-2 genes do not develop mature B or T lymphocytes, because failure to recombine the genes encoding the antigen receptors on these halts differentiation (Mombaerts *et al.*, 1992; Shinkai *et al.*, 1992). RAG deficient mice provide, therefore, an excellent background for studying the molecular and cellular mechanisms involved in T cell differentiation. Lymphocyte development in RAG-1 deficient mice can be described as that in the equivalent of "non-leaky" scid mice. Thymocytes in RAG-1 mutant mice do not develop beyond the triple negative CD3$^-$CD4$^-$

CD8$^-$ stage (Godfrey *et al.*, 1994) and most of them are interleukin-2 (IL-2) receptor positive (Mombaerts *et al.*, 1992; Crompton *et al.*, 1994). They are also Thy-1 positive, HSA positive and Sca-1 positive (Mombaerts *et al.*, 1992). Irradiation promotes the appearance of DP thymocytes in RAG-dificient mice (Zuniga-Pflucker *et al.*, 1994; Guidos *et al.*, 1995).

1.1.5 Extrathymic T cell Differentiation

As described above, T lymphocytes differentiate classically in the thymus (Boyd & Hugo, 1991; Ritter & Boyd, 1993). During this process of differentiation, the genes of T cell receptor rearrange and acquire the repertoire of mature, self-tolerant, self-major histocompatibility complex (MHC)-restricted T lymphocytes (Godfrey & Zlotnik, 1993). However, the presence of cells bearing T cell receptors in congenitally athymic nude mice and nude rats (Yoshikai *et al.*, 1986; MacDonald *et al.*, 1987; Rocha, 1990; Takimoto *et al.*, 1992), and existence the unique T cells in the periphery of humans and congenitally athymic nude mice (Preffer *et al.*, 1989; MacDonald *et al.*, 1986; Pardoll *et al.*, 1988; Rocha, 1990) suggests an extrathymic pathway for T cell differentiation. The thymus-independent T cells increase in number with age and contain a considerable proportion of $\gamma\delta$ T cells (Ohteki *et al.*, 1992; DeGeus *et al.*, 1990; Yoshikai *et al.*, 1986).

Despite the lack of a functional thymus, lymphocytes expressing the T cell markers Thy-1, CD4 and CD8 have been well documented in athymic nude mice and rats. The numbers of cells bearing these markers increase substantially with age (MacDonald *et al.*, 1981; Chen *et al.*, 1984; MacDonald *et al.*, 1986; Vaessen *et al.*, 1986; Bell *et al.*, 1987; Lawetzky & Hunig 1988; Takimoto *et al.*, 1992). Several lines of evidence indicate that generation of T cells occurs extrathymically, for instance, in the intestine (De Geus *et al.*, 1990; Mosley *et al.*, 1990; Bandeira *et al.*, 1991; Rocha *et al.*, 1991; Guy-Grand *et al.*, 1991; Rocha *et al.*, 1992a; Lefrancois & Puddington, 1995), the liver (Okuyama *et*

al., 1992; Ohteki *et al.*, 1992; Iiai *et al.*, 1992; Watanabe *et al.*, 1993; Ohtsuka *et al.*, 1994; Kenai *et al.*, 1995), the lung (Gek-Kee *et al.*, 1994) and the omentum of the peritoneal cavity (Andreu-Sánchez *et al.*, 1991).

Most attention has been paid to extrathymic maturation of T-cells within the epithelial compartment of the intestine and in the liver of the mouse (De Geus *et al.*, 1990; Mosley 1990; Bandeira *et al.*, 1991; Rocha *et al.*, 1991; Guy-Grand *et al.*, 1991; Rocha *et al.*, 1992a; Lefrancois & Puddington, 1995; Okuyama *et al.*, 1992; Ohteki *et al.*, 1992; Iiai *et al.*, 1992; Watanabe *et al.*, 1993; Ohtsuka *et al.*, 1994; Kenai *et al.*, 1995). Young nude rats contain IEL with the $CD8^+CD3^-$ $TCR\alpha/\beta^-$ phenotype but a considerable number of $CD8^+$ and $CD4^+$ IEL bearing CD3/TCR α/β can be detected in aged nude rats (12 month old) (Takimoto *et al.*, 1992). Similarly, TCR^+ cells become more prominent in the liver in athymic nude mice (Ohtsuka *et al.*, 1994) and in normal mice with aging (Iiai *et al.*, 1992; Ohteki *et al.*, 1992; Ohtsuka *et al.*, 1994). Their numbers increase with conditions such as malignancies (Seki *et al.*, 1991a), bacterial infection (Watanabe *et al.*, 1993; Abo *et al.*, 1991) and autoimmune disease (Masuda *et al.*, 1991). It is conceivable that thymus-independent T cells may benefit the body under conditions of aging, bacterial infections and malignancies (Abo, 1993).

The phenotype and functional behaviour of thymus-independent T cells differ from classical thymus-derived T-lymphocytes. While those with phenotypes similar to intestinal intraepithelial lymphocytes (IEL) are rare in peripheral lymphoid organs (Rocha *et al.*, 1995), the contribution of thymus-independent T cells as a whole to the T cell pool of normal animals is not known. This is because no single marker exists that defines the whole subset of thymus-independent T cells. However, within the gut and the liver, the $CD8\alpha/\alpha$ homodimer appears to be associated with extrathymic origin. Thymus-independent T cells in both the liver and the intestine in mice contain a large proportion

of γδ T cells and express the CD8 αα homodimer (Ohtsuka *et al.*, 1994). γδ TCR^+ and $CD8\alpha\alpha^+$ IEL are also present in the rats (Takimoto *et al.*, 1992), while about 10% of human intestinal IEL express the α chain but not the β chain of CD8 (Jarry *et al.*, 1990). In human fetal intestine (16-24 weeks gestation), about half of the $CD8^+$ cells in the lamina propria express CD8αα and many $CD8\alpha\alpha^+$ cells can be identified in the villus epithelium. The CD8αα cells in human fetal intestine are virtually all $TCR\alpha/\beta^+$ (Latthe *et al.*, 1994). In addition, a small fraction of adult human intestinal IEL express the CD8αα homodimer and most of these cells are T cells that use the α/β TCR (Taplin *et al.*, 1996). Furthermore, a significant proportion of TCR γ/δ IEL in human intestine co-express CD8 and CD1, a marker of immature cortical thymocytes (Robijn *et al.*, 1993).

Several lines of evidence support the hypothesis that a subset of murine intestinal intraepithelial lymphocytes, particularly those which express the CD8αα homodimer, matures extrathymically (Guy-Grand *et al.*, 1991; Rocha *et al.*, 1991; Rocha *et al.*, 1992a). Circumstantial evidence is the presence of only CD8αα homodimer in the intestinal epithelium in young nude mice (Guy-Grand *et al.*, 1991). Direct evidence for T cell development in normal murine intestine is the presence of RAG-1 protein in a small sub-population of murine intestinal IEL (Guy-Grand *et al.*, 1991; Guy-Grand *et al.*, 1992; Lin *et al.*, 1994a; Boll *et al.*, 1995). RAG-1 mRNA is found among the $CD3^-$ IEL (Guy-Grand *et al.*, 1992). Similarly, RAG-1 and RAG-2 mRNA have been detected in human IEL (Lynch *et al.*, 1995), suggesting that primary T lymphocyte maturation is occurring locally. The subsets of IEL in human small intestine that express the RAG-1 mRNA are $CD2^+$, $TCR/CD3^-$ and $CD2^+$, $CD3^+/TCR^-$ IEL (Lundqvist *et al.*, 1995). Moreover, IL-7 mRNA expression is detected in epithelial layers of human small intestine, indicating that intestinal epithelial cells may provide signals for ongoing thymus-independent T cell differentiation in the gut (Madrigal *et al.*, 1997). Although RAG-1 mRNA has been

detected in human IEL, terminal deoxynucleotidyl transferase (TdT) is not found in human IEL (less than one positive cell per 10^7 lymphocytes). This suggests that T cell development involving TdT-induced junctional diversity does not occur in the adult human intestinal epithelium (Taplin *et al.*, 1996).

Although, there is no one marker of extrathymic origin, studies on extrathymic T-cell maturation in the liver and intestine have shown that in each location the T cells have unique phenotypes (Ohtsuka *et al.*, 1994). For example thymus independent T cells in the liver have TCR of intermediate intensity (intermediate TCR cells) and comprise a significant proportion of DN ($CD4^-$ $CD8^-$) cells (Seki *et al.*, 1991b; Ohtsuka *et al.*, 1994). In this respect, they resemble circulating T cells in nude mice (MacDonald *et al.*, 1987; Kung, 1988; Rocha, 1990). In contrast, IEL express higher levels of TCR and contain a considerable proportion of DP ($CD4^+$ $CD8^+$) cells in both mice (Ohtsuka *et al.*, 1994) and rats (Fangmann *et al.*, 1991). The cells that express intermediate levels of TCR express IL-2Rβ but not IL-2Rα (Watanabe *et al.*, 1993; Ohtsuka *et al.*, 1994). Moreover, most γδ TCR^+ IEL are IL-$2R\beta^+$ (Ohtsuka *et al.*, 1994). In this respect, thymus-independent T cells share some properties with NK cells and it has been suggested that they are part of a more primitive layer of the immune system (Herzenberg *et al.*, 1992; Abo, 1993). NK cells share with thymus-independent T cells in the liver and the intestine constitutive expression of IL-2Rβ (Watanabe *et al.*, 1993; Ohtsuka *et al.*, 1994). In contrast, thymus-dependent T lymphocytes acquire the expression of both IL-2Rα and β after activation. Furthermore, the mode of response and the function of thymus-independent T cells appears to be different to classical T cells. Thymus-independent T cells in both the liver and the intestine exhibit a very poor proliferative response to either T cell mitogens, antigens (Ohteki *et al.* 1992; Watanabe *et al.*, 1993; Siebrecht *et al.*, 1993; Umesaki *et al.*, 1993) and neither nude mice nor nude rats reject allografts or xenografts (Festing *et al., 1978*; Vos *et al.*, 1980; Thomas *et al.*,

1991). However, the thymus-independent T cells in rats respond to activation by phorbol ester and ionomycin with vigorous cytokine production (Murphy, Adelaide, presonal communication). In this and other respects they resemble the NKT cells of mice (Vicari & Zlotnik, 1996), of which some also appear to have an extrathymic origin. Taken together, thymus-independent T cells may be more primitive than thymus-derived T lymphocytes in terms of their IL-2R expression and activation and their function in the contemporary immune system may mainly regulatory. They do not seem to be subject to an active negative selection system, as occurs in the development of thymus-derived T cells (Abo, 1993). Therefore, they contain a significant proportion of T cells bearing T-cell receptors (or forbidden T cell clones) that are identified with mAbs that detect Vβ chains that are common in auto-reactive T cells (Abo *et al.*, 1991; Murosaki *et al.*, 1991). It is interesting, therefore, that NKT cells are emerging as key regulatory cells that may influence the development of autoimmunity (Taniguchi *et al.*, 1996; Baxter *et al.*, 1997; Godfrey *et al.*,1997). It may emerge that this function extends to thymus-independent T cells more generally.

1.1.5.1 Characteristics of thymus-independent T cells

1.1.5.1.1 *Hepatic Mononuclear Cells (MNC)*

Studies on lymphocytes from the livers of normal adult mice have shown that T cells that express intermediate levels of TCR αβ (Seki *et al.*, 1991a; Ohteki *et al.*, 1992) or TCR γδ (Ohteki *et al.*, 1991) reside in hepatic sinusoids. "Intermediate TCR cells" (TCR^{int}) constitute approximately 24% of total MNC in the liver and they contain a significant proportion (approximately 5%) of double-negative (DN) $CD4^-$ 8^- cells (Abo *et al.*, 1991; Seki *et al.*, 1991b; Ohteki *et al.*, 1992). As mentioned above, these cells express a high level of IL-2Rβ (Watanabe *et al.*, 1993; Ohtsuka 1994; Arai *et al.*, 1995). In

contrast, T cells with the $CD4^-CD8^-$ $TCR\alpha\beta^{int}$ phenotype are present in the peripheral lymphoid tissues at only very low frequency (0.2- 0.8%) (Huang & Crispe, 1992).

A population of cells has been reported in adult mouse liver that has the phenotype $CD3^-$ $CD4^-$ $CD8^-$ cells and expresses RAG-1. These cells differentiate *in vitro* into $CD3^{int}$ cells. Therefore, the $CD3^-$ $CD4^-$ $CD8^-$ cells may be precursors of $CD3^{int}$ liver mononuclear cells (Kenai *et al.*, 1995). In support of primary T cell differentiation in the liver, approximately equal numbers of lymphocytes expressing TCR γ mRNA have been detected in the livers of both newborn (day-20) euthymic and athymic mice. This suggests that late in ontogeny, cells expressing rearranged TCRγ genes develop in the fetal liver prior to the dissemination of T cells from the fetal thymus (euthymic foetuses) or in the case of athymic foetuses, in the absence of a thymic influence (Carding *et al.*, 1990). In contrast, the α/β TCR^{int} cells are not present in mouse foetal liver and they appear first in the livers of 4 day-old neonatal mice (Iiai *et al.*, 1992). These cells increase in numbers in the liver with aging (Iiai *et al.*, 1992; Ohteki *et al.*, 1992). Adult athymic nude mice have only TCR^{int} cells, both in the liver and in the periphery (Ohteki *et al.*, 1992), while $CD3^+$ T cells are absent in scid mice (Abo, 1993). Like T cells isolated from the peripheral organs of athymic nude mice, TCR^{int} cells isolated from the livers of normal mice show very weak responses to the T-cell mitogens PhA and Con A (Ohteki *et al.* 1992; Tsuchida *et al.*, 1992).

A population of $B220^+$ $CD4^-$ $CD8^-$ TCR $\alpha\beta^{int}$ T cells is present in the livers of normal adult mice. Large numbers of such cells are present in the livers of mice homozygous for the lpr mutation (Ohteki *et al.*, 1990). These cells are Thy-1^{low} Pgp-1^+ HSA^+ $CD25^{low}$ and while some actively proliferate, others are undergoing apoptosis. It is unclear how or where these intra-hepatic $B220^+$ $CD4^-$ $CD8^-$ TCR $\alpha\beta^{int}$ cells originate or what functions they perform (Masuda *et al.*, 1991; Huang *et al.*, 1994). It has been

suggested by Crispe & Mehal (1996) that rather than supporting a progenitor population (cf expression of B220 by early thymocytes), the liver is a site for the apoptotic elimination of end-stage effector T cells. However, the liver MNC of MRL/ lpr mice proliferate vigorously *in vitro* and the majority of MNC in the hepatic sinusoids are lymphoblastic (Ohteki *et al.*, 1990). Furthermore, the abnormal lymphocytes in MRL-lpr/lpr mice may migrate to the periphery (Ohteki *et al.*, 1990).

Evidence that hepatic MNC express the RAG-1 and RAG-2 genes is contradictory. Makino *et al.* detected mRNA for both RAG-1 and RAG-2 in $B220^-$ hepatic T cells (Makino *et al.*, 1993). Kimura *et al.* also showed that hepatic MNC express these enzymes (Kimura *et al.*, 1995). However, Crispe & Huang believe that these two genes, which are necessary for T cell receptor gene re-arrangement, are not expressed in liver T cells (Crispe & Huang, 1994). It has been proposed that TCR^{int} DN cells in the adult liver may be mature T cells of extrathymic origin, since they express intermediate levels of TCR on the cell surface and they are not able to give rise to the other subsets in *in vitro* culture (Watanabe *et al.*, 1993). Alternatively, they may represent T cells of thymus origin in which the expression of TCR is down-regulated due to antigen stimulation.

The functions of hepatic T cells are not known. The number of TCR^{int} cells increases in malignancies (Seki *et al.*, 1991a). In humans, γδ T cells constitute only a minor population of lymphocytes in liver (< 10%) samples from healthy donors, whereas their number increases (up to 30%) in the liver of patients with cancer. The majority of such TCR $\gamma\delta^+$ cells (>70%) are shown to be lymphoblastic by electron microscopy. Most of the hepatic TCR γδ cells (more than 70%) express a T cell activation marker, Leu-19 (CD56) antigen. Moreover, in mice injected with syngeneic tumor cells, there is an increased number of liver MNC express the activation markers (Seki *et al.*, 1990). A

considerable proportion of such TCR γδ cells (>70%) are DN $CD4^-$ $CD8^-$ (Seki *et al.*, 1990). Bacterial infection causes an increase in the numbers of αβ T cell in the liver, the majority of which are also of the DN $CD4^-$ 8^- phenotype (Abo *et al.*, 1991; Watanabe *et al.*, 1993). During liver regeneration, the proportion and number of $CD3^{int}$ cells increases during the early phase (day 2-4 after partial hepatectomy), while, at the same time the thymus is atrophic (Sato *et al.*, 1993). Finally, the numbers of hepathic MNC increase during pregnancy (Kimura *et al.*, 1995) and their numbers are also increased by administration of estrogen (Okuyama *et al.*, 1992).

1.1.5.1.2 *Intraepithelial Lymphocytes (IEL) in the Mouse Intestine*

Intraepithelial lymphocytes in the mouse small intestine are a heterogenous population consisting mainly of T cells that express the γ/δ TCR (Goodman & Lefrancois, 1988; Bonneville *et al.*, 1988). The TCR γ chain (Vγ5) is detected first in the mouse fetal gut at day 17 of gestation (Carding *et al.*, 1990). T cells expressing the α/β TCR constitute a minor proportion (18%) of the IEL as determined with either a mAb with specificity for a common epitope on all α/β TCR molecules (18%) or a Vβ (KJ-16) family- specific mAb (13%) (DeGeus *et al.*, 1990). It follows, therefore, that most mature T cells residing in the murine intestinal epithelium express CD3 (Goodman & Lefrancois, 1988; Boll *et al.*, 1995) in association with TCRγδ chain and a striking feature of these IEL is that they are exclusively $CD4^-8^+$ (Goodman & Lefrancois, 1988; Camerini *et al.*, 1993). Although 60% of IEL express the Thy-1.2 molecule (Lefrancois, 1987), 93% are $CD8^+$ cells, indicating a substantial fraction of Thy-1^- $CD8^+$ cells. Dual-color fluorescence confirms that about 50% of the $CD8^+$ cells are Thy-1^-, whereas the remaining half are Thy-1^+ (Lefrancois, 1987). There is also a small percentage of Thy-1^+ $CD8^-$ cells, which are shown to be $CD4^+$ (Lefrancois, 1987). Some IEL resemble

peripheral T lymphocytes, as they express Thy-1, TCRαβ and either CD4 or CD8 molecules (Guy-Grand *et al.*, 1993).

The IEL population contains a number of subsets of T cells, including DN ($CD4^-$ $CD8^-$), single positive $CD4^+$ or $CD8^+$, and DP ($CD4^+$ $CD8^+$) cells. The majority of these cells are $CD3^+$ (Guy-Grand *et al.*, 1993), of which about 70% are CD8 single positive cells and 8% are $CD4^+$ $CD8^+$ (DP) (Camerini *et al.*, 1993). IEL contain less than 5% $CD4^+8^-$ T cells (Goodman & Lefrancois, 1988). Small intestinal IEL also contain a small population (10%) of triple negative ($CD3^-$ $CD4^-$ $CD8^-$) cells (Camerini *et al.*, 1993). A small proportion of these triple negative cells are B lymphocytes (approximately 2%) (Viney *et al.*, 1989; Camerini *et al.*, 1993), while the remainder are putative precursors of the intraepithelial T cells.

Most IEL in mouse gut can be divided also into two sub-populations, based on the form of CD8 molecule that they express. One sub-population expresses the CD8 αβ heterodimer, TCR $\alpha\beta^+$ and Thy-1^+, while the other expresses the CD8 αα homodimer. The latter are mainly Thy-1^- and they may express either the γ/δ TCR or the α/β TCR (Guy-Grand *et al.*, 1991). A minority of IELs (up to 40%) are $CD8\alpha\beta^+$ (Guy-Grand & Vassalli, 1993). The CD8 $\alpha\beta^+$, TCR $\alpha\beta^+$ IEL appear to be the progeny of blasts that are induced by antigenic stimulation in the Peyer's patches (Guy-Grand *et al.*, 1978). The other subset are thought to arise from precursors which have undergone antigen independent differentiation in the small intestine, as shown by its presence in nude mice, in germ free mice and in suckling mice (Guy-Grand *et al.*, 1991). Approximately 60% of small intestinal IEL express the CD8 αα homodimer (Camerini *et al.*, 1993). Several lines of evidence suggest that regardless of whether these cells express the α/β TCR or the γδ TCR, those IEL that express CD8αα are produced extrathymically (Guy-Grand *et*

al., 1991; Rocha *et al.*, 1991; Rocha *et al.*, 1992a). Consistent with this view, CD8$\alpha\alpha^+$ (but not CD8$\alpha\beta^+$) α/β TCR$^+$ or γ/δ TCR$^+$ IEL have been identified in thymectomized RAG-1 knock-out mice injected with BM cells from nude mice (Rocha *et al.*, 1994). This subset has not been detected in other tissues and expression of the α/α homodimer has become one of the hallmarks of the IEL compartment (Croitoru & Ernst, 1993).

A subset of CD4$^+$ CD8$^+$ α/β TCR$^+$ (double positive cells) is also found (5-10%) in intestinal epithelium (Mosley *et al.*, 1990; Lefrancois, 1991; Camerini *et al.*, 1993; Lefrancois & Puddington, 1995). Since some IEL appear to be extrathymically derived, it is of interest to study the CD4$^+$8$^+$ population in detail. These cells are not detected in the spleen or lymph nodes (Lefrancois, 1991). The DP intestinal IEL are thought to be expanded in response to gut-derived antigens, because they are not present in germ free animals and their numbers increase with age (Takimoto *et al.*, 1992; Poussier & Julius, 1994). Double positive $\alpha\beta$ TCR$^+$ IEL differ from immature DP thymocytes by expression of TCR $\alpha\beta^{high}$ (Lefrancois, 1991) and homodimeric CD8 α chains (Guy-Grand *et al.*, 1993). Thus CD4$^+$ CD8$^+$ IEL cannot be regarded as immature T cells. They could be a mature CD4$^+$ population that acquires CD8α chains within the epithelium (Guy-Grand *et al.*, 1993) or they might be a separate lineage (Lefrancois & Puddington, 1995). Their origin is unknown, but it is of interest that after activation *in vitro* with Con A, peripheral CD4$^+$ T cells express the CD8 α/α homodimer (Ramirez *et al.*, 1992). Furthermore, repopulation of scid mice with peripheral single-positive CD4$^+$ T cells from various lymphoid organs of immunocompetent donor mice leads to the appearance of DP CD4$^+$ CD8$^+$ T cells in the epithelium of the small intestine (Reimann & Rudolphi, 1995). In the CD4$^+$ subpopulation of IEL, the α/α homodimer may be a differentiation (activation) marker, rather than (or in addition to) a lineage marker.

A small population (10%) of IEL have a triple negative ($CD3^-$ $CD4^-$ $CD8^-$) phenotype (Camerini *et al.*, 1993). This subset of IEL is more abundant in 3-week-old mice and contains RAG-1 mRNA (Guy-Grand *et al.*, 1992). The presence of RAG-1 transcripts in this $CD3^-$ subset suggests that it may contain the precursors for the extra-thymically-derived subset of IEL T cells. The $CD3^-$ cells can be separated into two subsets: $CD3^-$ $CD8^-$ and $CD3^-$ $CD8^+$ IEL (Lin *et al.*, 1994a). $CD3^-$ $CD8^-$ IEL are mostly small, non-granular and phenotypically Pgp-1^+ IL-$2R^+$ $B220^-$, while $CD3^-$ $CD8^+$ IEL are mostly large, granular and phenotypically Pgp-1^- IL-$2R^+$ $B220^+$. The $CD3^-$ $CD8^+$ IEL express the RAG-1 gene (Lin *et al.*, 1994a). These authors suggested that $CD3^-$ $CD8^+$ IEL are an intermediate in extrathymic IEL development and that the differentiation sequence is $CD3^-$ $CD8^-$ to $CD3^-$ $CD8^+$ to $CD3^+$ ($\gamma\delta$ TCR) $CD8^+\alpha\alpha$ (Lin *et al.*, 1994a). Such cells correspond in phenotype to the IEL described by Croitoru *et al.* (1990) in scid mice.

The presence of cells bearing T cell receptors in congenitally athymic nude mice (Yoshikai *et al.*, 1986; MacDonald *et al.*, 1987; Rocha, 1990) provides strong evidence for an extrathymic pathway for T cell differentiation. In nude mice, IEL are present in small numbers (one-eighth of value in normal mice) (Guy-Grand *et al.*, 1993) and the numbers of these cells increase substantially with age (MacDonald *et al.*, 1981; Chen *et al.*, 1984; MacDonald *et al.*, 1986; Lawetzky & Hunig 1988). As mentioned above, a considerable proportion of these T cells express the γ/δ TCR (Yoshikai *et al.*, 1986; DeGeus *et al.*, 1990). The γ/δ TCR^+ IELs are detected in nude mice at day 20 after birth, suggesting that they are generated after birth (Bandeira *et al.*, 1991). CD8 $\alpha\beta^+$ IEL are not found in the nude mice (Guy-Grand *et al.*, 1993). Moreover no DP T cells, $CD4^+$ T cells, α/β TCR^+ or Thy-1^+ $CD3^+$ T cells are detected in the athymic mice (Lawetzky & Hunig 1988; DeGeus *et al.*, 1990). Nevertheless, some Thy-1^+ $CD8^-$ $CD4^-$ cells have been detected in nude mice (MacDonald *et al.*, 1986; Camerini *et al.*, 1993), suggesting that at

least some Thy-1.2$^+$ cells have an extrathymic origin. This possibility is supported by the observation that considerable numbers of αβ TCR$^+$ CD8$^+$ αβ IEL are generated extrathymically in adult thymectomized, irradiated, fetal liver reconstituted (ATXFL) mice when the IEL are examined 12 weeks after fetal liver reconstitution (Poussier *et al.*, 1992). Moreover, some CD8 αβ$^+$ TCR αβ IEL develop in the absence of a functional thymus (Emoto *et al.*, 1996). CD3$^-$ IELs are more common in nude mice than in normal adult mice (Rocha *et al.*, 1995). Most of the IEL in athymic nude mice are TCRγδ$^+$ Thy-1$^-$ and CD8$^+$ (Viney *et al.*, 1989; Camerini *et al.*, 1993), bearing a CD8 molecule comprised of the αα homodimer (Camerini *et al.*, 1993). These T cells apparently do not need antigenic stimulation, because they are present in both germ-free and suckling mice (Guy-Grand *et al.*, 1991). It has been shown that bacterial colonization has little effect on the γ/δ TCR population of IEL (Bandeira *et al.*, 1990; Umesaki *et al.*, 1993).

The presence of IEL in scid mice and RAG-1$^{-/-}$ mice , which have no functional B and T lymphocytes, is further evidence for extrathymic maturation of T cells in the murine intestinal epithelium. IEL in scid mice and RAG-1$^{-/-}$ mice are nearly all CD3$^-$ (Guy-Grand *et al.*, 1991; Rocha *et al.*, 1995), but 50% are found to express the CD8 αα homodimer (Guy-Grand *et al.*, 1991)· It has been suggested that IEL with the Thy-1$^-$ CD8$^+$ phenotype in scid mice may represent an early stage of T cell differentiation that would under normal circumstances acquire the TCR γδ molecule (Croitoru *et al.*, 1990). The CD3$^-$ IEL population in normal, nude and RAG$^{-/-}$ mutant mice expresses only mRNA encoding the γ chain (Guy-Grand *et al.*, 1994). The γδ TCR$^+$ T-cells in murine IEL can be separated into γδ^{Dim} and γδ^{Bright} fractions, according to the level of expression of the γδ TCR. It has been shown that IL-2 and IL-7 are key activation and growth factors for γδ^{Dim} IELs. The γδ^{Dim} T cells express low levels of IL-2R and IL-7R.

Intestinal epithelium contains mRNA for IL-7 but it does not transcribe the gene encoding IL-2. However, αβ T cells contain mRNA for both IL-2 and IL-7. Therefore, both epithelial cells and αβ T cells may be sources of IL-7 for neighbouring γδ T cells, while IL-2 must arise from T cells (Fujihashi *et al.*, 1996). This requirement for IL-2 may explain the partial dependence of IEL on the presence of thymus-derived T cells (Lefrancois & Puddington, 1995). Furthermore, the release of IL-7 by the thymus (Kenai *et al.*, 1993) or by antigenically stimulated thymus derived cells may influence the development of thymus-independent IELs (Rocha *et al.*, 1995). Interaction between epithelial cells and γδ TCR^+ IEL via IL-7 and the IL-7R could be an important cytokine communication for the differentiation of γδ T cells in the intestinal epithelium (Fujihashi *et al.*, 1996).

A formal demonstration that murine small intestine is as effective as the thymus in allowing progressive repopulation of peripheral lymphoid organs has come from experiments involving ectopic organ grafts (Mosely & Klein, 1992). Adult thymectomized, lethally irradiated, bone marrow reconstituted (ATXBM) mice received grafts under the kidney capsule of either fetal thymic lobes or fetal intestine. The presence of either sort of graft resulted in the repopulation of secondary lymphoid organs of the recipients with single positive $CD4^+8^-$ and $CD4^-8^+$ T cells (Mosely & Klein, 1992). These results provide strong evidence of the T lymphopoietic capacity of the intestinal mucosa. However, the origin of these T cells in the fetal grafts was not identified definitively and they may have arisen from clusters of lymphoid cells in the lamina propria.

To determine whether intestinal graft has the capacity to generate IEL, ATXBM mice are grafted with fetal thymus or fetal intestine. In ATXBM mice with fetal thymus graft, both graft-and bone marrow-derived cells are detected in LN and IEL. Forty-five percent of IEL are graft-derived cells. The majority of these cells express TCR

αβ. Graft-derived cells are not found in LN or IEL from fetal-intestine-grafted mice, suggesting that the fetal gut does not contain progenitors for intestinal T cells. However, it is possible that precursor IEL T cells are present in the graft but are unable to migrate in to the gut epithelium (Lefrancois & Puddington, 1996).

Phenotypic analysis of lymphocytes from parabiotic Ly5 congenic mice revealed that peripheral T cells enter the spleen, Peyer's patches and lamina propria, but that very few entered the intestinal epithelium (Poussier *et al.*, 1992). This suggests that IEL are produced locally in the epithelium and that they do not contribute to the recirculating pool of T cells. In addition, treatment of thymectomized adult mice *in vivo* by injection of anti-CD8 mAb, which depleted peripheral $CD8^+$ T cells and $CD8\alpha\beta^+$ IEL, was without any effect on the numbers of CD8 $\alpha\alpha^+$ IEL (Guy-Grand *et al.*, 1991). Taken together with the detection of RAG-1/2 expression in small intestinal IEL (Guy-Grand *et al.*, 1991; Guy-Grand *et al.*, 1992; Boll *et al.*, 1995), these findings support the hypothesis that the murine intestinal epithelium is a site of lymphocyte development.

The thymus-independent IEL differ in many features from thymus derived cells. They appear not undergo the processes of negative and positive selection that have been described for thymocytes. T cells which express TCR that are self-Mls-reactive are deleted in the thymus. In contrast, T cells expressing potentially self-Mls-reactive TCR are not deleted in the TCR αβ $CD4^-$ $CD8^+$ αα IEL (Rocha *et al.*, 1991) and they do not appear to undergo positive selection by contact with classical MHC molecules (Rocha *et al.*, 1992a). This supports the suggestion that they are thymus-independent (Guy-Grand & Vassalli, 1993). Autoreactive cells in the IEL population may not cause generalized autoimmune disease or tissue damage because these cells do not appear to recirculate (Rocha *et al.*, 1992b).

However, the precise role of the thymus in the expansion of thymus-independent IEL (TI-IEL) remains to be clarified. One possibility is that IEL precursors do not traffic through the thymus but require thymic-derived factors (either soluble or cellular) to complete their maturation in the intestine. The other possibility is that T cells traffic through the thymus, where limited maturation may occur, followed by the completion of maturation extrathymically under the influence of thymic-derived factors (Lefrancois & Puddington, 1995).

Finally, as suggested above, the thymus may influence extra-thymic T cell differentiation indirectly. Thymectomy of 3 days old mice results in a significant decrease in the number of γ/δ TCR^+ and α/β TCR^+ CD8 β^- IEL (Lin *et al.*, 1993). Moreover, grafting of nude mice with fetal thymus resulted in an increase in both γ/δ TCR^+ and Thy-1^- α/β TCR^+ IELs. The authors suggested that thymus-independent α/β TCR^+ and γ/δ TCR^+ IELs are influenced in some way by thymic factors or by thymus-derived T cells (Lin *et al.*, 1993). Lin *et al.* (1994b), in another study in neonatally thymectomized (NTX) mice, demonstrated that most γ/δ TCR^+ IEL and virtually all α/β TCR^+ $CD4^-$ CD8 $\alpha\alpha^+$ IEL in young euthymic mice (3-5 week old) are thymus-influenced (Lin *et al.*, 1994b). Similarly, it has been found that there are few $\gamma\delta$ TCR^+ IEL in NTX mice (Lefrancois & Olson, 1994). In addition, a population of immature ($CD8^+$ TCR^-) IEL is greatly increased in some NTX mice as compared to controls. (Lefrancois & Puddington, 1996). However, neonatal thymus engraftment into NTX mice resulted also in an expansion of graft-derived TCR$\alpha\beta$ and TCR $\gamma\delta$ IELs (Lefrancois & Olson, 1994). The results of NTX on the IEL compartment, particularly on $\gamma\delta$ IEL, indicate that the thymus participates in the local extrathymic IEL developmental process by facilitating normal $\gamma\delta$ and $\alpha\beta$ IEL maturation.

1.1.5.1.3 *Lymphocyte-filled Villi (LFV) and Cryptopatches*

Lymphocyte-filled villi are modified villi containing closely packed lymphocytes and dendritic cells. They are covered by epithelium containing specialized antigen-absorptive cells. The lymphoid tissue in these structures often extends down to the level of the muscularis mucosa. Such villi represent about 1% of the total population of villi in rats. Ontogenically, they are detected in the second week of life. Lymphocyte-filled villi are present also in pathogen free rats and in athymic rats (Mayrhofer & Brooks, 1995).

The initial lymphocyte population in suckling rats is surface Ig^-, $\alpha\beta$ TCR^- but from the third week in normal rats and from 7-10 weeks in nude rats, a subpopulation appears that is $\alpha\beta$ TCR^+ and mainly $CD4^+$. The majority of lymphocytes remain Ig^-, $\alpha\beta$ TCR^-, $\gamma\delta$ TCR^-, $CD3^-$ and most express CD25 and CD43. In the rat, LFV are sites of significant cell division but they are excluded from the recirculation of thoracic duct lymphocytes (Mayrhofer & Brooks, 1995). The epithelium overlying LFV has similarities to the follicle-associated epithelium (FAE) of Peyer's patches (PP) in that it contains large numbers of IEL, large MHC class II-positive dendritic cells (Mayrhofer *et al.*, 1983) and it transports horse radish peroxidase from the gut lumen.

Kanamori *et al.* (1996) have described recently the presence of novel lymphoid structures (crypto-patches) in the mucosa of the mouse small intestine. The crypto-patch (CP) occupies the lamina propria in the crypt region of the mucosa and it was estimated that the small intestine contains approximately 1500 of these structures. The differentiation markers expressed by the lymphoid cells in CP (eg. c-kit, interleukin 7 receptor) suggest that these structures may have a primary generative function. This concept is supported by the presence of CP in both severe combined immuno-deficient

(SCID) and RAG-1 knockout mice. Crypto-patches are absent in IL-7R knockout mice that show a considerable reduction in thymus cellularity. However, Kanamori *et al.* have not demonstrated either the transcriptional or translational activities of recombinase activating genes (RAG), or rearrangement of T cell receptor genes, in CP (Kanamori *et al.* 1996). Analysis of CP of 4-week-old nude mice has showed that almost all c-kit$^+$Lin$^-$ CP cells are IL-7R$^+$Pgp-1$^+$. The c-kit$^+$Lin$^-$ cells in CP are able to generate $\alpha\beta$ and $\gamma\delta$ T cells in the IEL compartment of irradiated scid mice. Moreover, these cells generate substantial $\alpha\beta$ T cells in MLNs and to a lesser extent in the spleen and thymus. Furthermore, engraftment of small intestine of nude mice with CP into the kidney capsule of scid mice resulted in the development of T cells in the recipients intestine and MLNs. Five weeks after engraftment, CD3$^+$ T cells are detected in the intestinal epithelium (IELs) and to a lesser extent in the LP. Electron microscopy studies show that the lymphocytes in CP may migrate into the villus epithelium. The authors believe that CPs are site of T lymphopoiesis which can generate local intestinal precursor T cells (Saito *et al.*, 1998).

Aims

General Aim

The general aim of the present study was to examine whether lymphoid aggregates comparable with LFV in rat are present in other species and to concentrate attention on mouse and human because of the availability of a large panel of monoclonal antibodies specific for lymphocyte surface antigens in these species.

Specific Aims

1. To examine the structure and distribution of lymphoid tissue at various sites along the small intestine in humans, mice and other animals, with special reference to structural homologues of LFV.

2. To compare the surface antigen phenotypes of lymphocytes in human and mouse non-Peyer's patch lymphoid tissue and in Peyer's patches.
3. To compare non-Peyer's patch lymphoid tissue with the thymus and to test the hypothesis that it is an alternative site of primary T cell differentiation.
4. To examine turnover and cell division in LFV *in vivo*.
5. To investigate whether lymphocytes in LFV homologues contain either RAG-1 protein or mRNA transcripts encoding RAG-1.
6. To examine the cell surface antigen phenotype of lymphocytes in LFV in congenitally athymic mice, in mice with the severe combined immunodeficiency (*scid/scid*) and RAG-1 knockout mutants.
7. To compare the importance of TNFα, LT or both in the organogenesis of LFV and Peyer's patches in mice.

Hypotheses

1. Lymphoid aggregations similar to LFV in the rat small intestine are also present in other species, are distinct from Peyer's patches and contain lymphocytes which express unique surface antigen phenotypes.
2. Non-Peyer's patch lymphoid aggregations are thymus-independent.
3. Non-Peyer's patch lymphoid aggregations are sites of primary T cell differentiation, where lumenal antigens may play a role in repertoire expansion/selection.

CHAPTER 2

MATERIALS AND METHODS

2.1 STUDIES IN MICE AND HAMSTERS

2.1.1 Animals

2.1.1.1 Mice. Phenotypically normal mice used in this study were of the Balb/c and C57Bl/6 strains. Mutant mice were rNu/rNu on C57Bl/6 background and scid on CB17 background. Gene knockout mice were RAG-1$^{-/-}$ (Mombaerts *et al.*, 1992) on C57Bl/6 background and LT$\alpha^{-/-}$ (De Togni *et al.*, 1994; Banks *et al.*, 1995), LT$\beta^{-/-}$ (Alimzhanov *et al.*, 1997), TNF$\alpha^{-/-}$ (Pasparakis *et al.*, 1996) and TNF$^{-/-}$/LT$^{-/-}$ (Eugster *et al.*, 1996; Amiot *et al.*, 1997) on C57Bl/6 background. All animals were 8-10 weeks old. Balb/c and C57Bl/6 mice were obtained from the Central Animal House of the University of Adelaide, South Australia. Scid mice were produced under barrier conditions in the Medical School Animal House of the University of Adelaide. Nude mice were from the breeding facility of the Walter and Eliza Hall Institute of Medical Research (Melbourne, Australia). RAG-1, LTα, LTβ, TNFα and TNF/LT knockout mice were kindly provided by Dr J. Sedgwick, Centenary Institute of Cancer Medicine and Cell Biology, University of Sydney, Australia.

The normal mice were kept under clean conventional conditions. The scid mice were housed in isolator cages with filtered air and were provided sterile water and mouse food. Nude mice and the knockout mice were transported in cages with air filters and were sacrificed within 24 hours of arrival.

2.1.1.2 Hamsters. The hamster's small intestines were obtained from the CSIRO, South Australia. After removal of small intestine, it was fixed in 10% neutral formalin and processed for embedding in paraffin and stained by haematoxylin and eosin.

2.1.2 Procedure for Killing Animals

The animals were sacrificed by CO_2 inhalation. The small intestine was removed and processed as required (see 2.1.4, 2.1.5 and 2.1.7).

2.1.3 Immunological Reagents

2.1.3.1 Monoclonal antibodies

The details of hamster anti-mouse monoclonal antibodies, rat anti-mouse monoclonal antibodies and mouse monoclonal allo-antibodies used in this study are shown in Table 2.1.

2.1.3.2 Polyclonal antisera

Polyclonal antisera were used as primary antibodies to detect RAG-1 and surface immunoglobulin on B cells. Rabbit anti-mouse RAG-1 (working dilution 1/30), was an affinity purified antibody obtained from PharMingen (San Diego, CA, USA. Product No: 13781A). HRP-conjugated sheep $F(ab')_2$ anti-mouse Ig antibody (Amersham Life Science, Sydney, Australia. Product No: N 9310) was used at a dilution of 1/40 to detect surface immunoglobulin on B cells. This conjugate (HRP-SHAM) was prepared from immunopurified antibody and it had been absorbed with human, rat and rabbit immunoglobulins.

The following polyclonal antisera were used as secondary antibodies in immunohistochemistry. Biotinylated sheep $F(ab')_2$ anti-rat Ig (working dilution 1/1000) (Amersham Life Science, Sydney, Australia. Product No: RPN 1002). This antiserum is purified on affinity columns of rat Ig and affinity absorbed with mouse, rabbit and human immunoglobulins. Goat $F(ab')_2$ anti-hamster IgG (working dilution 1/50) was affinity purified by column chromatography and absorbed with mouse and rat immunoglobulins (Caltag, San Francisco, California, USA. Product No: HA6115). Goat anti-mouse IgG2a

Sca-1	E13 161-7	Rat	Neat	CS	Haematopoietic progenitors, thymocytes	Aihara *et al.*, 1986. B
Sca-2	E3 81-204	Rat	Neat	CS	Haematopoietic progenitors, cortical thymocytes, B cells	Aihara *et al.*, 1986. B
TSA-1	MTS35	Rat	Neat	CS	Cortical thymocytes, TEC, B cells	Godfrey *et al.*, 1992. D
TSA-2	MTS32	Rat	Neat	CS	Cortical thymocytes, TEC T cell subsets	Godfrey *et al.*, 1990. D
Unknown	MTS33	Rat	Neat	CS	Cortical thymocytes, TEC, B cells	Godfrey *et al.*, 1990. D
Unknown	MTS37	Rat	Neat	CS	Thymocytes (Cortex, Medulla), TEC, B cells	Godfrey *et al.*, 1990 D
Unknown	MTS1	Rat	Neat	CS	TEC	Kampinga *et al.*, 1989. D
Unknown	MTS9	Rat	Neat	CS	TEC, Thymocytes (Cortex, Medulla)	Godfrey *et al.*, 1990. D
Unknown	MTS10	Rat	Neat	CS	TEC	Godfrey *et al.*, 1990. D
Unknown	MTS20	Rat	Neat	CS	TEC	Godfrey *et al.*, 1990. D
Unknown	MTS24	Rat	Neat	CS	TEC	D
Unknown	MTS 44	Rat	Neat	CS	TEC	Godfrey *et al.*, 1990. D
CD-11b	Mac-1	Rat	Neat	CS	Myeloid and NKcells	Springer *et al.*, 1979
F4/80	F4/80	Rat	Neat	CS	Macrophages	Hume *et al.*, 1983
MHC II	MK-D6	Mouse	1/20	CS	Dendritic cells, monocytes, macrophages, B cells	Kappler *et al.*, 1981
NK 1.1	P136	Mouse	Neat	CS	Natural killer cells	Koo *et al.*, 1986. E

[1]Species in which antibodies were raised. [2]CS. Culture supernatant. A. Ascites
A. Kindly provided by Dr T. Simmons, Institute of Medical & Veterinary Science, South Australia.
B. Kindly provided by Dr K. Shortman, Walter and Eliza Hall Institute of Medical Research of Melbourne, Australia.
C. A gift from Dr P. Hodgkin, Centenary Institute of Cancer Medicine and Cell Biology, University of Sydney, Australia.
D. Kindly provided by Dr R.Boyd, Monash Medical School, Melbourne, Australia.
E. kind gift of Dr C. Smart, Discipline of Surgical Science, Faculty of Medicine, Newcastle, Australia.

Table 2.1: Monoclonal antibodies used in this study

Surface Ag	Hybridoma Clone	Species[1]	Optimal Dilution	CS/A[2]	Main Specificity	Ref / Sources
TCR-α/β	H57-597	Hamster	Neat	CS	Thymocytes, mature T cells	Kubo *et al.*, 1989
TCR γ/δ	GL3 1A	Hamster	Neat	CS	Thymocytes, mature T cells	Goodman & Lefrancois, 1989
CD3ε	145-2C11	Hamster	Neat	CS	Thymocytes, mature T cells	Leo *et al.*, 1987
CD11c	N418	Hamster	Neat	CS	Dendritic cells	Metlay *et al.*, 1990
CD45	TIB-122	Rat	Neat	CS	All leukocytes	Luqman *et al.*, 1991
Thy-1.2	TIB-107	Rat	Neat	CS	Thymocytes, T cells, (NK cells)	Ledbetter & Herzenberg, 1979
CD4	TIB 207	Rat	1/2000	CS	Thymocytes, T cell subsets monocytes, macrophages	Dialynas *et al.*, 1983
CD4	RM4-5	Rat	1/100	CS	Thymocytes, T cell subsets monocytes, macrophages	PharMingen San Diego, CA, USA
CD8 α	YTS 169.4	Rat	1/10000	A	Thymocytes, T cell subsets	Cobbold *et al.*, 1984. A
CD25	PC-61	Rat	Neat	CS	Subset cortical thymocytes activated T cells, B cells, monocytes, thymic DC	Ceredig *et al.*, 1985. B
B220	RA3 6B2	Rat	1/10000	A	B cells	Coffman & Weissman, 1981a. C
HSA	M1/69	Rat	Neat	CS	Haematopoietic progenitors thymocytes, granulocytes, B cell subsets	Springer *et al.*, 1978. B
Pgp-1	IM7.8.1	Rat	Neat	CS	Leukocytes, Activated T cells, thymocytes	Trowbridge *et al.*, 1982. B

(working dilution 1/1000) (Amersham Life Science, Sydney, Australia. Product No: RPN 1181), was purified by affinity chromatography on immobilized antigen columns, and cross absorption with unwanted mouse and normal human immunoglobulins. Donkey anti-rabbit Ig (working dilution 1/1000) was obtained from Amersham Life Science, Sydney, Australia (Product No: RPN 1004). These antisera were used as second-step reagents where appropriate. Cells labelled with biotinylated antibodies were identified using avidin-biotin horseradish peroxidase complexes (working dilution 1/100) (Amersham Life Science, Sydney, Australia. Product No: RPN.1051).

For indirect immunofluorescence, bound primary antibody was detected with $F(ab')_2$ rabbit anti-rat IgG conjugated with fluorescein isothiocyanate (FITC) (Serotec, Oxford, England. Product No: STAR17B). This antiserum is purified by affinity chromatography. Biotin-conjugated primary antibodies were revealed by a streptavidin-phycoerythrin (PE) conjugate (Southern Biotechnology Associates, INC. Birmingham, AL, USA. Product No: 7100-09).

All antibodies were titrated before use. The polyclonal rabbit anti-mouse RAG-1, FITC conjugated-$F(ab')_2$ rabbit anti-rat Ig and donkey anti-rabbit Ig antibodies were absorbed with spleen and mesenteric lymph node cells before use, as described previously (Mayrhofer *et al.*, 1976).

2.1.3.3 Tyramide signal amplification in immunohistochemistry

A "direct" Renaissance Tyramide signal amplification (TSA) kit (catalog NEL701A) for fluorescence immunohistochemistry and an anti-fluorescein-HRP conjugate (catalog NEL710) for dual colour staining were purchased from NEN Life Science, USA.

2.1.4 Histology

2.1.4.1 Tissue preparation

After removal, the small intestine was opened along the anti-mesenteric border. Moreover, in some cases, small intestinal specimens were opened longitudinally along the mesenteric attachment. These specimens provided mucosa which included the undisturbed anti-mesenteric portion of the circumference of the intestine. The specimens were processed as a Swiss roll (Moolenbeek & Ruitenberg, 1981), fixed in 10% neutral formalin and processed for embedding in paraffin wax.

For morphological analysis, 5μm paraffin sections were stained by using a standard haematoxylin and eosin stain. Random sections were examined to identify and estimate the frequency of LFV. In some cases, serial sections were collected and stained to allow examination of complete lymphoid aggregations.

2.1.4.2 Counting of lymphocyte-filled villi

Counts of LFV were made on conventional H&E-stained sections of tissue from 5 mice. The small intestine from each mouse was embedded in a single paraffin block as a "Swiss roll". The numbers of LFV and classical villi were counted in 5 random sections from each tissue block. Approximately 3200 total villi (classical plus LFV) were counted in 5 mice.

2.1.4.3 Measuring the diameter of LFV

The diameter of LFV was measured by cutting serial sections from frozen tissue blocks, using a cryostat set to cut 5μ sections. The number of sections required to cut through an LFV was recorded for 32 separate examples.

2.1.5 Immunohistochemistry

2.1.5.1 Tissue processing

For immunohistochemistry, segments of the proximal jejunum were opened along the anti-mesenteric border on to nitrocellulose membrane. The edges were trimmed and the tissue was embedded in OCT (Tissue-Tek, Miles Inc, Diagnostics Division, USA), oriented so that sections could be cut in the longitudinal axis of the intestine. The blocks were snap frozen in isopentane chilled over liquid nitrogen and stored at -70°C until required for sectioning. Serial 5μm sections were cut in a cryostat, air dried, and stored at -70°C for no longer than 2 days before staining.

2.1.5.2 Immunohistochemical methods

2.1.5.2.1 *Immunoperoxidase Staining*

The method used was a 3-layered immunoperoxidase technique. Air-dried sections were fixed in cold acetone for 10 min and then washed in phosphate-buffered saline (PBS), pH 7.2. The last wash in each step was with PBS containing 1% bovine serum albumin (BSA) (Fraction V, Bioscience PTY LTD, Australia). Fifty microliters of primary antibody containing 10% normal mouse serum (to block Fc receptor binding sites) was applied at optimal working dilution and the slide was incubated at room temperature in a moist chamber for 60 minutes. Control sections were incubated with PBS containing 10% normal mouse serum. Sections were washed with three changes of PBS and then incubated with the appropriate biotinylated secondary antibody for 60 minutes at room temperature. The secondary antibodies were also diluted in PBS pH, 7.2 containing 10% normal mouse serum in order to block any residual cross-reactivity between secondary antibody and endogenous immunoglobulin in the sections. After three more washes, the sections were incubated for 30 min with avidin-biotin peroxidase complexes (Hsu *et al.*, 1981), washed again and incubated for 10 minutes with 0.5 mg/ml

3-3' diaminobenzidine, (Sigma Chemical Company, USA) in Tris buffer containing 0.068% H_2O_2 . Finally, the sections were post-fixed for 5 minutes in 1% glutaraldehyde (Sigma Chemical Company, USA) in PBS, counter stained with Gill's haematoxylin, dehydrated in alcohol, and mounted in DPX synthetic medium (AJAX Chemicals, Sydney, Australia).

2.1.5.2.2 *Single Colour Conventional Immunofluorescence Staining*

In most cases, acetone-fixed sections were incubated with primary antibodies for 1 hour but in some cases, incubation was extended to overnight. Control sections were incubated with PBS containing 10% normal mouse serum. After three washes in PBS, an appropriate biotin-conjugated secondary antibody was applied to the sections for 1 hour. Following three further washes in PBS, the slides were stained with streptavidin PE conjugate (1/200 dilution in PBS) for 30 min. The slides were then washed three times with PBS, mounted with Mowiol buffered glycerol (pH 8.5) and coverslipped. Immunofluorescence was viewed with a fluorescence microscope (Olympus) using a red (590 nm) interference excitatory filter and a red EY-455 barrier filter.

2.1.5.2.3 *Single Colour Immunofluorescence (Signal Amplification Method)*

The Renaissance direct tyramide signal amplification (TSA-direct) kit was used to improve antigen detection. Acetone-fixed cryostat sections were incubated with TNB blocking buffer (0.1M Tris-HCl, 0.15M NaCl, 0.5% blocking reagent supplied in kit, pH 7.5) for 30 min at room temperature. After draining off the TNB blocking buffer, the sections were incubated with primary antibodies for 1 hour at room temperature. The sections were then washed three times, for 5 minutes each, in TNT buffer (0.1M Tris-HCl, 0.15M NaCl, 0.05% Tween 20, pH 7.5) at room temperature with agitation and then incubated with the appropriate biotin-conjugated secondary antibody for 1 hour. After washing with TNT buffer, sections were incubated with streptavidin-HRP (diluted 1/100

in TNB buffer) for 30 min at room temperature. They were then washed again and incubated with fluorescein tyramide diluted 1/50 in 1 x amplification diluent (supplied in kit) for 10 min at room temperature. Slides were washed and mounted with Mowiol buffered glycerol (pH 8.5).

2.1.5.2.4 *Dual-colour Immunofluorescence Staining (Conventional Method)*

When the two primary antibodies were raised in different species, dual-colour immunofluorescence staining experiments were performed by combining two indirect techniques. However, when the two primary antibodies raised in the same species, direct and indirect techniques were combined. In either case, the fixed sections were incubated first with 10% normal rabbit serum for 30 min at room temperature to block Fc receptors and reduce background staining. As a negative control, sections were incubated in normal rat serum instead of the primary antibody. Single fluorochrome experiments were also performed, to compare the staining patterns of each technique singly with those obtained in the double-fluorochrome technique.

For dual-colour staining combining two indirect techniques, sections were incubated with the first primary (rat anti-mouse) antibody, and then with the first secondary antibody (a rabbit anti-rat antibody conjugated to fluorescein). At this stage, free valencies of the secondary antibody were blocked by incubation with undiluted rat serum. This was followed by incubation with the second primary antibody and the appropriate biotinylated secondary antibody, followed by avidin-biotin PE. All antibodies were used in the presence of 10% normal mouse serum (first stage) or 10% normal rat serum (second stage).

Dual-colour staining with a combination of direct and indirect techniques was performed when one of the primary antibodies was available as a direct conjugate. The indirect-technique was undertaken first, using the unconjugated primary monoclonal

antibody, followed by incubation with FITC-labelled $F(ab')_2$ rabbit anti-rat IgG plus 10% normal mouse serum. The second step consisted of either a monoclonal antibody conjugated directly to PE or a biotin-conjugated antibody. In the case of biotin conjugates, the labelled cells were detected by an avidin PE conjugate.

In both techniques, reagents were added sequentially with washes in between (see 2.1.5.2.2). After the final wash, stained sections were mounted with Mowiol buffered glycerol (pH 8.5). An Olympus microscope, equipped for selective visualization of fluorescence from fluorescein and rhodamine, was used to read the slides.

2.1.5.2.5 *Dual-colour Immunofluorescence Staining with Signal Amplification*

The TSA-direct kit and HRP conjugated anti-FITC were used for dual-colour staining with signal amplification. The incubation with primary antibody (overnight) was followed by washes in TNT buffer and by incubation with FITC-labelled $F(ab')_2$ rabbit anti-rat IgG with 10% normal mouse serum for 1 hour at room temperature. As in the single colour immuno-staining by this method, this was followed by washes in TNT buffer and incubation with an anti-fluorescein-HRP conjugate diluted 1:400 in TNT buffer containing 10% normal mouse serum (30 min at room temperature). After 3 more washes, the sections were incubated with fluorescein tyramide for 10 min at room temperature, then washed in TNT buffer. They were then incubated with a second primary mAb, followed by the appropriate biotin-labelled secondary antibody and avidin-biotin PE, as described for conventional double staining. In the case of biotin-conjugated monoclonal antibodies, the labelled cells were detected by an avidin PE conjugate.

2.1.6 Photography

Photographs were taken using daylight Fujichrome 400 ASA colour reversal film. The exposure times for either fluorescein or phycoerythrin were usually 60 second,

although for some PE-stained sections this was reduced to 10 sec. For dual-colour staining, double exposures were used of 30 sec for fluorescein and 60 sec for PE. For comparison of staining patterns, single exposures for fluorescein and PE images were also acquired from the same area of the section. Double exposure analysis determined how much overlap was present in the staining patterns arising from the different antibodies. In regions of the merged images, where the staining was not superimposed, the colours were either red or green, representing PE or FITC staining, respectively. In regions of the merged images where the staining was superimposed, the colour was yellow, indicating that the two antigens under investigation were co-localized.

2.1.7 Enzyme Histochemistry

2.1.7.1 Procedure for detecting acid phosphatase

Acid Phosphatase was demonstrated in frozen sections from pre-fixed tissues, using naphthol AS-TR phosphate as substrate, essentially as described by Lojda *et al.* (1979). The tissues were fixed at 4°C for 24 hours in 4% paraformaldehyde, freshly prepared in 0.1M cacodylate buffer containing 1% $CaCl_2$, pH 7.2. The tissues were then washed in Holt's medium three times at 4°C for 24 hours (Mayrhofer & Schon-Hegrad, 1983). After fixation, the tissues were washed in cacodylate buffer for 1 hour and then cryopreserved by equilibration with the same buffer containing 10% dimethysulfoxide (DMSO). They were then embedded in OCT compound containing 2.5% DMSO by freezing in isopentane cooled by liquid nitrogen. The blocks were kept at -70°C until required (Mayrhofer & Spargo, 1989). Five micron sections were collected onto gelatin-coated microscope slides (cryostat temperature -30°C), air dried for 1 hour at room temperature and then stained for acid phosphatase as described previously (Lojda *et al.*, 1979; Bancroft, 1982).

2.1.7.2 Procedure for detecting non-specific esterase

Non-specific esterase activity was determined using α Naphthyl acetate as substrate, essentially as described by Lojda *et al.*, 1979 and Bancroft, 1982. Tissue preparation and sectioning were as described for acid phosphatase (2.1.7.1).

2.1.8 Cortisone Resistance of Lymphocytes in Lymphocyte-filled Villi.

2.1.8.1 Hydrocortisone treatment

Male Balb/c mice (8 weeks of age) were injected once intraperitoneally with 2.5 mg of hydrocortisone acetate (Sigma Chemical Co, USA) in saline and killed 48 hours later (Shortman *et al.*, 1988). Untreated mice, matched for age and sex, were used as controls. The small intestines were removed, prepared as "Swiss rolls" and processed for routine histology (see 2.1.4). The total numbers of cells were counted in 43 separate LFVs from treated and 28 from untreated mice.

2.1.8.2 Statistical analysis

The numerical results are expressed as means plus or minus standard deviations. Student's t test was used to evaluate the statistical significance of differences between the numbers of lymphocytes in LFV in the small intestines of the cortisone treated mice and the untreated control mice.

2.1.9 Labelling in vivo with ^{3}H Thymidine

To detect dividing cells in vivo, ^{3}H-thymidine (3H-Tdr) (20Ci/mmol, ICN Pharmaceuticals Inc, USA) was diluted in saline and injected intraperitoneally (1 μCi/g body weight) at 3 hourly intervals. One mouse received only a single injection and it was sacrificed 3 hours later. The remainder (2 mice) were given a total of 4 doses and were

killed 3 hours after the last injection. Formalin-fixed small intestine (Swiss roll) was prepared for autoradiography.

Sections were cut at 5 μm and air dried. The slides were dewaxed in 3 changes of analytical grade xylene and washed through grades of ethanol (50%, 75%, and 2 x 100%). The slides were then dried in a 37°C oven and dipped in photographic emulsion (Amersham LM-1). After 3 weeks of exposure (4°C), the slides were developed with Kodak D-19, fixed with Ilford Hypam Rapid Fixer and counterstained with Gill's haematoxylin (1 min). They were then deydrated and mounted. The percentage of labelled lymphocytes in sections of LFV was determined by counting the total labelled and unlabelled lymphocytes in 5 separate LFV.

2.2 STUDIES IN HUMAN

2.2.1 Small Bowel Specimens

Segments of small intestine were obtained at operation from 6 adult patients at sites of intended anastomosis (details in Table 2.2). Informed consent was obtained under guidelines of the Human Ethics Committee of The Queen Elizabeth Hospital. In 3 patients (surgical treatment of obesity), there was no intra-abdominal pathology. However, in one (patient 2), the specimen was obtained from a blind loop during revision of a therapeutic gastro-ileal bypass. In the other 3 patients (resections of caecal or colonic carcinoma, or treatment of chronic pancreatitis), segments of small intestine distant from the disease were obtained during anastomotic procedures.

The segments were chilled on ice and transported to the laboratory within 30-60 minutes of resection. Each specimen was opened longitudinally along the attachment of the mesentery. This provided tissue which included the undisturbed anti-mesenteric portion of the circumference of the intestine. In some cases, parts of the surgical specimen were opened longitudinally opposite to the mesenteric attachment (anti-mesenteric).

These segments provided mucosa which included the undisturbed mesenteric portion of the circumference.

The mucosa was dissected free from the muscularis in the tissue plane of the submucosa, using fine scissors. Strips of mucosa were cut in the longitudinal axis of the intestine, fixed in 10% neutral formalin and processed for embedding in paraffin wax. In some cases, longer strips were prepared as "Swiss-rolls" prior to fixation. Other strips of tissue were embedded in OCT medium (Tissue-Tek, Miles Inc, Diagnostics Division, USA), frozen by cooling in an isopentane bath chilled with liquid nitrogen (Mayrhofer & Spargo, 1989). Blocks were stored at -70°C until required for sectioning.

Table 2.2: Details of tissue donors used in this study.

Source (case No)	Pathological status of specimen	Age	Sex	Diagnoses
Jejunum (3)	Normal	37	M	Obesity[a]
Jejunum (5)	Normal	27	F	Obesity[a]
Jejunum (4)	Normal	66	M	Chronic Pancreatitis[b]
Jejunum (2)	Blind loop	36	M	Obesity[c]
Ileum (1)	Normal	26	F	Carcinoma caecum[d]
Ileum (6)	Normal	78	M	Carcinoma colon[d]

[a]Creation of gastric bypass.
[b]Pancreatico-jejunostomy.
[c]Reversal of gastric bypass.
[d]Right hemi-colectomy

2.2.2 Immunological & Immunohistochemical Reagents

The sources and the specificities of the monoclonal antibodies used in this study are shown in Table 2.3. A mouse anti-giardia mAb (1B5, IgG1) was used as an irrelevant negative control (Mayrhofer, unpublished). The horseradish peroxidase

CD25	7G7-B6	a	Subset cortical thymocytes, activated T cells, B cells, monocytes	Knapp *et al.*, 1989
CD45RA	FMC-7	a	Naive T cells, B cells, monocytes	Ferro & Zola, 1990
CD45RO	UCHL-1	a	Memory T cells, B cell subset, monocytes, macrophages	Smith *et al.*, 1986
CD71	OKT9	ATCC	All proliferating cells	-
CD117 (c-kit)	YB5-B8	b	Haematopoietic progenitors, subset of thymocytes	Ashman *et al.*, 1994
MHC class II	FMC52	a	Dendritic cells, monocytes, macrophages, B cells	Zola *et al.*, 1988

a. Kindly provided by Dr P. McArdle, Flinders Medical Centre, South Australia.
b. Kindly provided by Dr L. Ashman, Hanson Centre for Cancer Research, Institute of Medical and Veterinary Science, South Australia.

Table 2.3: Monoclonal antibodies used in this study

Cluster of Differentiation	Monoclonal Antibody	Source	Main Specificity	Ref
CD1a	OKT6	ATCC	Cortical thymocytes, Langerhans cells	-
CD2	OKT11	ATCC	Thymocytes, T cells, NK cells	-
CD3	OKT3	ATCC	Thymocytes, T cells	-
CD4	OKT4	ATCC	Thymocytes and T cell subsets, monocytes, macrophages	-
CD5	WM-13	a	Thymocytes, T cells, subset B cells	Zola *et al.*, 1991a
CD7	HB2	a	Haematopoetic stem cells, thymocytes, T cells	Knapp *et al.*, 1989
CD8	OKT8	ATCC	Thymocytes and T cell subsets	-
CD19	FMC63	a	B cells	Zola, *et al.*, 1991b
CD20	L26	Dako	B cells	Petruch *et al.*, 1992

conjugate of $F(ab')_2$ sheep anti-mouse immunoglobulin (immunopurified and absorbed with human immunoglobulin) was obtained from Amersham Life Science (Sydney, Australia). This conjugate (HRP-SHAM) was used at a dilution of 1/20.

2.2.3 Histology

Sections (5µm) from paraffin-embedded blocks were de-waxed and stained with H&E. Random sections were examined to identify and estimate the frequency of specific lymphoid tissues. In some cases, serial sections were collected and stained to allow examination of complete lymphoid aggregations.

2.2.4 Immunohistochemistry

For immunohistochemical studies, 5µm sections were cut from frozen tissue blocks and air-dried at room temperature for at least 1 hour before fixation in either 95% ethanol or acetone at 4°C for 10 minutes. After rehydration in cold phosphate-buffered saline (pH 7.4), the sections were stained by an indirect immunoperoxidase technique, essentially as described elsewhere (Mayrhofer & Spargo, 1989). Normal human serum (final concentration 10%) was added to all antibodies. Incubation with primary antibodies (neat culture supernatants) and secondary antibody (HRP-SHAM) were for 1 hour at 4°C in a humidified chamber. Bound conjugate was detected by incubating the section with 0.068% H_2O_2 plus 0.5mg/ml diaminobenzidine (Sigma Chemical Company, U.S.A.) in 0.05 M tris buffer (pH 7.6) for 10 minutes. The sections were counterstained with Gill's haematoxylin and mounted in D.P.X synthetic medium (AJAX Chemicals, Sydney, Australia).

2.2.5 Combined histochemistry & Immuno-histochemistry

To detect mast cells in tissue sections stained with mAb YB5.B8 (anti-c-kit) combined histochemistry and immuno-histochemistry were used, essentially as described elsewhere (Mayrhofer *et al.*, 1987). Freshly cut frozen sections were fixed immediately in cold Carnoy's fixative (10 min), washed in cold ethanol (2 minutes) and rehydrated in PBS briefly. Sections were stained with 0.1% Alcian blue 8GX (BHD Chemicals Ltd., Poole, U.K.) in 0.7 M HCl for 20 minutes. The sections were rehydrated in PBS prior to incubation with antibodies (as described before).

2.2.6 Intraepithelial Lymphocyte (IEL) Counts

Counts of total IEL were made on conventional H&E-stained sections of ILF (5 separate ILF in the jejunum or the ileum), LFV (5 separate LFV in the jejunum) and in the FAE of PP (5 follicles in sections of PP from jejunum or ileum). The counts were expressed as the number of lymphoid cell nuclei per 100 epithelial cells. In the case of conventional villi, at least 2000 epithelial cells (about 10 villi) were counted.

The relative numbers of IEL stained by individual mAb in the FAE of PP and ILF, and in epithelium overlying LFV and adjacent villi, were estimated by counts on serial sections using a 40 x objective lens. Counts of IEL stained with each mAb were expressed as percentages of the total lymphocyte nuclei in the epithelium. The specific staining of lymphocyte cell membranes with mAbs (clearly circumferential staining) was distinguished easily from the granular endogenous peroxidase reaction in the cytoplasm of eosinophils.

2.2.7 Statistical Analysis

Results were expressed as mean % of IEL (or subsets of IEL) in different lymphoid aggregates $\pm$ SD. Student's t test was used to estimate the significance of

differences observed in the frequency of IEL in the epithelium overlying the various lymphoid aggregates and in adjacent villi.

2.2.8 Photography

Photographs were taken with an Olympus photomicroscope using Agfa Optima 100 ASA film and employing a blue filter (LBD-2N).

2.2.9 Magnification

Total magnification was the product of the reproduction ratio of the objective multiplied by the magnification factor of the camera eyepiece (3.3). In some cases, an additional magnification factor (1.25) was added, due to the use of an extension tube lens system:

Total Magnification = objective x 1.25 x 3.3.

CHAPTER 3

CHARACTERISATION OF ISOLATED LYMPHOID AGGREGATIONS IN THE MUCOSA OF THE MOUSE AND HAMSTER SMALL INTESTINE

3.1 INTRODUCTION

In recent years, considerable attention has been paid to extrathymic maturation of T-cells within the epithelial compartment of the intestine of the mouse. The origin of thymus-independent IEL, which appears to be distinct from the main thymic pathway, is poorly understood. Whether the intestinal epithelium provides the complete environment for their development from $CD3^-$, RAG^+ precursors or whether the thymus (or thymus-derived T cells) is necessary for full expansion of thymus-independent IELs is still controversial. It is also possible that they might originate within the lamina propria (Rocha *et al.,* 1995), or at other sites in the intestine.

Recently, an organized lymphoid structure has been identified in the mucosa of rat small intestine and this has been designated as a lymphocyte-filled villus (LFV) (Mayrhofer, 1994). The surface antigen phenotype of cells in LFV was found to be different from lymphocytes in the other gut lymphoid aggregates. It has been suggested that these novel structures are another possible site of primary extrathymic T cell differentiation (Mayrhofer & Brooks, 1995).

To study whether structures similar to LFV are also present in other rodents, the mouse was chosen for study. A large range of antibody reagents are available for characterization of lymphocytes and accessory cells in this species and a number of natural mutations and gene knockouts facilitate studies on the development and differentiation of lymphoid cells and tissues.

3.2 RESULTS

3.2.1 Histological Observations in Normal Mice and Hamsters

3.2.1.1 Mice. Histological studies on the small intestine of Balb/c mice revealed three lymphoid structures. These were classical Peyer's patches, isolated lymphoid follicles,

and structures similar to LFV in the rat. Isolated lymphoid follicles (Fig 3.1a) resembled closely the follicles within PP and they shared with PP a distribution along the anti-mesenteric border of the intestine. Initially, it was thought that they might be the mouse homologues of LFV. It was only when these structures were stained with antibodies against either the B220 antigen or immunoglobulin that a follicle of B cells (without a germinal center) was revealed (Fig 3.1b). It was possible, by exploring the mesenteric border of the gut, to avoid all of the lymphoid structures that contain B cell follicles. This led to the identification of LFV (Fig 3.2a), which are packed with lymphocytes but contain no organized follicles of B cells.

Histological studies of LFV showed that they were distributed throughout the small intestine and at all points on the circumference, including both mesenteric and anti-mesenteric borders. Counts on Swiss rolls sectioned along the mesenteric border indicated that the frequency of LFV was approximately 1 per 118 villi. The mean diameter of LFV was 75 μm, equivalent to 15 sections of 5 μm thickness. Serial sections of LFV showed that they were limited to the mucosa and they did not extend through the muscularis mucosa at any point. They contained large numbers of lymphocytes. The lymphocytes were most densely packed at the bases of LFV and were least dense towards the villus tip and immediately subjacent to the overlying epithelium (Fig 3.2a).

The epithelium covering the LFV was similar to that on adjacent villi. It was a simple tall columnar epithelium containing mucous secreting goblet cells. The distribution of lymphocytes in the epithelium appeared similar to that in the epithelium covering adjacent villi. The IEL occurred as single cells, usually below the level of the enterocyte nuclei. In this respect, the epithelial layer of LFV differs from that covering either ILF or Peyer's patches, where lymphocytes are clustered into groups in the dome epithelium (Rowinski *et al.,* 1984). Lymphocyte-filled villi were observed in Balb/c and

Figure 3.1

Haematoxylin and eosin stained sections of jejunum from Balb/c mice. **a**- an isolated lymphoid follicle, which is considerably broader than a classical villus. **b**- B cells in an isolated lymphoid follicle detected on a frozen section by sheep anti-mouse Ig, using an indirect immunoperoxidase technique. Original magnification, a x 41, b x 83.

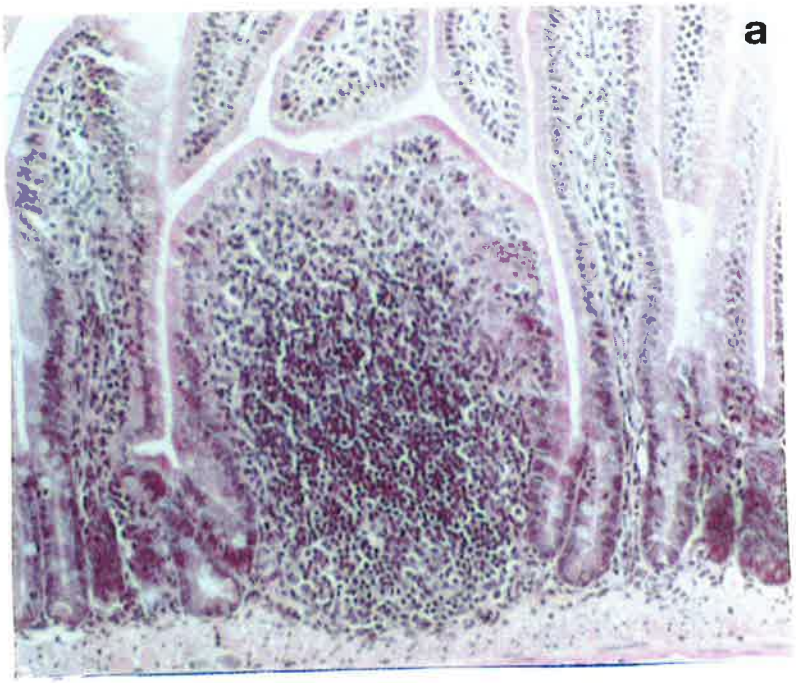
a

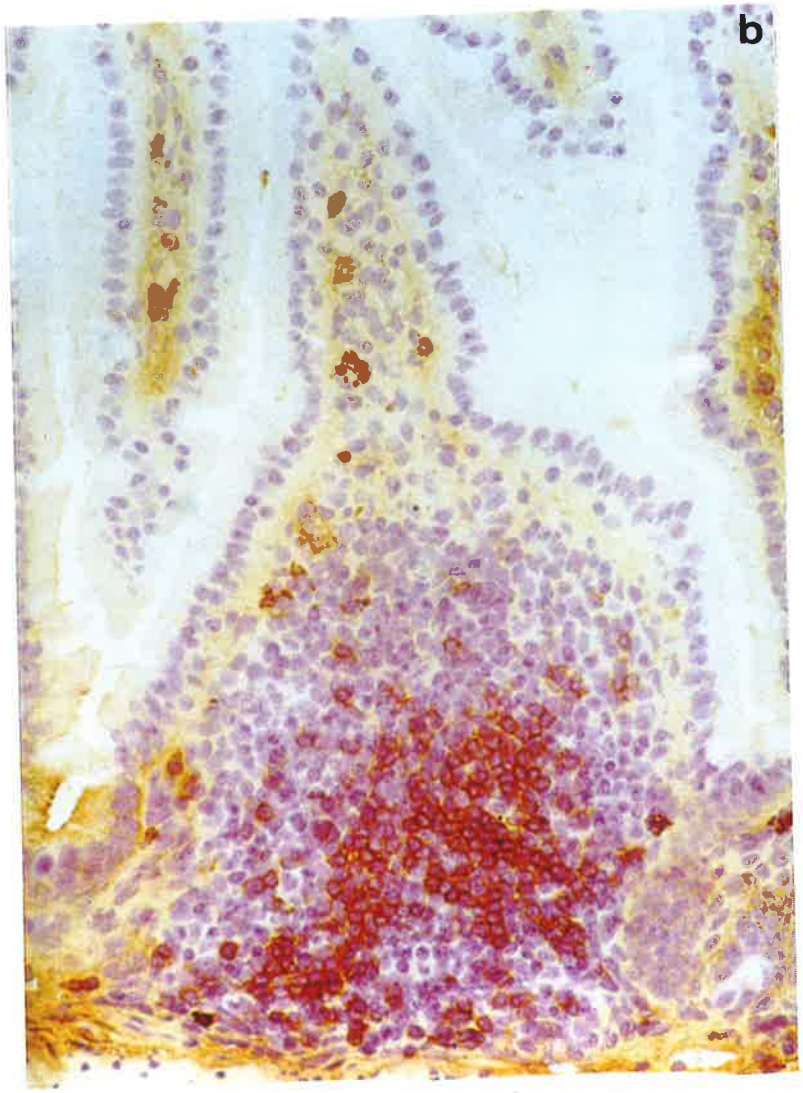
b

Figure 3.2

Haematoxylin and eosin-stained sections of LFV in the jejunum from a normal Balb/c mouse (**a**), a C57Bl/6 athymic nude mouse (**b**), a CB17 mutant scid mouse (**c**) and a C57Bl/6 RAG-1 knockout mouse (**d**). Original magnification x 83.

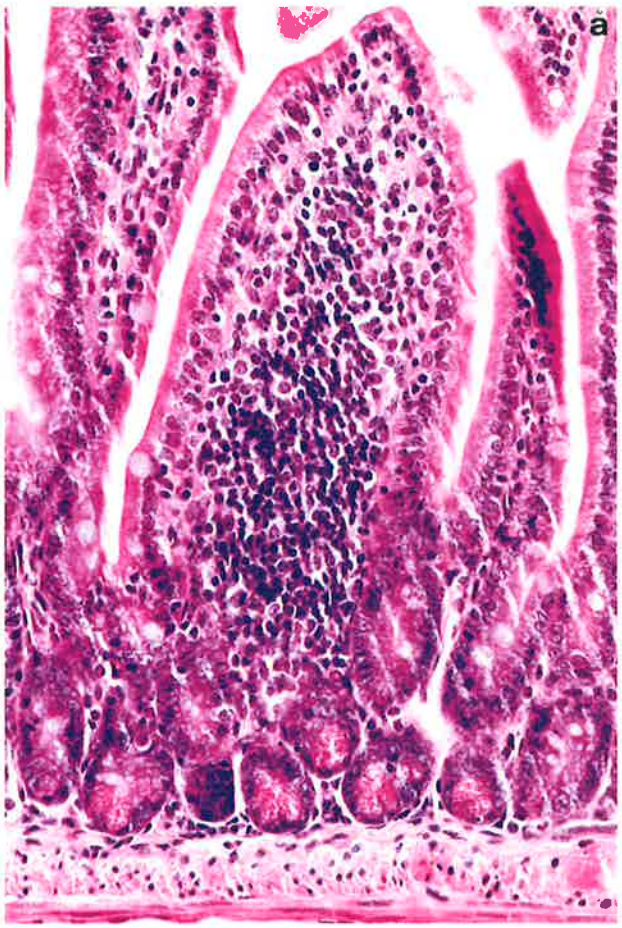
a

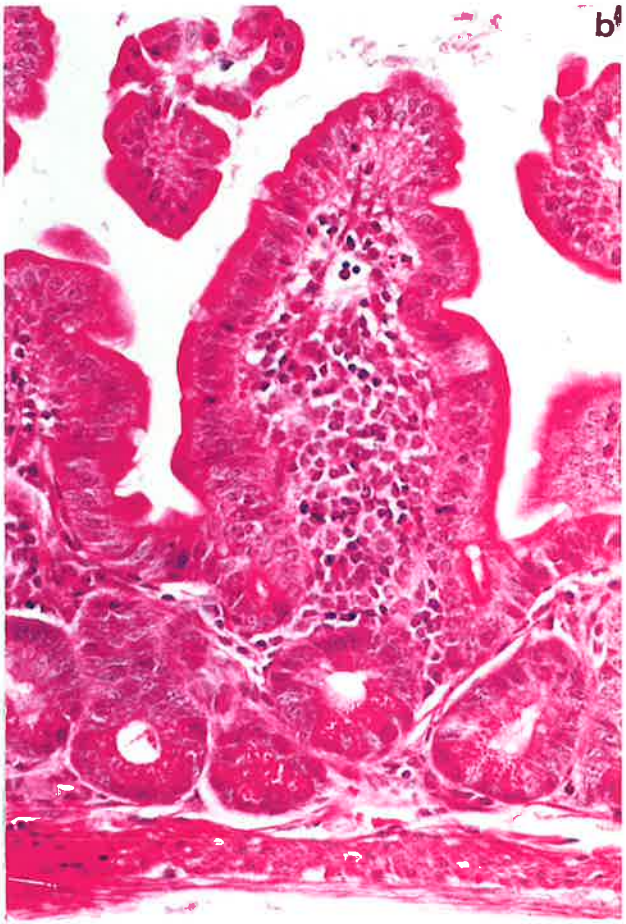
b

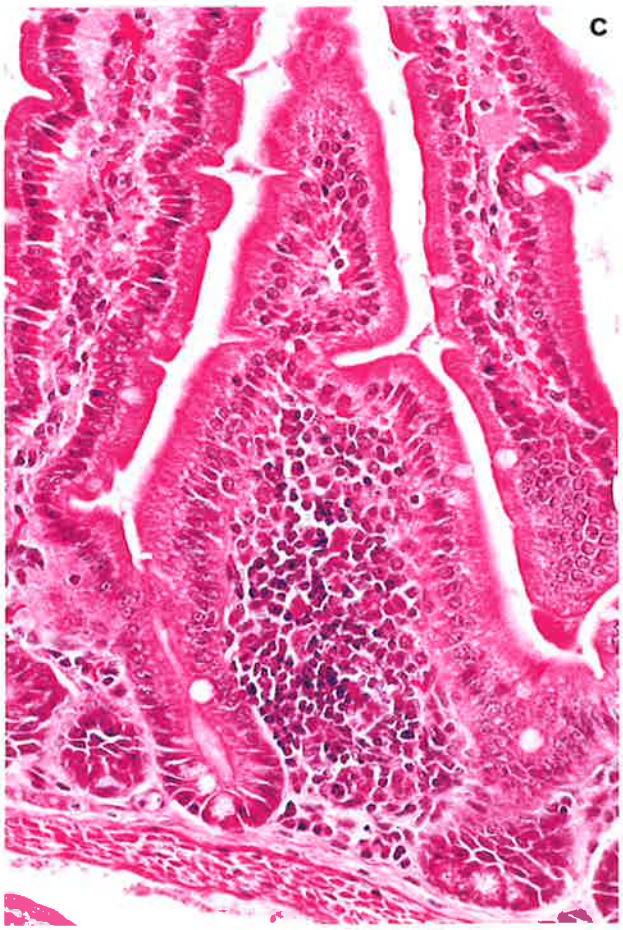
c

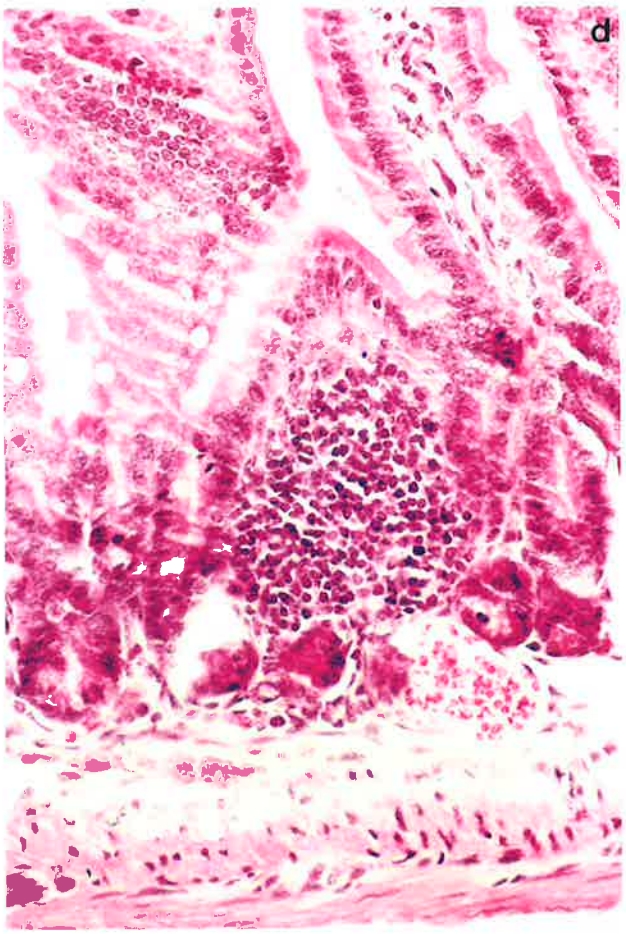
d

C57Bl/6 mice but in the latter strain, they were slightly smaller in size than in Balb/c mice.

3.2.1.2 Hamsters. To examine whether structures similar to lymphocyte filled villi in rats and mice are also present in other laboratory rodents, histological studies was performed on the small intestine of Syrian hamsters. LFV were also found in this species (not shown). They were distributed throughout the small intestine and at all points on the circumference, including both mesenteric and anti-mesenteric borders. LFV in hamster had close similarities to mouse LFV in morphology. Because antibody reagents were not available to characterize the lymphocyte populations in these structures, no further studies were undertaken in the hamster.

3.2.2 Histological Observations in Nude Mice, Scid Mice and RAG-1 Gene Knockout Mice

Because LFV have been observed in athymic nude rats, studies were undertaken to examine whether similar structures were also present in nude mice, scid mice and RAG-1 mice. LFV were easily detected in all three mutants and they were of similar size and frequency as in their normal counterparts (Fig 3.2b-d). This indicates that the lymphocyte population in LFV in the mouse is not derived from thymic emigrants and that the structures can develop in an apparently normal manner without requirement for rearrangements in the genes encoding either immunoglobulin or the T cell receptor.

3.2.3 Histological Observations in Mice Deficient in TNFα, LTα, LTβ or TNF plus LTα

It is of interest to know whether LFV are modifications of the same ontogenetic process that gives rise to organised lymphoid tissue in the gut (Peyer's

patches) and systemically (lymph nodes and spleen). It has been reported that inactivation of the genes encoding subunits of the TNF and LT molecules, and of the TNFRl, lead to phenotypic changes within these organs (reviewed, Mayrhofer, 1997). Targeted knockout of the murine LTα gene disrupts the development of lymph nodes and Peyer's patches and results in alterations of splenic architecture, characterized by the absence of distinct B and T cell areas (De Togni *et al.,* 1994; Banks *et al.,* 1995). Although LTα-deficient mice do not have normal mesenteric lymph nodes (MLN) (De Togni *et al.,* 1994), abnormal lymph-node-like structures are detected in the mesentery of some of these mutants (Banks *et al.,* 1995). The development of the thymus and intra-thymic T lymphopoiesis appear normal (De Togni *et al.,* 1994; Banks *et al.,* 1995). Moreover, IEL are present with apparently normal distribution in the small intestine of LTα-deficient mice, suggesting that LT is not required for recruitment of IEL precursors or for their subsequent differentiation (De Togni *et al.,* 1994). Lβ-deficient mice also lack Peyer's patches and peripheral lymph nodes and the splenic architecture is disorganized, with the absence of germinal centers and follicular dendritic cells (FDC) (Koni *et al.,* 1997). However, unlike LTα-deficient mice, LTβ-deficient mice have mesenteric lymph nodes (MLN) (Koni *et al.,* 1997; Alimzhanov *et al.,* 1997).

It has been shown that LTα and TNFα share the same cell surface receptors, designated 55 kD and 75 kD TNF-R (Brockhaus *et al.,* 1990). Inactivation of the TNFα gene by homologous recombination in embryonic stem cells gives rise to mice in which there is disruption of splenic primary B cell follicles and failure to form organized FDC networks and germinal centers. However, in contrast to the LTα knockout mice, lymph nodes and Peyer's patches are detected in these TNFα knockout mice, suggesting that TNFα is not necessary for lymphoid organogenesis (Pasparakis *et al.*, 1996). The combined inactivation of both TNF and LTα genes disrupts the development of lymph

nodes and Peyer's patches completely. Moreover, the splenic microarchitecture is disorganized and this is characterized by the loss of the clearly defined T and B cell areas (Eugster *et al.,* 1996). Nevertheless, the size and microscopic structure of thymus appears normal in these mutant mice (Eugster *et al.,* 1996).

In the present study on mice with a C57Bl/6 background, Peyer's patches were found in TNFα gene knockout mice but they were not detected in either LTα, LTβ or TNF/LT gene knockout mice. Similarly, isolated lymphoid follicles were observed in TNFα gene knockout mice but were not found in neither LTα, LTβ nor TNF/LT gene knockout mice. MLN were found in TNFα and LTβ gene knockout mice but were not visible in either LTα or TNF/LT gene knockout mice. IEL were present in all of these mutant mice but in TNF/LT gene knockout mice, the numbers of IEL appeared fewer than in the normal counterparts.

In view of the profound defects in peripheral lymphoid organs in LTα, LTβ and TNF/LTα knockout mice, the development of LFV were analyzed by morphological examination. LFV were detected in all of these mutant mice (Fig 3.3). In LTα, LTβ and TNFα gene knockout mice, the sizes of the LFV were similar to those in normal C57Bl/6 mice (Fig 3.3a-c). However, in TNF/LT gene knockout mice, LFV were present but they appeared smaller than those in the normal counterparts (Fig 3.3d). The effects of inactivation of the genes encoding TNFα and LT on the development of PP, MLN, ILF, IEL and LFV are summarized in Table 3.1.

Figure 3.3

Haematoxylin and eosin-stained sections of LFV in the jejunum of C57Bl/6 mice with knockouts of the genes encoding LTα (**a**), LTβ (**b**), TNF α (**c**) or TNF/LT (**d**). Original magnification x 83.

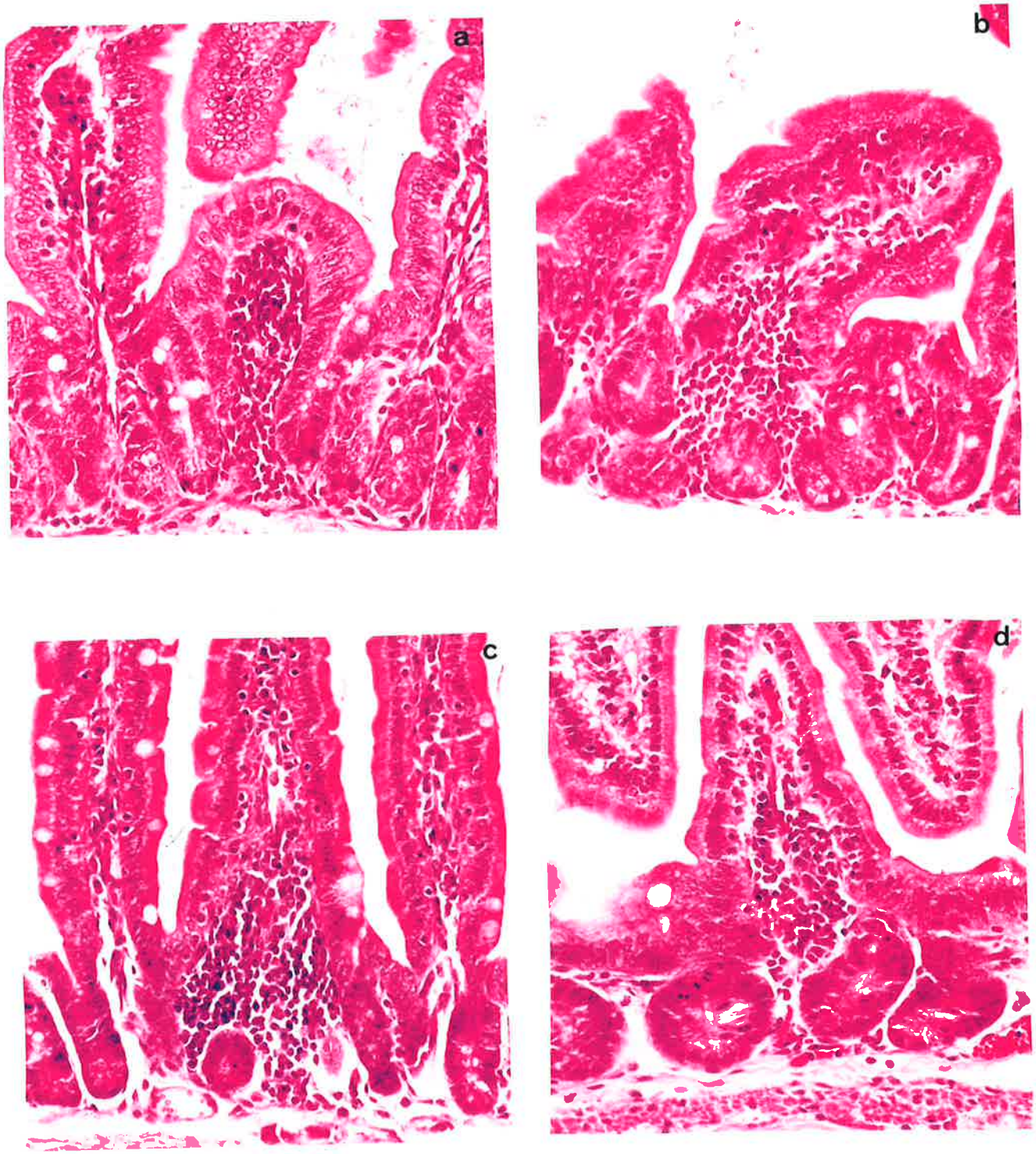
a
b
c
d

Table 3.1-The effect of inactivation of the genes encoding TNFα and LT on the development of PP, MLN, ILF, IEL and LFV

	$TNF\alpha^{-/-}$	$LT\alpha^{-/-}$	$LT\beta^{-/-}$	$TNF/LT^{-/-}$
PP	+	-	-	-
MLN	+	-	+	-
ILF	+	-	-	-
IEL	+	+	+	±
LFV	+	+	+	±*

± Reduced in number
±* Present but reduced in size

3.2.4 Identification the Surface Antigen Phenotype of the Cells in LFV in Normal Mice by Immunohistochemistry and Single-Colour Immunofluorescence

In order to determine the phenotype of the lymphocytes contained within the LFV, studies commenced with indirect immunoperoxidase, using a large panel of monoclonal antibodies (Table 3.2). The expression of antigens by cells in the LFV in Balb/c and C57Bl/6 mice was compared with antigen expression by immature T cells (thymus), IEL, lymphocytes in PP and lymphocytes in the lamina propria of classical villi.

In the immunoperoxidase technique, where control sections were incubated with PBS in place of specific antibodies, only the endogenous peroxidase staining of eosinophils was observed. In contrast, the staining patterns obtained with the specific antibodies were distinctive when examined on the positive control tissues such as thymus and PP.

The distribution of B lymphocytes in LFV in normal mice was determined by staining with mAb RA3-6B2 (anti-B220) or sheep anti- mouse Ig. Anti-B220 and anti-Ig stained only scattered cells in LFV (Fig 3.4a,b). The nature of the $B220^{+}$ cells will be

Figure 3.4

Photomicrographs of frozen sections through LFV in the jejunum of normal Balb/c mice stained by the indirect immunoperoxidase technique. **a**- section stained with mAb RA3-6B2 (anti-B220). **b**- section stained with sheep anti-mouse Ig. Sections were counterstained with haematoxylin and eosin. Original magnification x 83.

a

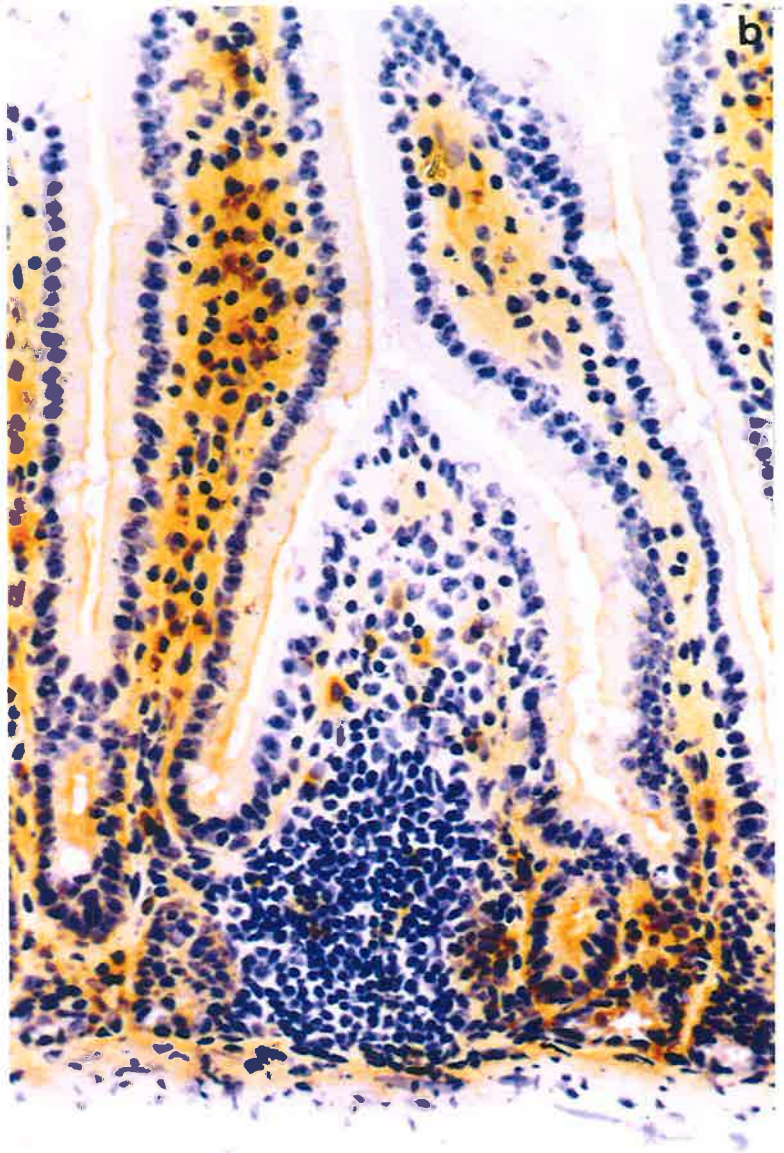
b

discussed later (see Chapters 4 and 5). Moreover, alternate serial sections from some LFV were stained with anti-Ig and mAb RA3-6B2 to examine whether LFV contained B cell follicles. The results indicated that LFV contained only scattered B cells and they did not contain follicles. In contrast, superficially similar structures which were somewhat larger and are referred to above as isolated lymphoid follicles each contained a small follicle of B cells without an obvious germinal centre (see Fig 3.1b). This distinction was vital for the identification of LFV as unique structures.

Essentially all of the cells within LFV were stained by mAb TIB-122 (anti-CD45) (Fig 3.5a). Most of the lymphocytes were stained strongly by mAb TIB-107 (anti-Thy-1.2). Thy 1.2^{+} cells were also numerous in the epithelium and lamina propria of classical villi, where they were considered to be T cells (Fig 3.5b). However, in the LFV, very few lymphocytes expressed the surface markers that are expected of mature T cells, such as CD3, TCR α/β or TCR γ/δ (Fig 3.6). The mAb L3T4 (anti-CD4) stained a subpopulation of the lymphocytes but mAb YTS.169.4 (anti-CD8) stained only a few scattered cells in LFV. In contrast, $CD8^{+}$ cells predominated in the epithelium of LFV and in the epithelium of adjacent classical villi (Fig 3.7).

To determine whether the Ig^{-} TCR^{-} lymphoid cells in the LFV might be natural killer cells, sections of LFV from C56Bl/6 mice were stained with mAb P136 (anti-NK1.1). Lymphocytes in LFV were $NK1.1^{-}$, but scattered cells in the lamina propria of adjacent villi were labelled by mAb P136 (Fig 3.8). The lymphocytes in the LFV were negative for the antigen Mac-1 (CD11b), which is expressed by NK cells (see 3.2.5.1).

3.2.5 Characterization of Large and Irregular Cells in LFV

3.2.5.1 Single-colour immunohistochemistry

To examine the nature of large non-lymphoid Thy-1^{+}, $CD45^{+}$ cells that were present within LFV, particularly beneath the epithelium, sections were stained with mAb

Figure 3.5

Frozen sections from the jejunum of a normal Balb/c mouse, stained with monoclonal antibodies by the indirect immunoperoxidase technique. **a**- monoclonal antibody TIB-122 (anti-CD45), shows that most cells in LFV are $CD45^{+}$. **b**- monoclonal antibody TIB-107 (anti-Thy-1.2), shows that many cells in LFV express Thy-1. Original magnification x 83.

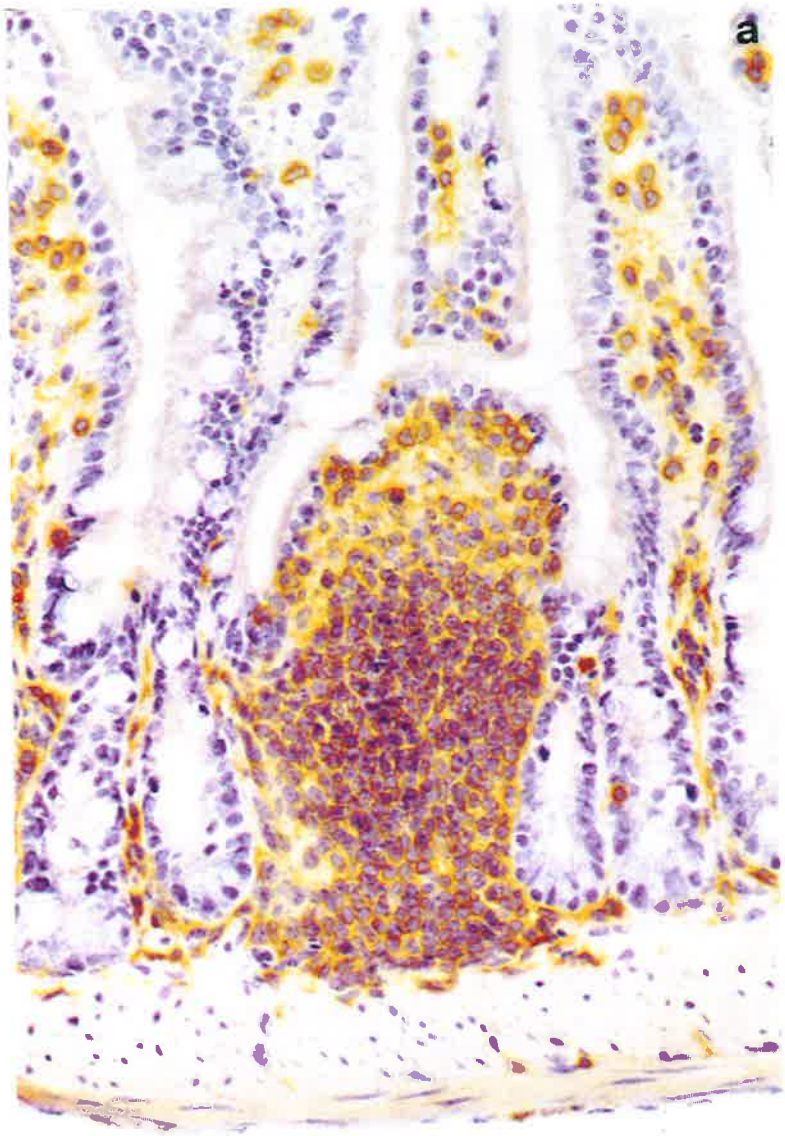
a

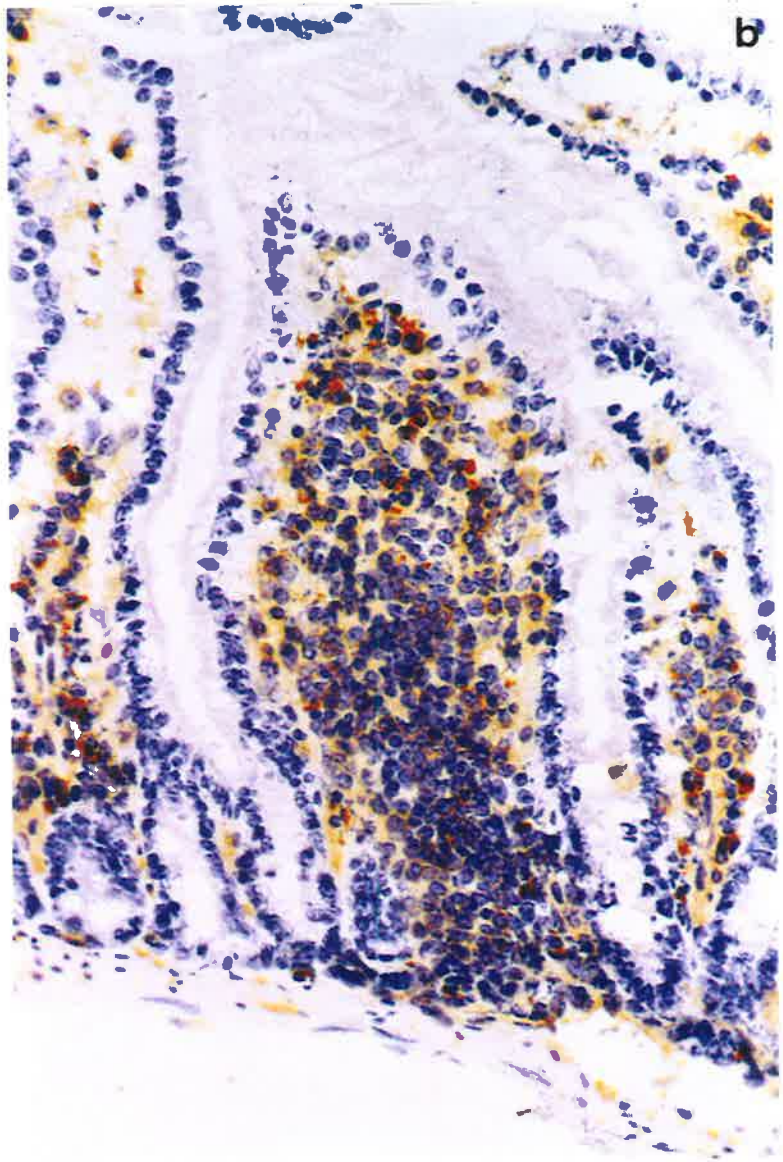
b

Figure 3.6

Expression of mature T cell markers (CD3, αβ TCR, γδ TCR) by lymphocytes in LFV from the jejunum of a normal Balb/c mouse, detected by the indirect immunoperoxidase technique. **a**- staining with mAb 145-2C11 (anti-CD3) shows very few $CD3^+$ cells in the LFV but many $CD3^+$ cells within the epithelium of the LFV and the epithelium of adjacent villi. **b**- staining with mAb H57-597 (anti-TCR α/β) shows scattered αβ TCR^+ cells in LFV. **c**- staining with mAb GL3 1A (anti-TCR γ/δ). No γδ TCR^+ cells were detected within the LFV, but scattered positive IEL are present in the overlying epithelium of both LFV and classical villi (arrows). Original magnification x 83.

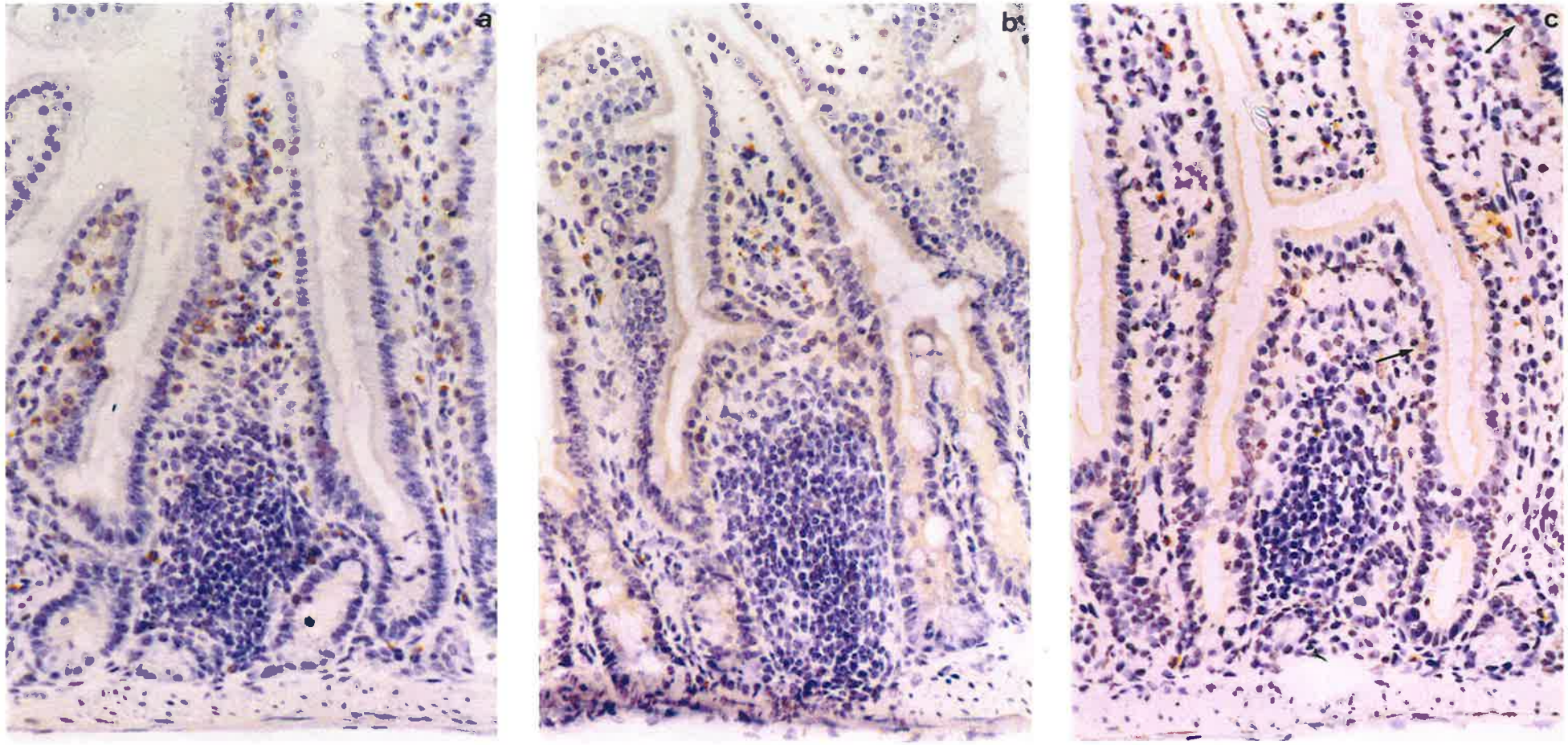
a
b
c

Figure 3.7

Frozen sections from jejunum in normal Balb/c mice were stained with monoclonal antibodies by the indirect immunoperoxidase technique. **a**- LFV, showing a sub-population of lymphocytes that are stained with monoclonal antibody TIB 207 (anti-CD4). **b**- LFV stained with monoclonal antibody YTS 169.4 (anti-CD8). Note the $CD8^+$ IEL in the epithelium of the LFV and classical villi. A small number of lymphocytes in the LFV express CD8. Original magnification x 83.

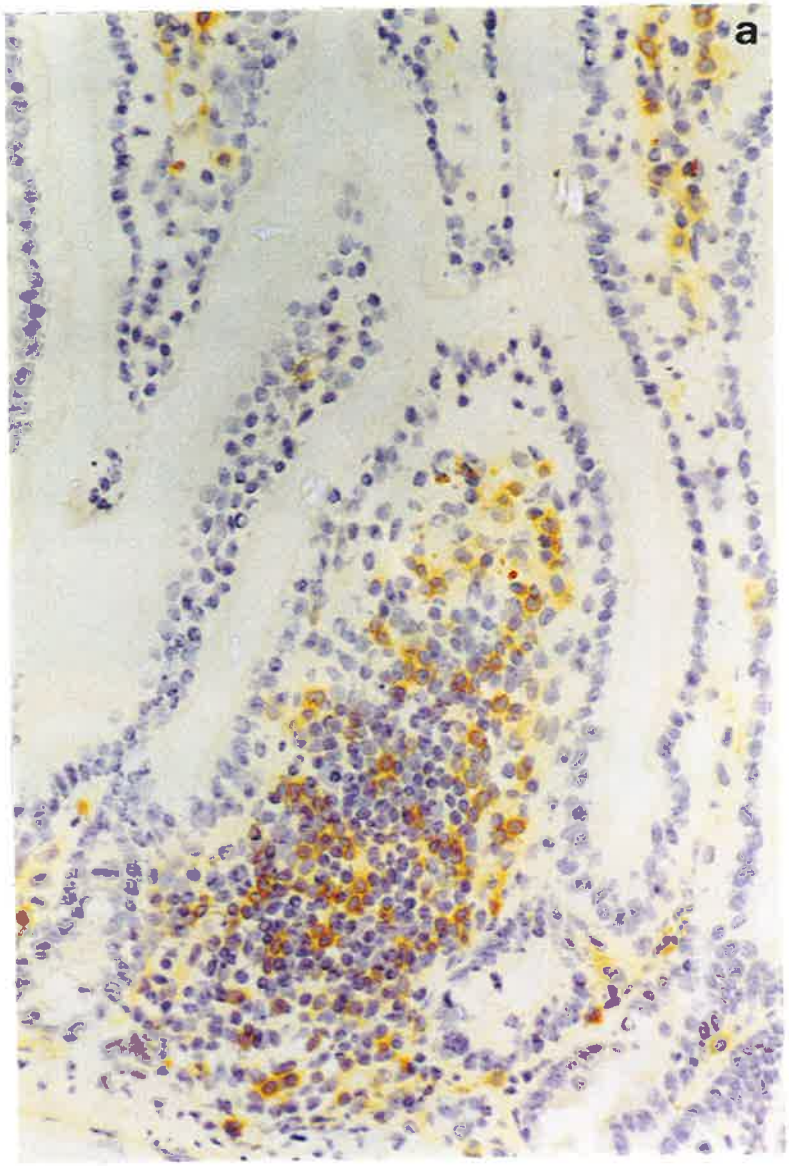
a

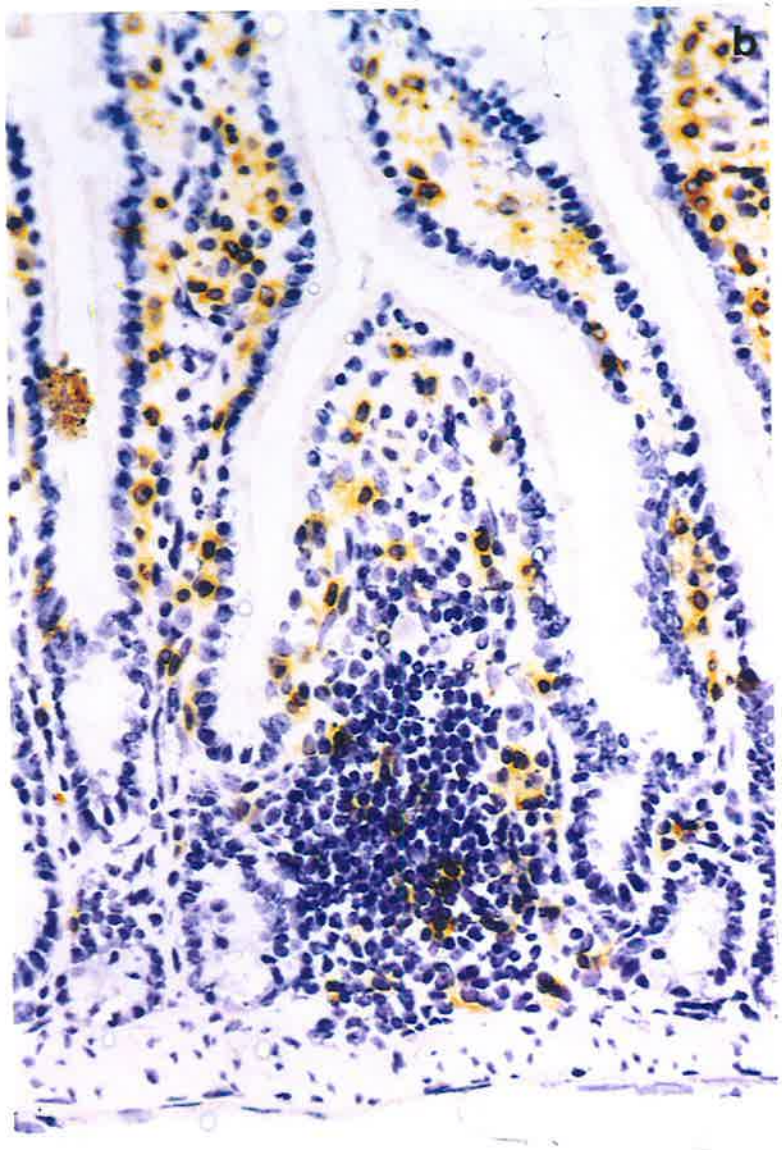
b

Figure 3.8

Frozen section of jejunum from a normal C57Bl/6 mice, stained with monoclonal antibody P136 (anti-NK 1.1) by the indirect immunoperoxidase technique. Only one cell was stained in the LFV (arrow) and scattered positive cells are present in adjacent villi. Original magnification x 83.

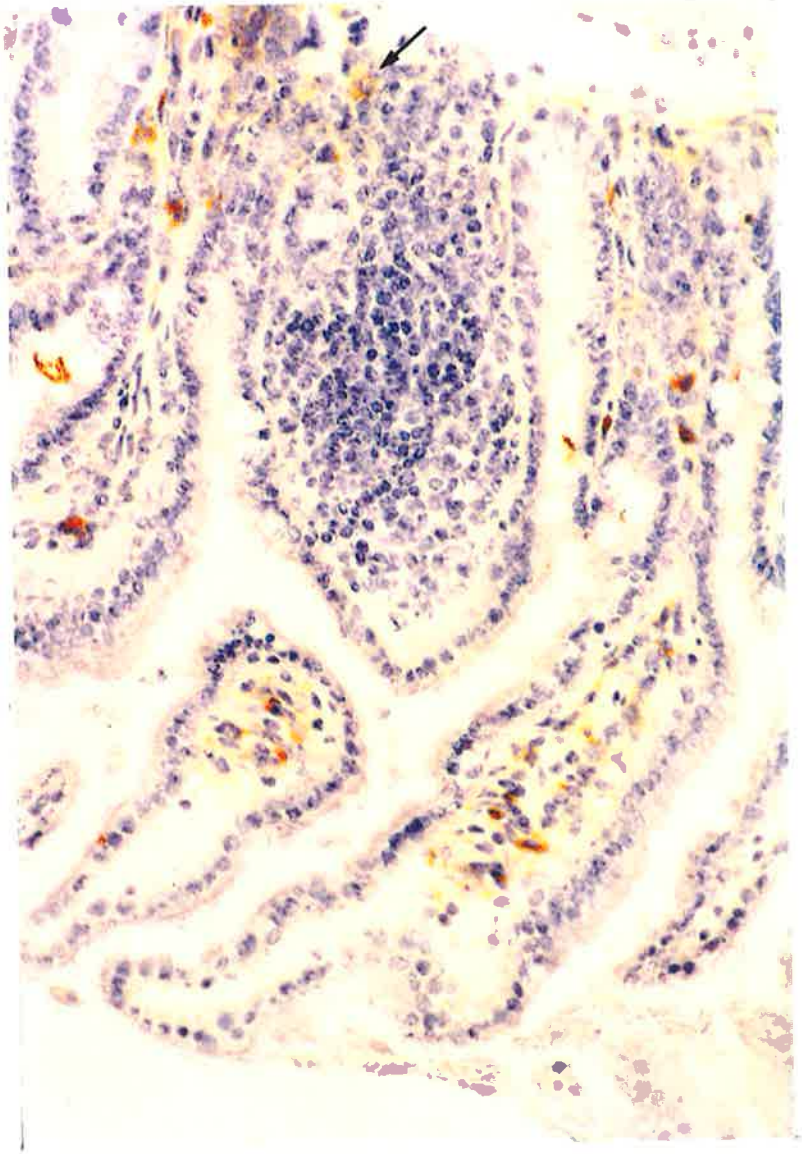

MK-D6 (anti-MHC-II). Most of the cells in the subepithelial areas within the lamina propria of LFV expressed MHC class II molecules (Fig 3.9a). MHC class II-positive cells were also present between the lymphocytes in the cores and bases of LFV. Moreover, the epithelial cells overlying the LFV and the adjacent villi expressed MHC class II molecules (Fig 3.9a). The vast majority of the MHC class II-positive cells in the lamina propria of LFV were not stained by mAbs M1/70 (anti-Mac-1 or CD11b) or F4/80 and are not, therefore, believed to be macrophages. Discrete cells that expressed CD11b or F4/80 antigen were present in classical villi (Fig 3.9c,d).

To further characterise the Thy-1$^+$, MHC-II$^+$, CD11b$^-$, F4/80$^-$ large cells in LFV, sections were stained with mAb N418 (anti-CD11c). Most of the large cells beneath the epithelium in LFV expressed CD11c (Fig 3.9b). Scattered positive cells were also present between the lymphocytes in the cores and bases of the LFV. In addition, scattered cells in adjacent villi were labelled with N418 mAb (Fig 3.9b). The pattern of cells stained with mAb N418 was similar to the distribution of MHC class II-positive cells (Fig 3.9a). Monoclonal antibody N418 stained a dense layer of cells in the subepithelial dome of PP and scattered cells in interfollicular regions, as described by Kelsall & Strober (1996).

3.2.5.2 Histochemical analysis of acid phosphatase and non-specific esterase activities in the LFV

The large MHC II$^+$ CD11C$^+$ cells beneath the epithelium of LFV were investigated further by histochemical detection of the lysosomal enzymes acid phosphatase and non-specific esterase. Weak acid phosphatase activity was observed in some cells beneath the epithelium, particularly at the tips of LFV. Scattered cells with weak non-specific esterase activity were detected in the same areas. However, most MHC II$^+$, CD11c$^+$ cells in the subepithelial areas within the lamina propria of LFV are unlikely

Figure 3.9

Frozen sections of jejunum from normal Balb/c mice were stained with monoclonal antibodies by the indirect immunoperoxidase technique. **a**- section stained with monoclonal antibody MK-D6 (anti-MHC-II). **b**- serial section to "a", stained with monocloal antibody N418 (anti-CD11c). Note the similar distribution of MHC class II and CD11c within the LFV. **c**- section stained with monoclonal antibody M1/70 (anti-CD11b). **d**- section stained with monoclonal antibody F4/80. Original magnification x 83.

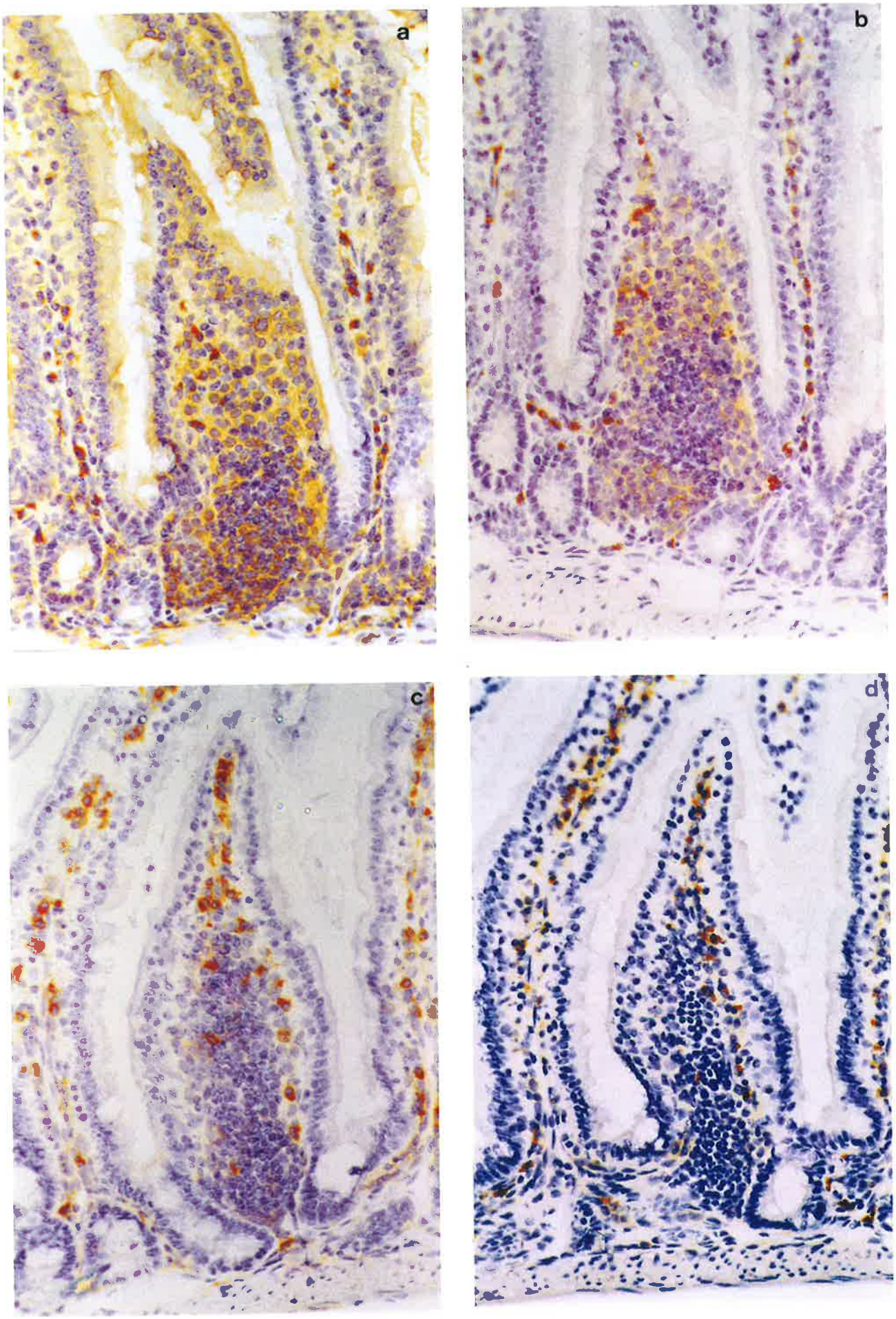
a
b
c
d

to be macrophages. The epithelial cells overlying the LFV and adjacent villi were intensely acid phosphatase and esterase positive (Fig 3.10).

On the basis of these investigations using immunoperoxidase and enzyme histochemistry techniques, it appears most likely that the large and irregular cells in the LFV are dendritic cells.

3.2.6 Comparison between the Antigens Expressed by Cells in the LFV, Bone Marrow Haematopoietic Stem Cells and Thymocytes

The primary observations of the cells in the LFV showed that these novel lymphoid aggregates contain an unusual population of lymphocytes that do not express mature T cell markers, B cell markers or NK cell markers. Because the expression of differentiation antigens by T cells in the process of intrathytmic development is well documented (Fowlkes & Pardoll, 1989), it was of interest to examine whether the lymphoid cells in LFV have similarities with immature thymocytes. Therefore, a more detailed phenotype was carried out.

3.2.6.1 Expression of CD25

Studies on the expression of CD25 during thymocyte ontogeny in normal mice has indicated that this molecule is expressed by a substantial subpopulation of $CD3^-$ 4^- 8^- cells in the fetal and adult thymus (Ceredig *et al.*, 1985; Raulet, 1985; Wilson *et al.*, 1994a). The majority of lymphoid cells in the bases of LFV showed reactivity with mAb PC-61 (anti-CD25) (Fig 3.11). The $CD25^+$ cells were limited to the LFV, while IEL and lymphocytes in the lamina propria of adjacent villi were unstained by this antibody. In this respect, cells in LFV that on numerical grounds must be $CD3^-CD4^-CD8^-$, are similar to immature thymocytes.

Figure 3.10

Photomicrographs of frozen sections of paraformaldehyde-fixed jejunum from a normal Balb/c mouse. **a**- section of an LFV stained by the Azo-dye method to show acid phospatase activity (red). **b**- section of an LFV stained by the α naphtyl acetate method to demonstrate non-specific esterase activity (reddish brown). Sections were counterstained with methy-green. Original magnification, a x 83, b x 165.

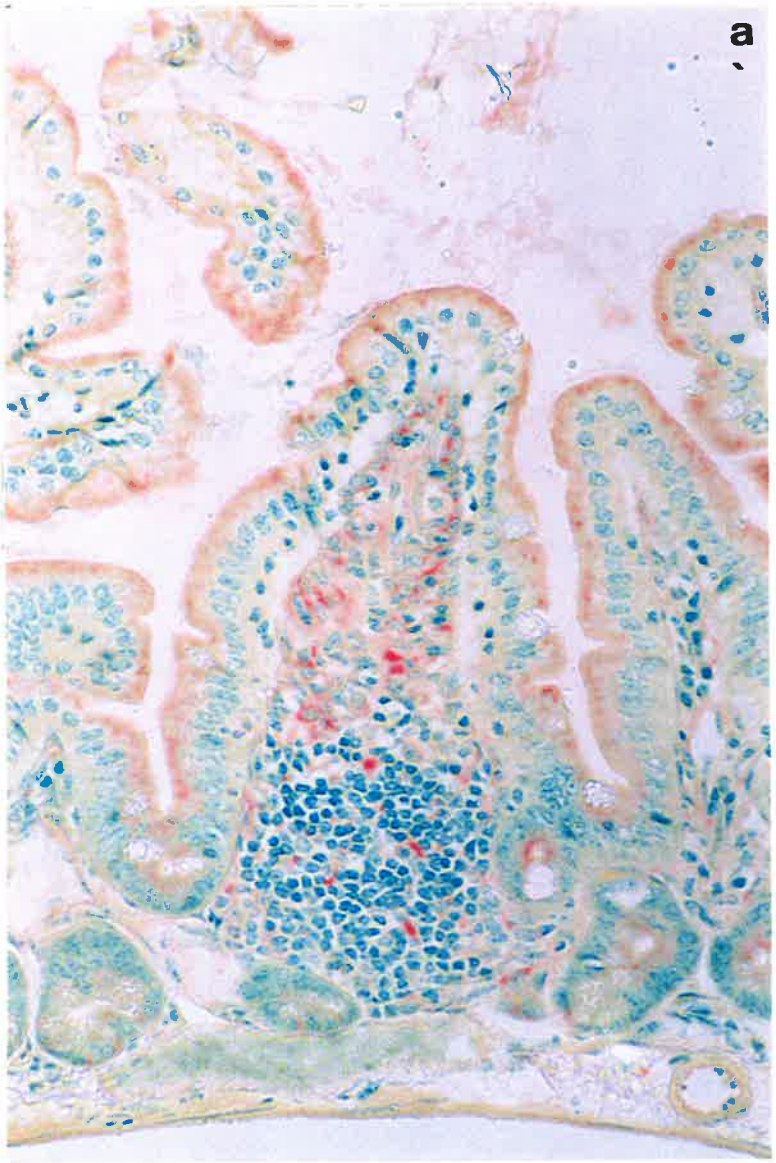
a

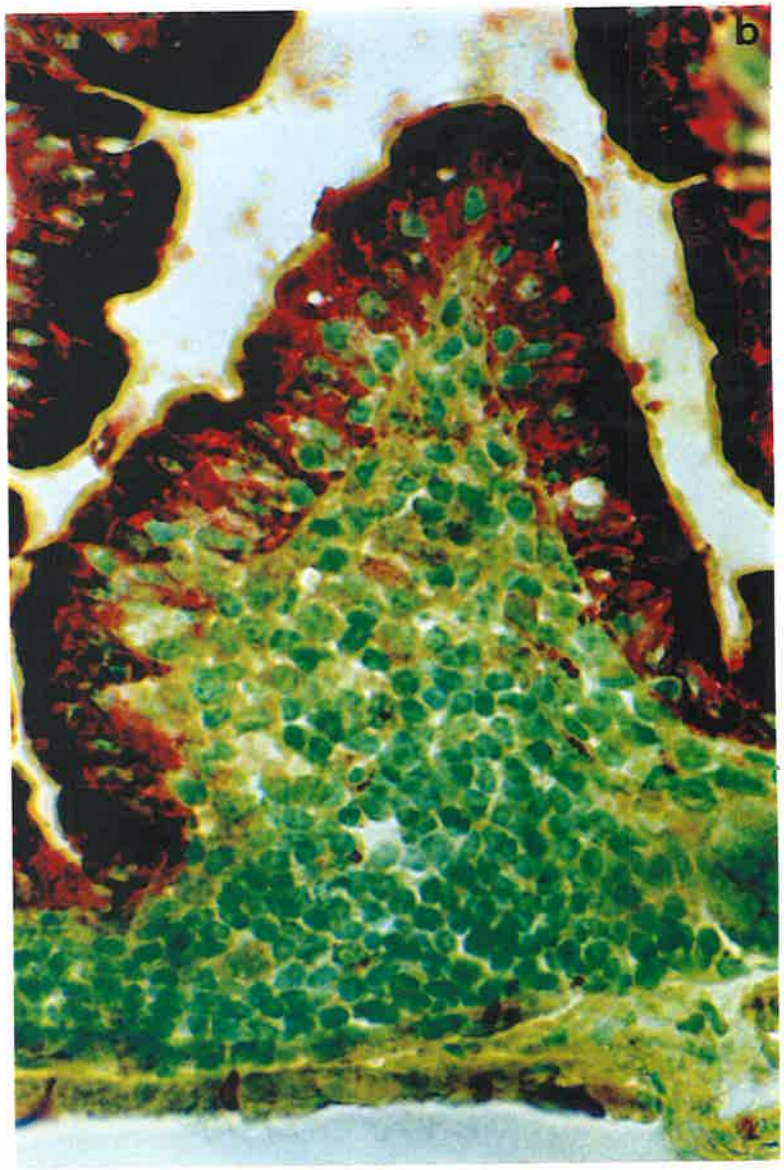
b

Figure 3.11

Frozen section of jejunum from a normal Balb/c mouse, stained with monoclonal antibody PC-61 (anti-CD25) by the indirect immunoperoxidase technique. Many CD25 positive cells are present in the center and base of the LFV. Original magnification x 83.

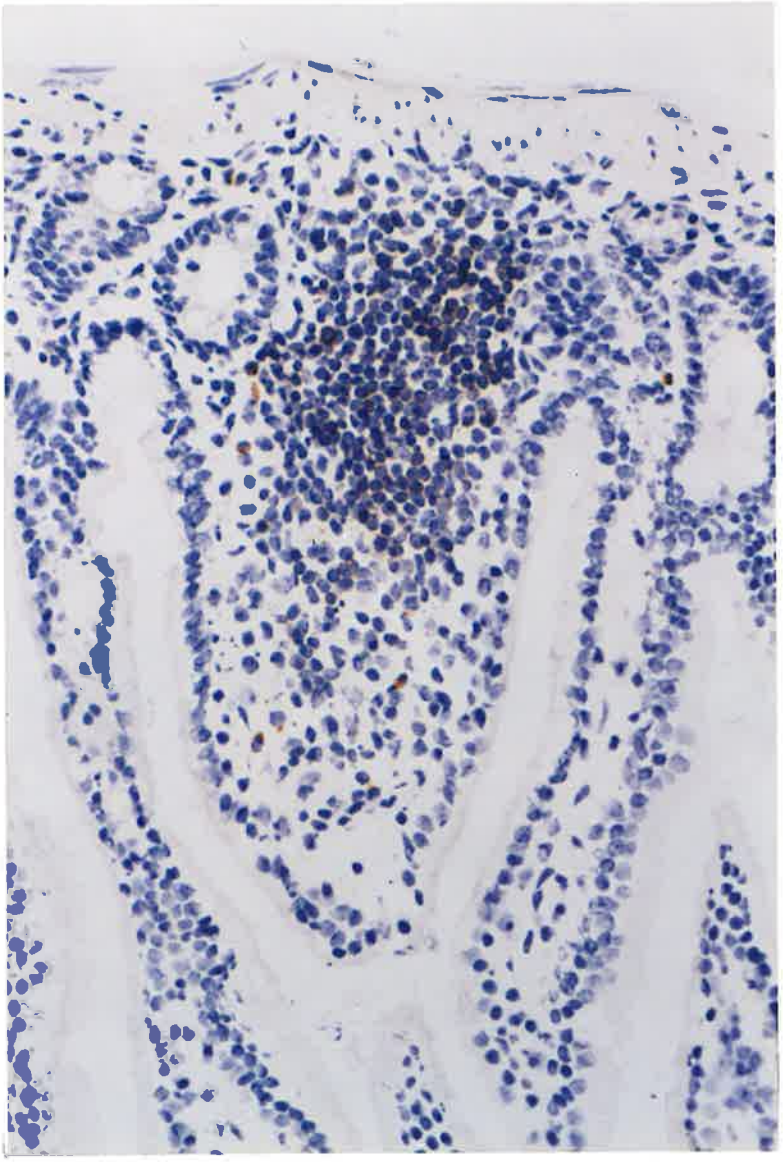

3.2.6.2 Expression of stem cell antigen 2 (Sca-2)

To assess the possibility that the cells in LFV share surface antigens with bone marrow-derived haematopoietic stem cells or early thymocytes, sections of thymus and LFV were stained with mAbs against the antigens stem cell antigen 1 (Sca-1), stem cell antigen 2 (Sca-2), thymic shared antigen 1 (TSA-1), heat stable antigen (HSA), Pgp-1 (CD44) and TSA-2 (MTS-32), and with mAbs MTS-33 and MTS-37. This was accomplished by the use of either indirect immunoperoxidase (mAbs E13 161-7, M1/69, IM7.8.1, MTS-33, MTS-37) or by indirect immunofluorescence (mAbs E3 81-204, MTS-35, MTS-32) as detailed in the Figure legends.

Stem cell antigen 2 is a marker expressed by subsets of bone marrow cells that home to and repopulate the thymus (Spangrude *et al.*, 1989). In confirmation of the observations of Spangrude *et al.*(1988b), expression of Sca-2 (mAb E3 81-204) was limited to the cortical thymocytes and in particular, to those located in the subcapsular region (Fig 3.12a). In contrast, in LFV the vast majority of cells reacted with mAb E3 81-204 (Fig 3.13a). The Sca-2 antigen was also present abundantly in the lamina propria of adjacent villi. The nature of the cells that express Sca-2 in the lamina propria were not further characterized but they could include B cells and dendritic cells (Tucek *et al.*, 1992; Vremec *et al.*, 1992). In addition, a few positive cells were detected in the epithelial compartment. Thymic shared antigen 1 is identical to Sca-2 (Saitoh *et al.*, 1995) and the patterns of cells stained with mAb MTS-35 both in thymus (Fig 3.12b) and LFV (Fig 3.13b) were similar to those produced by mAb E3 81-204. However, mAb MTS-35 also stained epithelial cells in the crypt area of the mucosa (Fig 3.13b).

3.2.6.3 Expression of stem cell antigen 1 (Sca-1)

Although Sca-1 and Sca-2 are both markers of haematopoietic stem cells (Spangrude *et al.*, 1988a, Spangrude *et al.*, 1989), in the thymus they are expressed by

Figure 3.12

Frozen sections from the thymus of a normal Balb/c mouse, stained with monoclonal antibodies by the indirect immunoperoxidase technique. **a**- monoclonal antibody E3 81-204 (anti-Sca-2). **b**- monoclonal antibody MTS 35 (anti-TSA-1). In both cases, labelled thymocytes are confined to the cortex, particularly beneath the capsule. Scattered epithelial cells are stained in the cortex and medulla. Original magnification x 83.

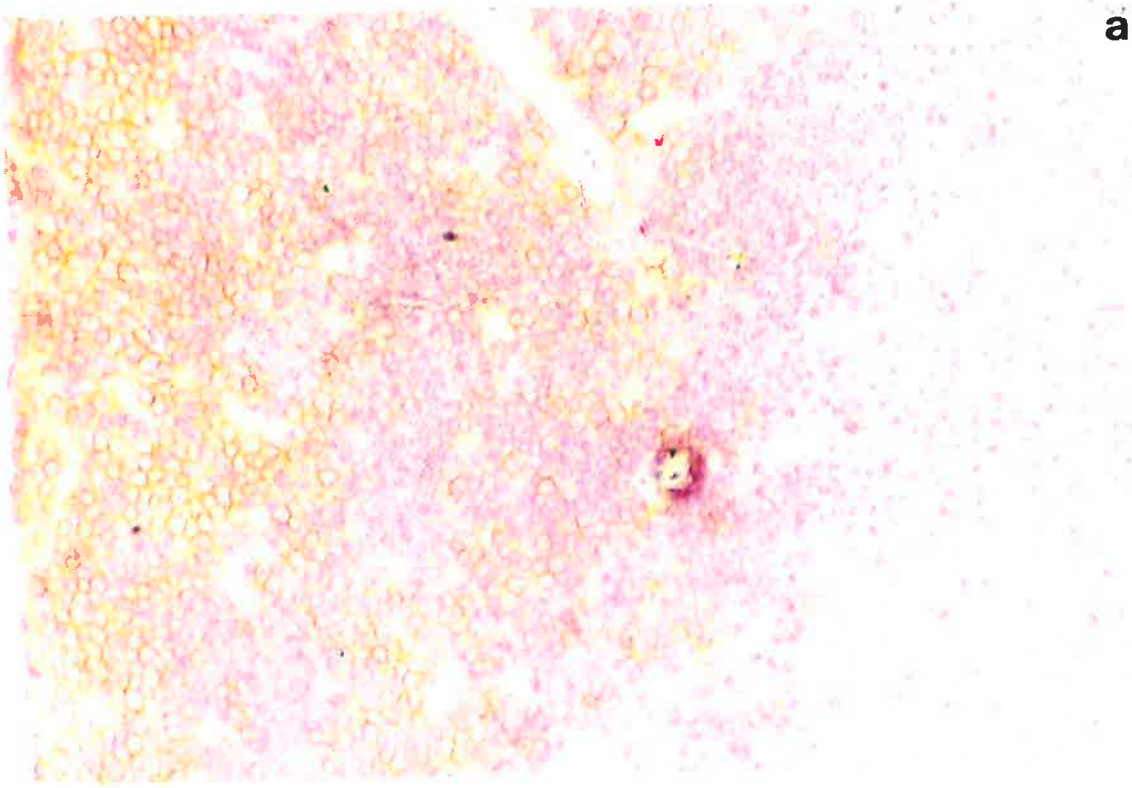
a

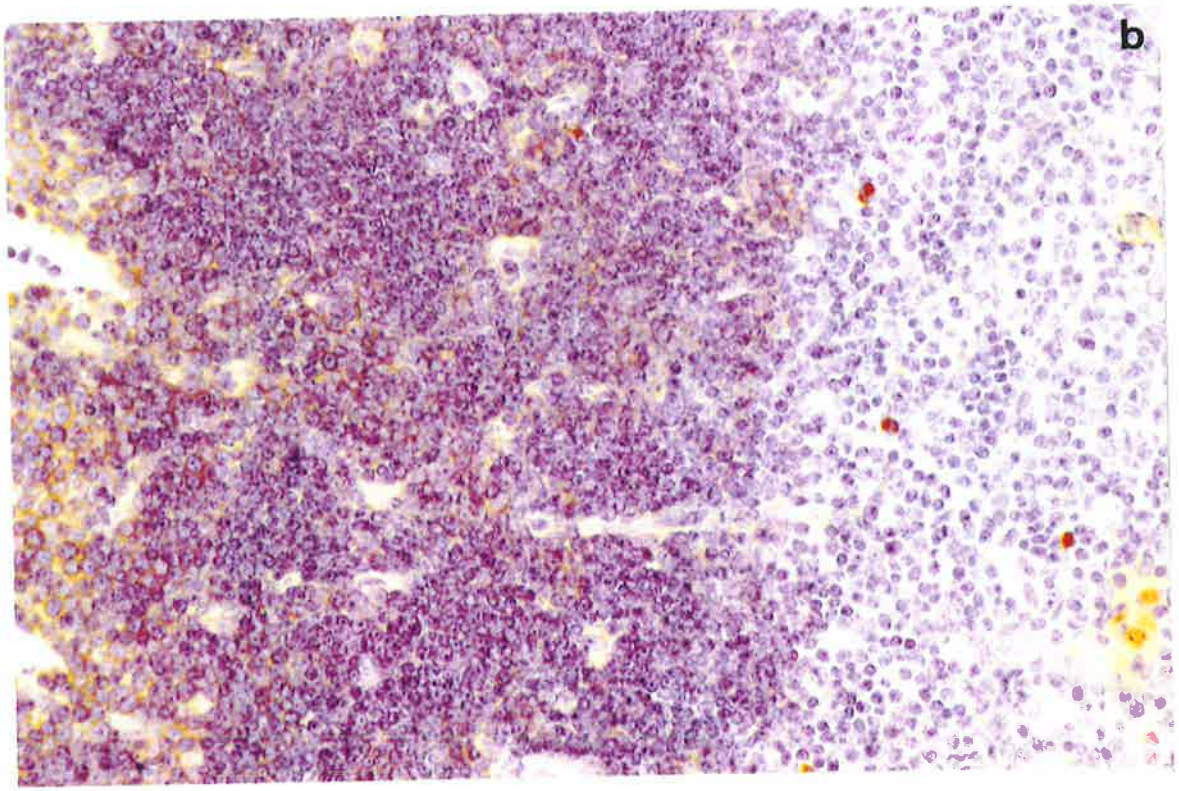
b

Figure 3.13

Frozen sections of jejunum from a normal C57Bl/6 mice, stained with monoclonal antibodies by the indirect immunofluorescence technique. **a-** section stained with mAb E3 81-204 (anti-Sca-2) (over-exposed during photography). **b-** section stained with mAb MTS 35 (anti-TSA-1/ Sca-2). Original magnification x 83.

a

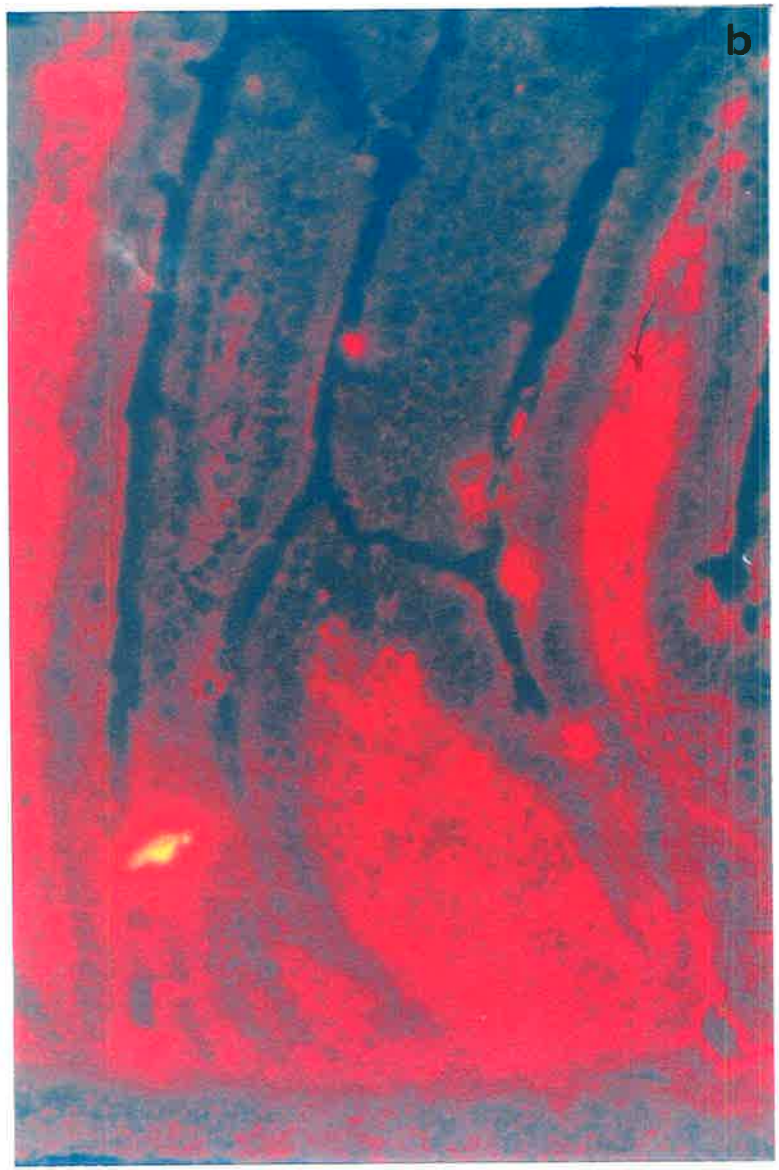
b

separate populations of thymocytes. Monoclonal antibody E13 161-7 (Sca-1) stained the medullary region, including both thymocytes and stromal elements (not shown). In the cortex, as noted previously by Spangrude *et al.*(1988b), scattered thymocytes and connective tissue were labelled by mAb E13 161-7 (not shown). Expression of Sca-1 in LFV was limited to the blood vessels and scattered cells beneath the epithelium (Fig 3.14a).

3.2.6.4 Expression of heat stable antigen (HSA)

Heat stable antigen is an early thymocyte marker (Wu *et al.*, 1991b). Monoclonal antibody M1/69 (anti-HSA) stained the thymocytes in the cortex of the thymus, particularly in the subcapsular region. In the medulla, the expression of HSA was limited mainly to the stromal cells and it was expressed by only scattered thymocytes (not shown). In LFV, most of the lymphocytes were labelled by mAb M1/69 but there were small clusters of unstained cells, particularly in the center and at the base of the LFV. The antibody stained many cells in the lamina propria of adjacent villi and also scattered cells in the epithelium (Fig 3.14b). Because HSA is expressed during the initial stages of T cell development (Scollay *et al.*, 1984; Crispe & Bevan, 1987; Crispe *et al.*, 1987; Nikolic-Zugic, 1991), and by a subset of IEL with phenotypic properties of immature T cells (Stickney *et al.*, 1994), the expression of this antigen by lymphocytes in LFV supports the hypothesis that these structures may contain immature cells of the T cell lineage.

3.2.6.5 Expression of Pgp-1 antigen (CD44)

Pgp-1 (CD44) is expressed by thymic progenitors of T lymphocytes (Hyman *et al.,* 1986) and by bone marrow stem cells (Trowbridge *et al.,* 1982). Staining by mAb IM7.8.1 (anti-Pgp-1) in the thymus medulla was limited mainly to the stromal cells and to isolated thymocytes. Small clusters of thymocytes and connective tissue were stained by this mAb (anti-Pgp-1) in the thymic cortex (not shown). In LFV, most lymphocytes

Figure 3.14

Frozen sections of jejunum from normal Balb/c mice, stained with monoclonal antibodies by the indirect immunoperoxidase technique. **a**- section stained with mAb E13 161-7 (anti-Sca-1). **b**- section stained with mAb M1/69 (anti-HSA). **c**- section stained with mAb IM 7.8.1 (anti-Pgp-1). Original magnification x 83.

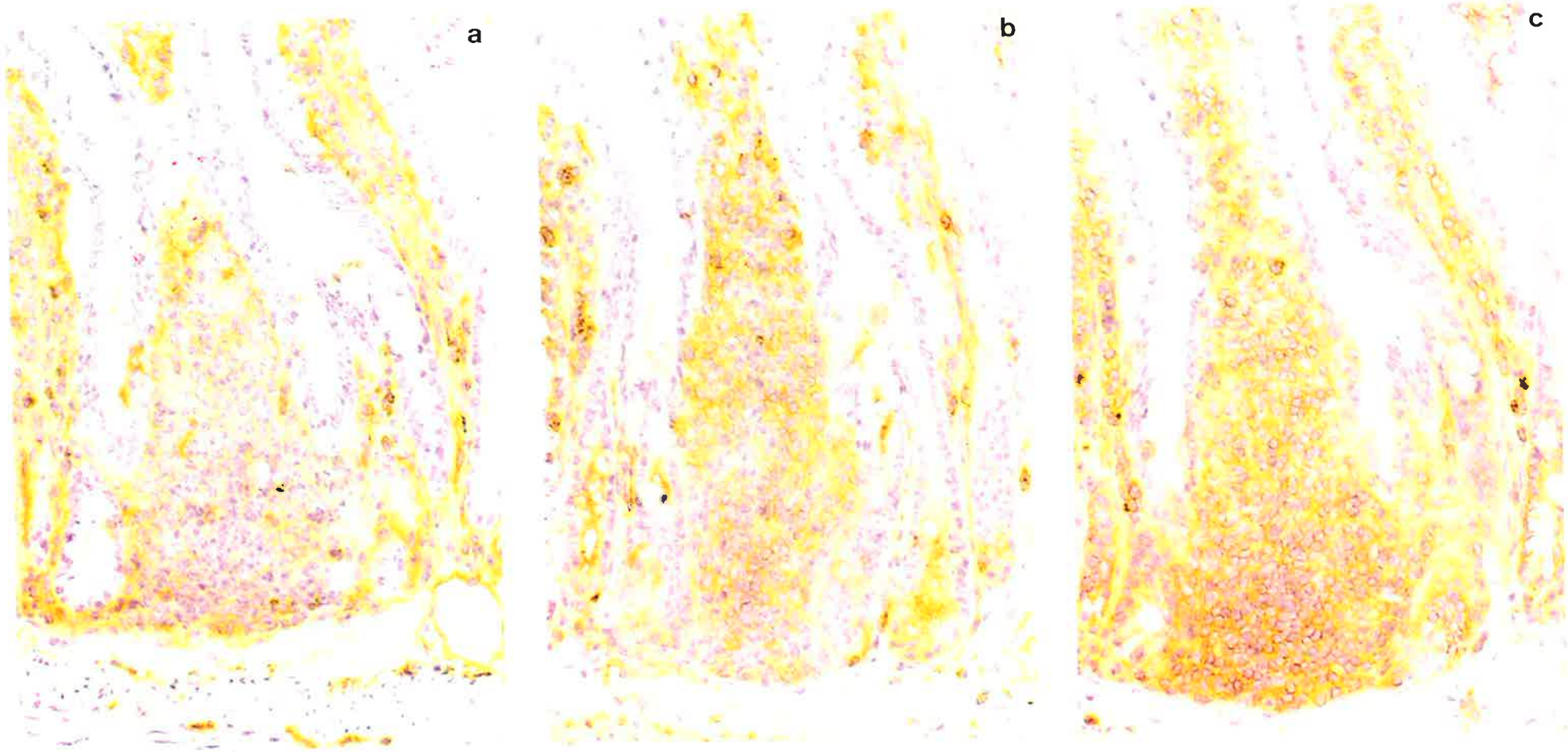
a
b
c

expressed Pgp-1 but there were scattered unstained cells between the positive cells in the core and the base of the LFV. The positive cells were also present in classical villi. Scattered Pgp-1 positive IEL were detected in the epithelium of both LFV and classical villi (Fig 3.14c).

3.2.6.6 Expression of antigens detected by the MTS panel of monoclonal antibodies

Dr Richard Boyd (Monash University) has raised a large panel of monoclonal antibodies against mouse thymic stromal (MTS) cells. Some of these mAb have demonstrated antigens that are shared between thymocytes and thymic stromal cells. These include mAbs MTS 32, MTS 33, MTS 35 and MTS 37 (Godfrey *et al.*, 1990). Monoclonal antibodies MTS 33, MTS 35 and MTS 37 also react with peripheral B cells but they do not recognize peripheral T cells (Tucek *et al.,* 1992). In contrast, mAb MTS 32 does not recognize B cells but it does recognize an antigen expressed by peripheral T cells (Tucek *et al.,* 1992).

In the thymus, mAb MTS 32 stained epithelial cells in both the cortex and the medulla and it stained most of the cortical thymocytes (Fig 3.15a). This distribution has been reported previously (Godfrey *et al.*, 1990). In LFV, mAb MTS 32 stained a population of cells in the centers and at the bases of these structures. Labelled cells were also present in the lamina propria of adjacent villi and were scattered in the epithelial compartment (Fig 3.16a). The positive cells in lamina propria of normal C57Bl/6 mice were probably mature T cells, as mAb MTS 32 is known to stain peripheral $CD4^+$ T cells (Tucek *et al.*, 1992). The expression of the MTS 32 antigen on the cells in LFV will be described in more detail in Chapter 5.

Most thymocytes (85-90%) are stained by mAb MTS 33 (Godfrey *et al.*, 1990). This mAb stained the cortical thymocytes and cortical epithelium and also small

Figure 3.15

Frozen sections from the thymus of a normal Balb/c mouse, stained with monoclonal antibodies by the indirect immunoperoxidase technique. **a**- section stained with mAb MTS 32 (anti-TSA-2). **b**- section stained with mAb MTS 33. **c**- section stained with mAb MTS 37. Original magnification x 83.

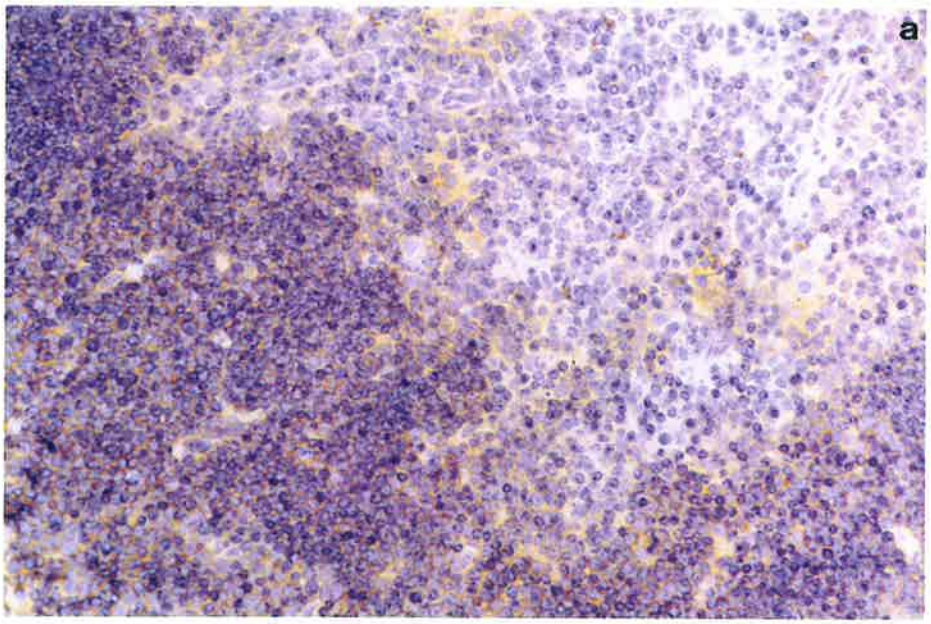
a

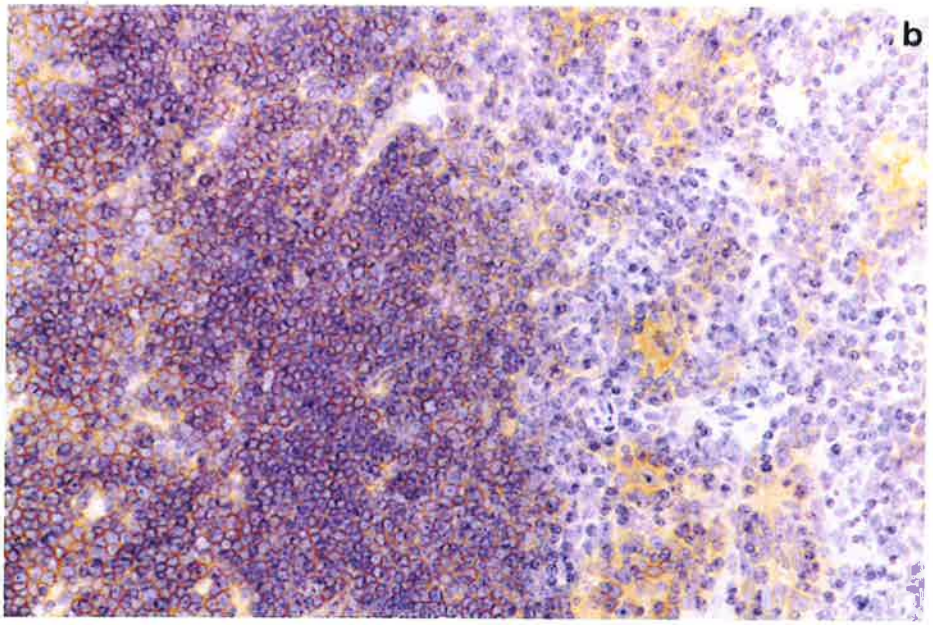
b

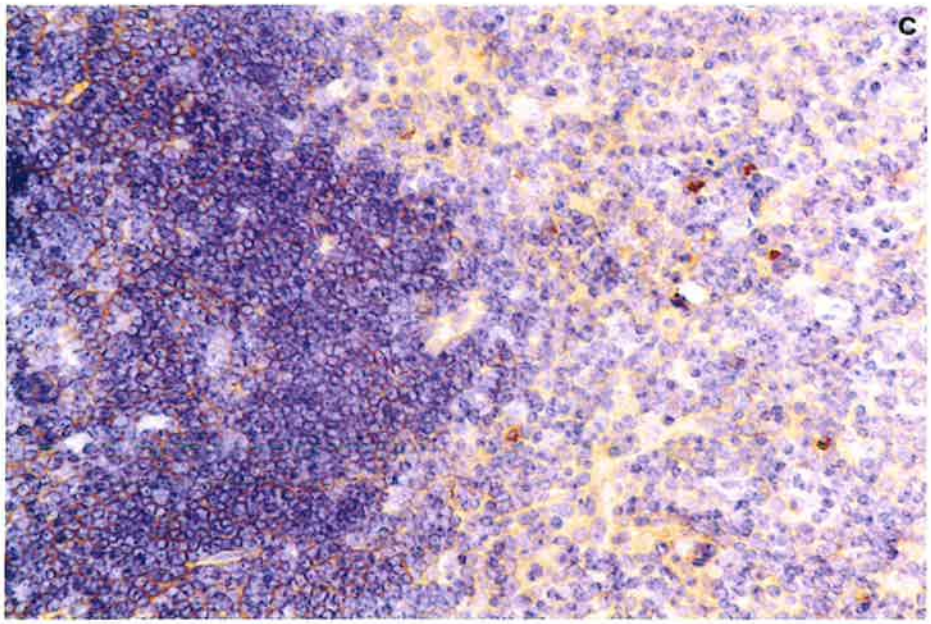
c

Figure 3.16

Photomicrographs of frozen sections of LFV from normal mice. **a**- section (from a C57Bl/6 mouse) stained with mAb MTS 32 (indirect immunofluorescence technique). **b**, **c**- sections (from Balb/c mice) stained with mAbs MTS 33 and MTS 37 respectively (indirect immunoperoxidase technique). Original magnification x 83.

a

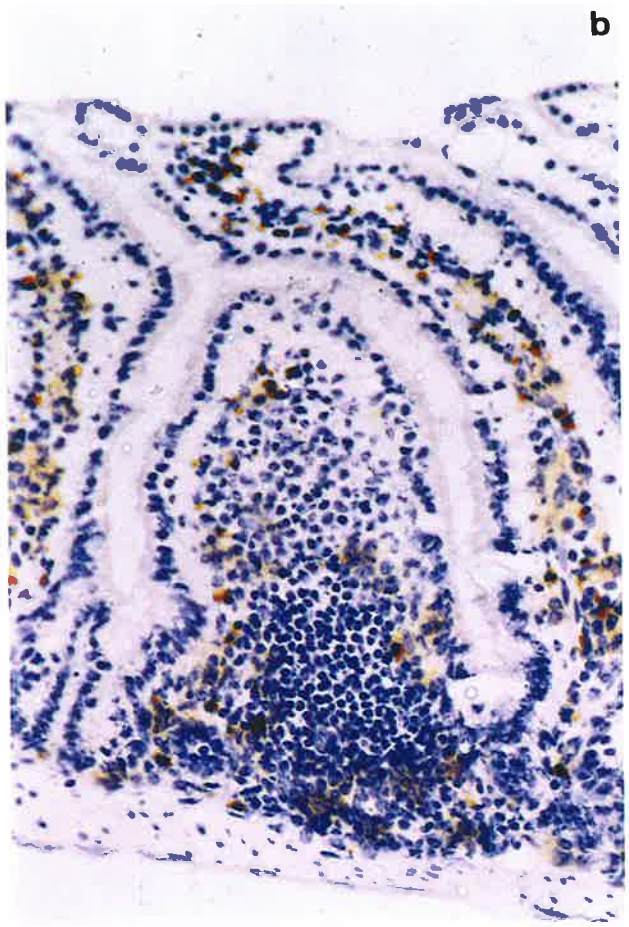
b

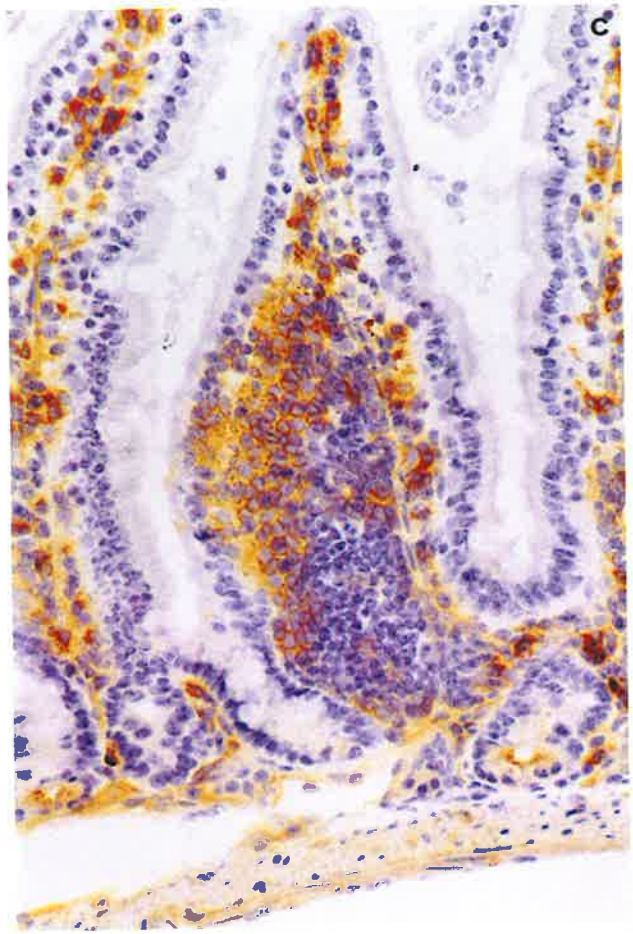
c

clusters of medullary epithelial cells (Fig 3.15b). In LFV, some large and irregular cells at the bases and in the subepithelial areas were labelled by this mAb but most of the cells in the center of LFV were not stained (Fig 3.16b). Scattered cells in the lamina propria of classical villi were stained, as were a few IEL.

Monoclonal antibody MTS 37 is another antibody that recognizes an antigen shared by thymic stromal cells and thymocytes (Godfrey *et al.,* 1990). Flow cytometric analysis has demonstrated that more than 95% of thymocytes express this antigen (Godfrey *et al.,* 1990). Frozen sections of thymus which were stained by the immunoperoxidase technique showed that mAb MTS37 stained many cortical thymocytes. It also stained epithelium in both the cortex and the medulla (Fig 3.15c). In the LFV, mAb MTS 37 identified two types of cells. One of these was non-lymphoid and they were located mainly beneath the epithelium. The second was a population of lymphocytes located among these cells in the sub-epithelial region of the tip and lateral margins of the LFV. The major population of lymphocytes in the centers and bases of LFV did not react with this mAb. Monoclonal antibody MTS 37 also stained some of the cells in adjacent villi (Fig 3.16c). The positive cells in the classical villi may include B-cells (Tucek *et al.*, 1992), although many have a distribution and morphology similar to the MHC II^+ cells described as dendritic cells in the rat (Mayrhofer *et al.*, 1983). The staining pattern of mAb MTS 35 (anti-TSA-1; anti-Sca-2) has been described above (3.2.6.2).

3.2.7 Expression of Thymic Stromal Antigens by the Non-lymphoid Cells in LFV

To further investigate the non-lymphoid cells in LFV and their possible relationships to stromal cells in thymus, a further range of mAb against thymic stromal cell antigens was tested. These included mAbs MTS 1, MTS 9, MTS 10, MTS 20, MTS

24 and MTS 44. These mAbs recognize different sub-populations of epithelial cells in the thymus (Kampinga *et al.,* 1989; Godfrey *et al.*, 1990).

Monoclonal antibody MTS 20 stained large cells, particularly beneath the epithelium of the LFV (Fig 3.17a). Rare cells in the lamina propria and in the epithelium of adjacent villi were labelled. In addition, the antibody stained epithelial cells overlying the LFV and adjacent villi weakly. Monoclonal antibody MTS 24 labelled the majority of cells in the subepithelial areas within the lamina propria of LFV. This mAb appeared to recognized two types of cells - large non-lymphoid cells and also lymphocytes among these cells. Most of the lymphocytes at the bases of the LFV were negative (Fig 3.17b). Scattered cells in adjacent villi and rare IEL were also labelled with this mAb.

The other monoclonal antibodies that recognize thymic epithelial cells, including mAb MTS 1, reacted with scattered large cells in LFV (not shown). In addition, mAb MTS 9 stained epithelial cells in the crypts (Fig 3.17d). Monoclonal antibodies MTS 10 and MTS 44 stained epithelial cells of both LFV and classical villi (Figs 3.17c and 3.17e). Lymphocytes in LFV and in the lamina propria and epithelial compartments of classical villi did not stain with mAbs MTS 9, MTS 10 and MTS 44 (Fig 3.17c-e).

3.2.8 Expression of Some T cell Markers by Dendritic Cells in LFV and Comparison with Thymic Dendritic Cells by Dual-colour Immunofluorescence Staining

Thymic dendritic cells express a number of surface markers usually associated with T cells (Vremec *et al.,* 1992). To determine whether the dendritic cells in LFV are similar to those in the thymus, dual immunofluorescence (IF) staining was carried out in RAG-1 gene knockout mice using combinations of mAbs that recognize the following determinants; Thy1/CD11c; CD45/CD11c; CD4/CD11c; CD8/CD11c; Sca-

Figure 3.17

Photomicrographs of frozen sections through LFV from normal Balb/c mice. **a**- section stained with mAb MTS 20. **b**- section stained with mAb MTS 24. **c**- section stained with mAb MTS 10. **d**- section stained with mAb MTS 9. **e**- section stained with mAb MTS 44. (a-c, indirect immunoperoxidase; d-e, indirect immunofluorescence staining). Original magnification x 83.

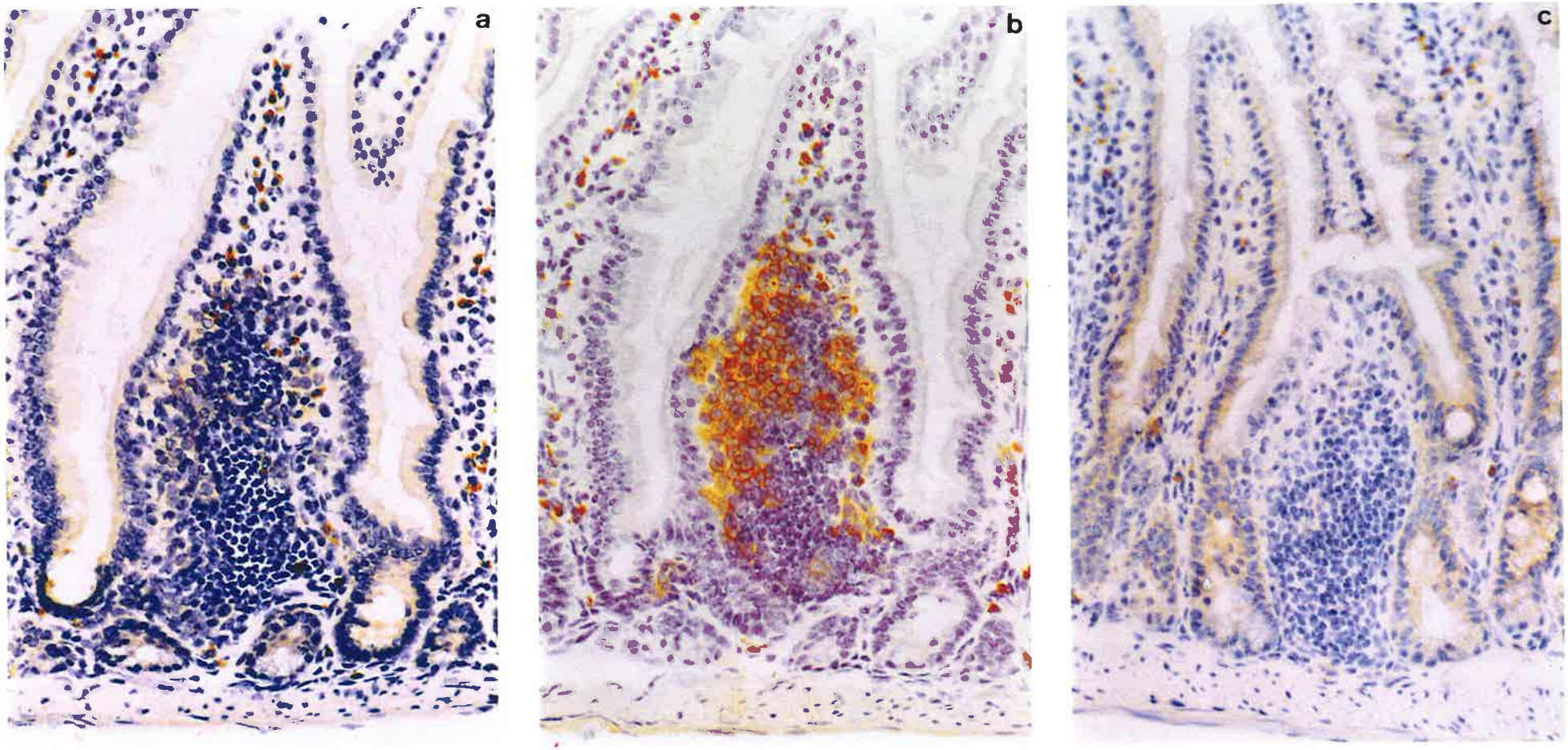
a
b
c

d

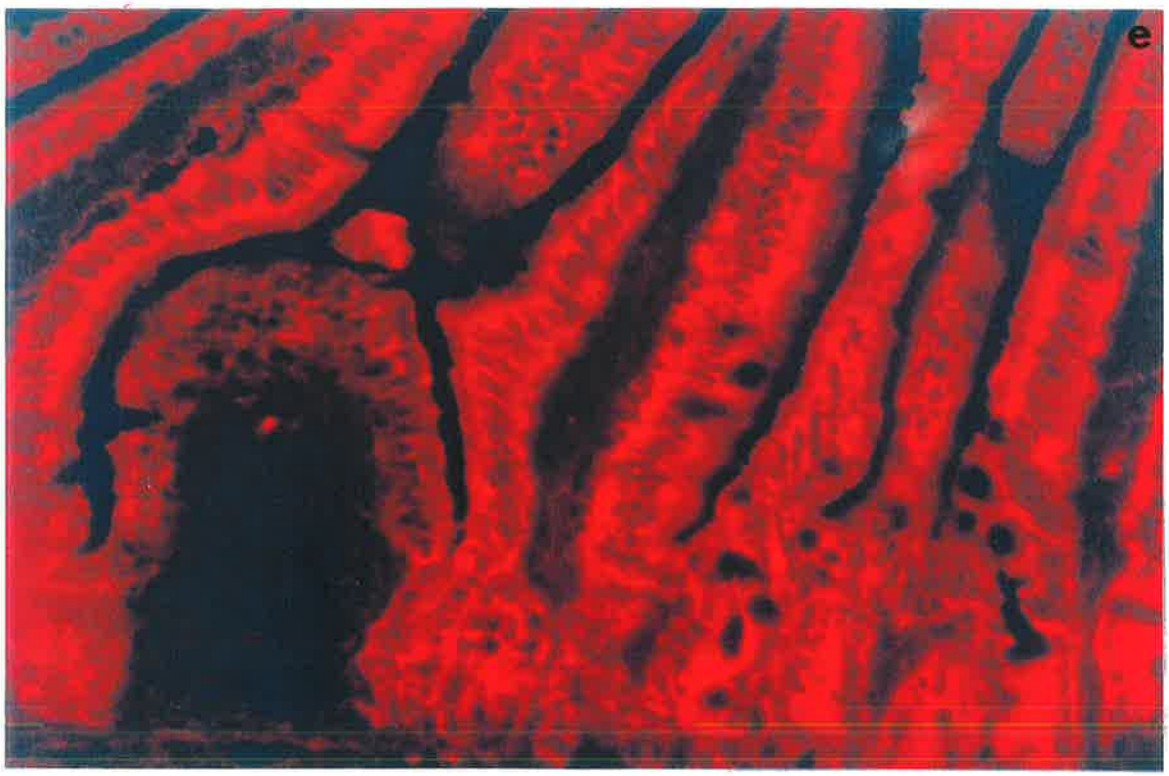
e

2/CD11c; TSA-1/CD11c; CD25/CD11c; HSA/CD11c; Pgp-1/CD11c; TSA-2/CD11c; MTS-33/CD11c; MTS-37/CD11c, MTS-24/CD11c, B220/CD11c, and Sca-1/CD11c.

Two-colour IF staining with mAbs N418 (anti-CD11c) and TIB-107 (anti-Thy1) indicated that all CD11c$^+$ cells (red) were also Thy-1$^+$ (green). Similarly, the CD11c$^+$ cells in LFV expressed the leukocyte common antigen CD45 (Fig 3.18), detected by mAb TIB-122 (green). This indicates that the CD11c$^+$ cells are of haematopoeitic origin and are probably dendritic cells. The CD11c$^+$ cells in LFV did not express detectable levels of the T-cell markers CD4 and CD8 (not shown).

TSA-1, recognised by mAb MTS-35, is a marker of immature thymocytes (Godfrey *et al.*, 1992). In addition, it has been reported that thymic dendritic cells are labelled by mAb MTS 35 (Vremec *et al.*, 1992). Most of the CD11c$^+$ cells in the LFV and in the lamina propria of classical villi were also stained by mAbs E3 81-204 (Fig 3.19a-c) and MTS-35 (not shown) which detect Sca-2. The CD11c$^+$ cells in the subepithelial regions of LFV appear to express CD25 (Fig 3.19d-f). The situation with CD11c$^+$ cells between the lymphocytes in the cores and bases of the LFV is less clear. While it appears that some may co-express CD25, it is difficult to exclude the possibility that the co-localization of CD11c (red) and CD25 (green) is due to the close apposition of the cell membranes of CD25$^+$ lymphocytes and CD11c$^+$ dendritic cells. Resolution of this difficulty requires confocal microscopy and/or immuno-electron microscopy.

Heat stable antigen and the phagocyte glycoprotein (Pgp-1) are expressed by thymic dendritic cells (Vremec *et al.*, 1992). Most of the CD11c$^+$ (red) cells in LFV co-expressed (green) HSA (Fig 3.20a-c) and Pgp-1 (Fig 3.20d-f).

As mentioned earlier, mAb MTS-33 stains cortical thymocytes and thymic epithelial cells (cortical and medullary). In LFV (not shown), cells stained by mAb MTS-33 were located mainly in sub-epithelial areas and at the bases of the LFV. The positive

Figure 3.18

Two-colour immunofluorescence staining of jejunum from a RAG-1 knockout mouse. MAb N418 (PE) in combination with either mAb TIB-107 (FITC) or mAb TIB-122 (FITC). **a-c**, mAbs TIB-107 (anti-Thy-1) and N418 (anti-CD11c); **d-f,** mAbs TIB-122 (anti-CD45) and N418 (anti-CD11c). **a**- double exposure for FITC and PE. **b-** single exposure for FITC **c**- single exposure for PE. **d**- double exposure for FITC and PE. **e**- single exposure for FITC. **f**- single exposure for PE. Original magnification x 83.

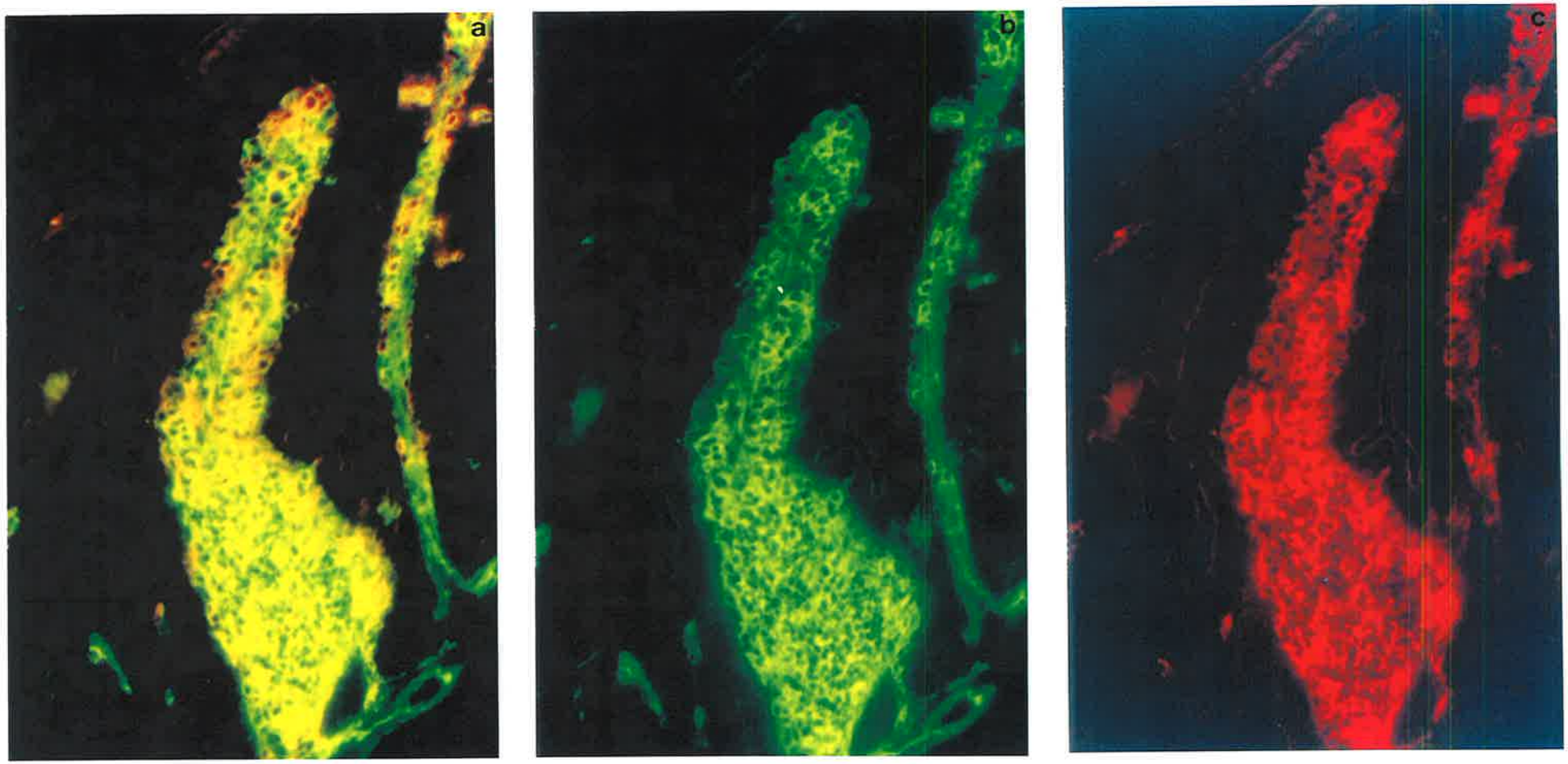
a
b
c

Figure 3.19

Two-colour immunofluorescence analysis of LFV from a RAG-1 knockout mouse using mAb N418 (PE) in combination with either mAb E3 81-204 (FITC) or PC-61 (FITC). **a-c**, mAbs E3 81-204 (anti-Sca-2) and N418 (anti-CD11c); **d-f**, mAbs PC-61 (anti-CD25) and N418 (anti-CD11c). **a**- double exposure for FITC and PE. **b**- single exposure for FITC **c**- single exposure for PE. **d**- double exposure for FITC and PE. **e**- single exposure for FITC (signal amplification). **f**- single exposure for PE. Original magnification x 83.

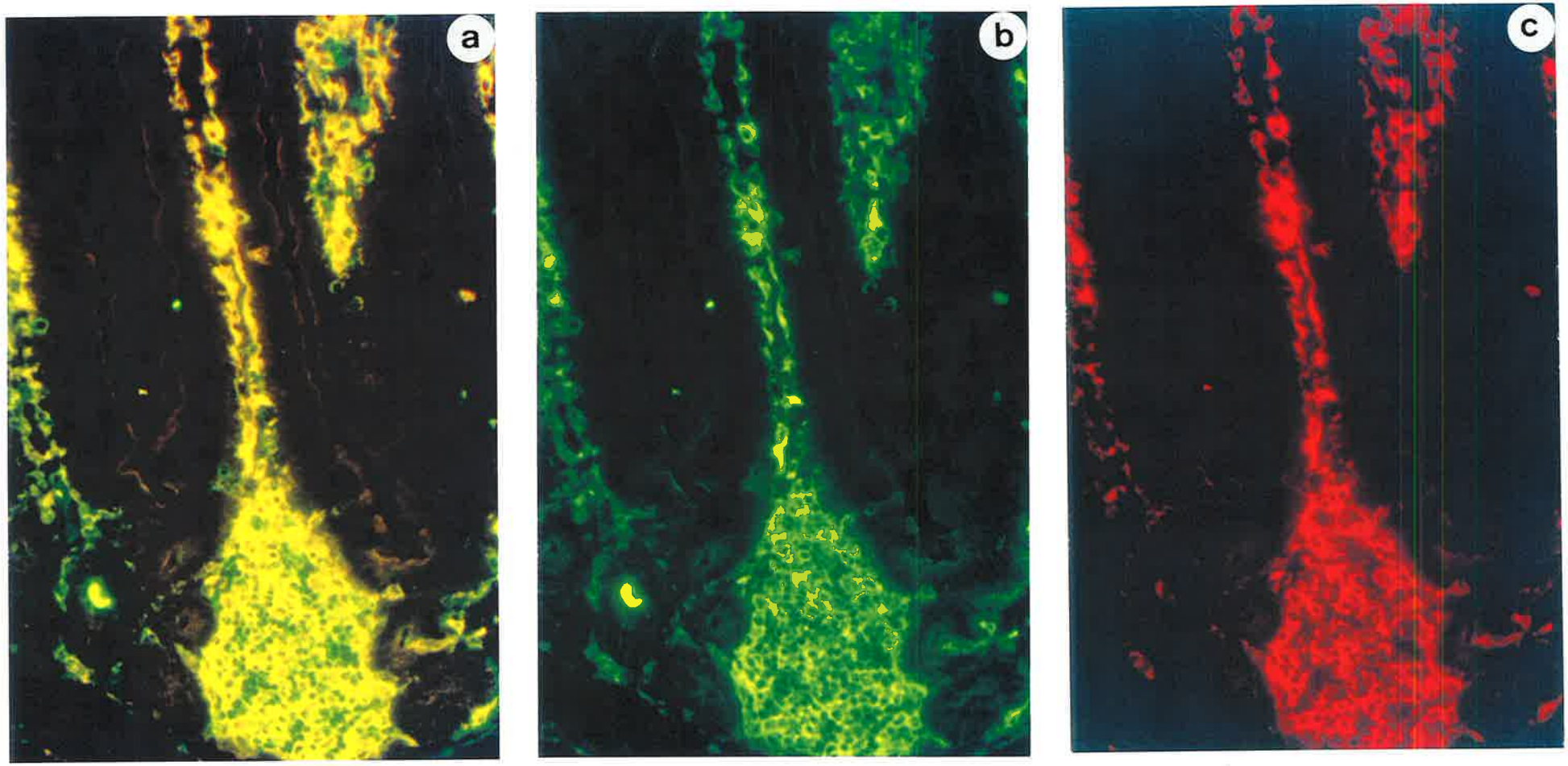
a
b
c

Figure 3.20

Two-colour immunofluorescence staining of jejunum from a RAG-1 knockout mouse. MAb N418 (PE) in combination with either mAb M1/69 (FITC) or IM7.8.1 (FITC). **a-c**, mAbs M1/69 (anti-HSA) and N418 (anti-CD11c), **d-f,** mAbs IM7.8.1 (anti-Pgp-1) and N418 (anti-CD11c). **a**- double exposure for FITC and PE. **b**- single exposure for FITC **c**- single exposure for PE. **d**- double exposure for FITC and PE. **e**- single exposure for FITC. **f**- single exposure for PE. Original magnification x 83.

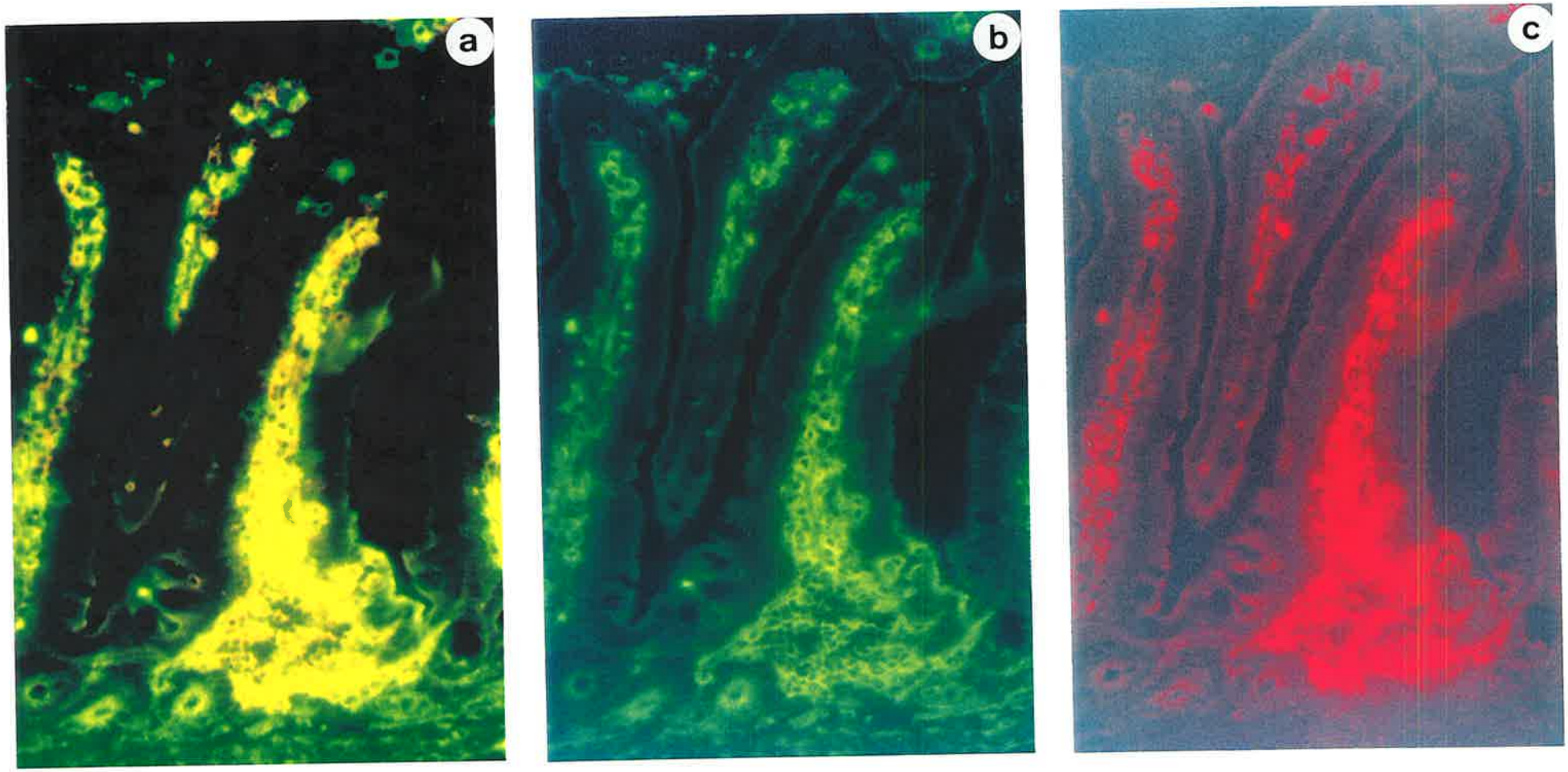
a
b
c

cells were large and irregular. Dual colour IF staining suggests that most of these cells are MTS-33$^+$ and either CD11c$^-$ or CD11c^{lo} (not shown). Consequently the MTS-33$^+$ cells in LFV may be dendritic cells or they may be more related to thymic epithelial cells. It seems most likely that they are similar to the CD11c$^-$ population of DC reported in the subepithelial dome region of Peyer's patches (Kelsall & Strober, 1996).

Monoclonal antibody MTS32 stains epithelial cells in both the cortex and the medulla in the thymus. To examine the relationship between expression of TSA-2 antigen and the CD11c molecule in LFV, simultaneous staining was undertaken with mAbs MTS 32 and N418. These studies revealed that the cells in LFV that express TSA-2 do not co-express CD11c (Fig 3.21). Two-colour analysis of staining by mAbs MTS-37 (thymocytes and thymic epithelium) and N418 indicated that these antibodies also stain independent cell types (not shown). Only a few double positive cells were present in subepithelial areas within the LFV (not shown). Similarly, double labelling with mAbs MTS 24 and N418 revealed that most CD11c$^+$ cells in LFV were negative for MTS 24 (not shown). Dual fluorochrome analysis of staining with mAb RA3-6B2 and N418 demonstrated that the CD11c$^+$ cells did not express the B-220 antigen (not shown). Furthermore, the CD11c$^+$cells did not express the Sca-1 molecule (not shown). Table 3.2 summarizes the tissue distribution of the cell-surface molecules detected with the complete panel of monoclonal antibodies in thymus, LFV, adjacent villi and IEL.

Figure3.21

Two-color immunofluorescence staining of LFV from a RAG-1 knockout mouse using mAb N418 (PE) in combination with mAb MTS 32 (FITC). No double positive TSA-2^{+}CD11c^{+} cells· Original magnification x 83.

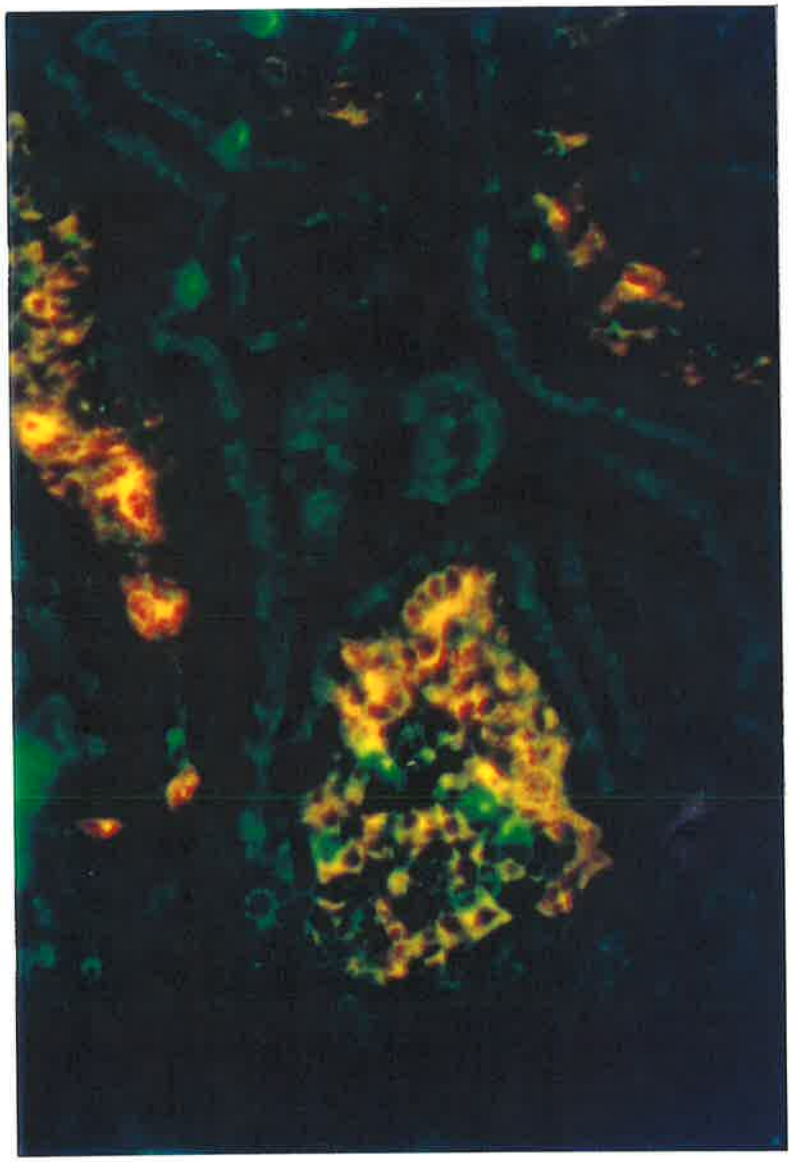

M1/69 (anti-HSA)	Haematopoietic progenitors thymocytes, granulocytes, B cell subsets	+++	++	+++	+++	+++	++
IM7.8.1 (anti-Pgp-1)	Leukocytes, Activated T cells, thymocytes	++	++	+++	+++	+++	++
E13 161-7(anti-Sca-1)	Haematopoietic progenitors, thymocytes	++	+++	-	+	+	-
MTS 32 (anti-TSA 2)	Cortical thymocytes, TEC, T cell Subsets	+++	+	++	-	++	++
MTS 33 (unknown)	Cortical thymocytes, TEC, B cells	+++	++	-	+++	++	++
MTS 37 (unknown)	Cortical thymocytes, TEC, B cells	+++	++	-	+++	++	+
MTS 20 (unknown)	TEC (Medulla)	-	++	-	+++	+	+
MTS 1 (unknown)	TEC	++	++	-	+	-	-
MTS 9 (unknown)	TEC, Thymocytes (Cortex, Medulla)	-	++	-	-	-	-
MTS 10 (unknown)	TEC	+	++	-	-	-	-
MTS 44 (unknown)	TEC	+	++	-	-	-	-
M1/70; Mac-1 (anti-CD11b)	Myeloid and natural killer cells	ND	ND	-	+	++	++
F4/80	Macrophages	ND	ND	-	+	+	-
MK-D6 (MHC-11)	Dendritic cells, monocytes, macrophages, B cells	+	+	+	+++	++	+
N418 (anti-CD11c)	Dendritic cells	ND	ND	+	+++	++	+

-, +, ++, +++: negative, rare, scattered, many respectively.
ND: not done. TEC: thymic epithelial cells
* Subpopulation of cortical thymocytes, scattered B cells in thymic medulla.

Table 3.2: The specificity of the antibodies used in this study and their binding patterns in Thymus, LFV, Classical Villi & IEL

Antibodies	Specificity	Binding patterns					
		Thymus		LFV		Classical Villi	IEL
		Cortex	Medulla	Center	Subepithelial		
H57-597 (anti-βTCR)	Thymocytes, mature T cells	+	+++	+	-	++	+
GL3 1A (anti-TCRγ/δ)	Thymocytes, mature T cells	+	++	+	-	+	++
145-2C11 (anti-CD3ε)	Thymocytes, mature T cells	+	+++	+	-	++	+++
anti-Ig	B cells	ND	ND	+	-	+++	-
RA3 6B2 (anti-B220)	B cells	+*	++*	++	-	+++	-
TIB-107 (anti-Thy-1)	Thymocytes, T cells, (NK cells)	+++	+++	+++	+++	+++	+++
TIB-122 (anti-CD45)	All leukocytes	ND	ND	+++	+++	+++	+++
TIB 207 (anti-CD4)	Thymocytes, T-cell subsets, monocytes, macrophages	++	++	++	-	++	+
YTS 169.4 (anti-CD8)	Thymocytes, T-cell subsets	++	++	+	-	+	+++
P136 (NK1.1)	Natural killer cells	+	+	+	-	++	+
PC-61 (anti-IL-2Rα)	Subset cortical thymocytes, activated T cells, B cells, monocytes	++	+	+++	-	-	-
MTS35 (TSA-1)	Cortical thymocytes, TEC, B cells	+++	+	+++	+++	+++	+
E3 81-204 (Sca-2)	Haematopoietic progenitors, cortical thymocytes, B cells	+++	+	+++	+++	+++	+

3.3 DISCUSSION

Recently, an organized lymphoid structure has been identified in the mucosa of rat small intestine and this has been designated as a lymphocyte-filled villus (LFV) (Mayrhofer, 1994). These novel structures possess some unusual characteristics and it has been suggested that they are a possible site of primary extrathymic T cell differentiation (Mayrhofer & Brooks, 1995). The present study was undertaken to search for similar structures in mice. The histological observations of LFV in normal adult mice revealed that they have a unique structure among gut associated lymphoid tissues. Their microarchitecture was different from classical villi, isolated lymphoid follicles and Peyer's patches. They were composed primarily of compact cells in the center and at the base of the lamina propria of the villus and they were limited to the mucosa. Moreover, the epithelium overlying the lamina propria of LFV had differences from follicle-associated epithelium at the light microscopic level. In addition, high endothelial venules were not observed in these structures.

In the rat, LFV are detected in the second week of life (Mayrhofer & Brooks, 1995), which is concomitant with development of the small intestinal mucosa at weaning (Cummins *et al.,* 1988a; Cummins *et al.,* 1988b). Although they may be seeded earlier, their development may depend on the lumenal environment of the gut. They are present also in pathogen free rats (Mayrhofer & Brooks, 1995), indicating that the generation of lymphocytes in these structures occurs independently of infective agents. In addition, the location of lymphocytes principally at the base and center of LFV may provide the necessary microenvironment for antigen-independent development of lymphocytes in the presence of professional antigen presenting cells. Moreover, the similar appearance of LFV in athymic nude rats and mice as in normal counterparts indicates that these structures can develop in the absence of a normal thymic environment. Furthermore, the presence of LFV in scid and RAG-1 mutant mice, which have no functional B and T

lymphocytes, is further evidence for extrathymic development of lymphocytes in LFV. Likewise, the existence of LFV in LTα, LT β and LT/TNF gene knockout mice, which have abnormal secondary lymphoid organs (De Togni *et al.,* 1994; Banks *et al.,* 1995; Koni *et al.,* 1997; Eugster *et al.,* 1996), indicates that the organogenesis of LFV resembles the thymus rather than secondary lymphoid organs. Taken together, these observations indicate that LFV share characteristics with primary lymphoid tissue such as the thymus. LFV were not limited to rats and mice, as they were also identified in the small intestine of Syrian hamsters.

Kanamori *et al* (1996) have described recently the presence of novel lymphoid structures (crypto-patches) in the mucosa of the mouse small intestine. The crypto-patch occupies the lamina propria in the crypt region of the mucosa and it was estimated that the small intestine contains approximately 1500 of these structures. The CPs have similarities with LFV observed in rat (Mayrhofer & Brooks, 1995), mouse and Syrian hamster small intestine. However, in contrast to CPs which are located in crypt lamina propria, the lymphocytes in LFV were compact at the base and in the center of the lamina propria and extended towards the villus tip. The structure of LFV was similar in different strains of mice (Balb/c and C57Bl/6), so that it is unlikely that the morphological difference from crypto-patches is due to use different strains. Moreover, in both rat and mouse, the LFV appear for more numerous than crypto-patches (approximately 1 per 100 villi).

The differentiation markers expressed by the lymphoid cells in crypto-patches (e.g. c-kit, interleukin 7 receptor) suggest that these structures may have a primary generative function. Similarly, the lymphocytes in LFV resembled immature T-cells in many respects. The LFV is composed primarily of αβ TCR^-, γδ TCR^-, $CD3^-$, $CD4^-$, $CD8^-$ and $B220^-$ cells. Expression of leukocyte common antigen (CD45) by the cells in LFV indicates that they, like other leukocytes, are of haematopoietic origin. Evidence that the

lymphocytes in LFV might be of T cell lineage arose from the observation that they express the pan T-cell marker, Thy-1. Thy-1 is a major cell surface molecule that is expressed very early in murine T cell development (Palacios *et al.,* 1987). However, it is not a lineage-specific marker of T cells. The expression of other early thymocyte markers, such as CD25, Sca-2 (TSA 1), HSA, Pgp-1 and TSA 2, by lymphocyte subpopulations within LFV suggests that these may be T cells at an early stage of differentiation. The presence of similar lymphocyte subpopulations in the mutant mice, the sensitivity of lymphocytes in LFV to corticosteroids, and the presence of cell division will be discussed in Chapters 4 and 5.

The initial lymphocyte population in suckling rats is surface Ig^-, $\alpha\beta$ TCR^- but from the third week in normal rats and from 7-10 weeks in nude rats, a subpopulation appears that is $\alpha\beta$ TCR^+ and mainly $CD4^+$. The majority of lymphocytes remain Ig^-, $\alpha\beta$ TCR^-, $\gamma\delta$ TCR^-, $CD3^-$ and most express CD25 and CD43 (Mayrhofer & Brooks, 1995). In contrast, the $\alpha\beta$ TCR^+ subset was not found in LFV of mice. However, based on expression of MTS37 antigen and CD25, there were two subsets of lymphocytes in LFV. Those that were located mainly in the centers and bases of LFV were $MTS37^-CD25^+$, while the other subset was found mainly in the sub-epithelial region of the tip and lateral margins of the LFV and these were $MTS37^+CD25^-$. The latter subset ($MTS37^+CD25^-$) in the outer regions may be more mature than the former subset ($MTS37^-CD25^+$) in the center of LFV. Further studies, using higher sensitivity detection methods, are needed to exclude the possibility that the latter subpopulation expresses the TCR/CD3 complex at low levels.

As mentioned earlier, LFV also contain a subpopulation of $CD4^+$ cells. The lack of CD3 expression, which is a characteristic feature of immature T-cells (Fowlkes & Pardoll, 1989), implies that these are not mature $CD4^+$ T cells. A $CD4^+$ subset,

representing the earliest T precursor cells in the adult mouse thymus, has been reported by Wu *et al.*(1991a). This population has been shown to share a number of surface antigens with bone marrow haematopoietic stem cells (Wu *et al.,* 1991a). The $CD3^-$ $CD4^+$ $CD8^-$ subset appears to be less mature than the established $CD3^-$ $CD4^-$ 8^- precursors, both in their ability to reconstitute the thymus and in their status of TCR gene-rearrangement (Wu *et al.,* 1991a). It is possible, therefore, that the $CD4^+$ cells in LFV are equivalent to the committed lymphoid progenitors ($CD4^+$ cells) in the thymus. This subset will be discussed in more detail in Chapters 4 and 5.

Large and irregular non-lymphoid cells, bearing the surface marker MHC class II, were present in the subepithelial region of LFV. They were observed also between the epithelial cells overlying LFV and in this respect, they resemble the dendritic cells that are found within the pockets of M cells in follicle-associated epithelium of PPs. It is possible, therefore, that the epithelium of LFV is specialized for antigen absorption and that lumenal antigens influence lymphocyte development within LFV. The majority of the MHC class II-positive cells were not stained by mAbs M1/70 (anti-Mac1 or CD11b) or F4/80. The MHC class II positive cells that expressed CD11c are believed to be dendritic cells. Phenotypically, the DC in LFV most closely resembled thymic dendritic cells (Vremec *et al.,* 1992; Ardavin & Shortman, 1992) in that they expressed Thy-1, CD-45, HSA, Pgp-1, TSA-1, and Sca-2. Although DC from mouse and human thymus express CD8 and CD4 molecules (Vremec *et al.,* 1992; Winkel *et al.,* 1994), neither of these molecules was detected on DC in LFV. Moreover, they did not express the B cell-associated isoform of CD45, B220.

The antigens expressed by the cells in LFV and in the thymus, were compared using a panel of monoclonal antibodies raised against thymic stromal elements (Godfrey *et al.,* 1990). The cells in LFV had phenotypic similarities with those in the thymus but they also exhibited some differences. These differences included the absence in LFV of

thymic epithelial cell markers recognized by mAbs MTS-9, MTS-10 and MTS-44. In the thymus, mAbs MTS 32, MTS 33 and MTS 37 recognise subsets of thymic epithelial cells in addition to thymocytes (Godfrey *et al.*, 1990). In LFV, mAb MTS 32 stained only a population of lymphocytes and this antibody did not label the non-lymphoid cells. In contrast, mAb MTS 33 stained large and irregular non-lymphoid cells which were located mainly in subepithelial areas and at the bases of LFV. These cells were either $CD11c^-$ or $CD11c^{lo}$. While expression of the MTS 33 antigen could indicate an epithelial origin for these cells, it is more likely that they are dendritic cells of the sort discribed by Kelsall & Strober (1996) in the subepithelial dome of PP. As mentioned before, mAb MTS 37 recognized a sub-population of lymphocytes and also non-lymphoid cells in LFV. The $MTS37^+$ non-lymphoid cells were located mainly beneath the epithelium and as in the case of the $MTS33^+$ cells, these cells did not co-express CD11c. As argued above, $MTS37^+CD11c^-$ and $MTS33^+CD11c^-$ cells may be immature DC that have not expressed CD11c, as suggested by Kelsall & Strober (1996) for similar cells in PP. The MTS-37 antigen is also expressed by peripheral B-cells and peritoneal macrophages (Godfrey *et al.,* 1990; Tucek *et al.,* 1992). In Peyer's patches, mAb MTS-37 stained primarily B-cells in germinal centers (data not shown). In LFV, with only scattered B220 and F4/80 positive cells, the MTS-37 positive cells are unlikely to be B-cells or macrophages. Double immunofluorescence staining, using anti-keratin antibody, is required to investigate whether the large cells stained by mAbs MTS-33 and MTS-37 beneath the epithelium of LFV are epithelial cells.

Monoclonal antibodies MTS20 and MTS24 recognize scattered epithelial cells in the thymus particularly at the corticomedullary junction (Malin *et al.*, 1998). In LFV large $MTS20^+CD11c^-$ and $MTS24^+$ $CD11c^-$ cells were located mainly beneath the epithelium in a distribution similar to $MTS37^+CD11c^-$ and $MTS33^+CD11c^-$ cells. For the reason discussed above, they could be either immature DC or epithelial cells.

The function of non-lymphoid cells in LFV is unknown and requires further study. As mentioned before, the epithelium overlying the lamina propria of LFV was not similar to FAE in that it did not contain large numbers of intraepithelial lymphocytes. However, like FAE, MHC class II-positive DC appear to infiltrate the epithelium of LFV whereas they are absent from the epithelium of classical villi. Furthermore, LFV in rats have been shown to absorb horse radish peroxidase from the gut lumen (Mayrhofer, unpublished). It is possible that LFV have cells that are equivalent functionally to M cells. However, it has also been proposed that the enterocytes are involved in antigen presentation (Bland & Warren, 1986; Mayer & Shlien, 1987). MHC class II molecules on intestinal epithelium could function to bind and absorb processed peptides (Mayrhofer & Spargo, 1989; Mayrhofer, 1994; Mayer *et al.,* 1997). It is conceivable that MHC class II-positive epithelial cells overlying the LFV, together with the non-lymphoid cells beneath the epithelium, are involved in development of lymphocytes in LFV. Furthermore, it is possible that enterocytes influence LFV through the secretion of soluble factors. IL-7 mRNA has been detected in epithelium of the human small intestine, indicating that intestinal epithelial cells may provide appropriate signals for thymus-independent T cell differentiation in the gut (Madrigal *et al.,* 1997). The non-lymphoid cells in the LFV could be involved in presentation of antigen for initiating immune responses to lumenal antigens, in sustaining lymphocyte-mediated immune suppression to foreign antigens and for the induction of oral tolerance. On the one hand, thymus-independent T cell differentiation could differ fundamentally from T cell development in the thymus. Whereas thymic T cell differentiation is independent of exogenous antigen and leads to the development of naive cells that need antigen for the first time in the periphery, it is possible that thymes-independent T cell differentiation is antigen-deriven (ie positively selected by exogenous and/or endogenous antigens) and that it yields short-lived activated T cells. On the other hand, lumenal antigens may be involved in negative selection in LFV, as described in Peyer's patches (Chen et al, 1995). Finally, if our hypothesis that

LFV are extrathymic sites of primary T cell differentiation is correct and lumenal antigens play a role in repertoire expansion/selection, it will be necessary to show that some lymphocytes in the LFV express an antigen-specific receptor (TCR/CD3 complex). However transitory, before migration from the LFV, this would be required for either positive or negative selection to occur.

CHAPTER 4

IDENTIFICATION OF CELL SURFACE MARKERS IN THE LYMPHOCYTE-FILLED VILLI (LFV) OF T CELL-DEFICIENT MUTANT MICE

4.1 INTRODUCTION

The histological identification of LFV in the normal adult mouse small intestine revealed that they are unique structures among the gut associated lymphoid tissues (Chapter 3). Their micro-architecture was different from classical villi, isolated lymphoid follicles and Peyer's patches. They were composed primarily of a modified villus in which compact lymphoid cells replace the central and basal lamina propria, extending down to but not penetrating the muscularis mucosa. Moreover, the epithelium overlying LFV was similar to that overlying classical villi at the light microscope level. Unlike follicle-associated epithelium, it contained goblet cells. High endothelial venules, which are characteristic of secondary lymphoid organs including PP, were not observed in LFV. Isolated lymphoid follicles were the only structures which had any resemblance to LFV but staining with antibodies to identify the B220 antigen or surface immunoglobulin showed that they contained B cell follicles.

The similarity of size and frequency of LFV in athymic nude mice and in normal mice suggests that these structures develop in the absence of a normal thymic environment. In addition, the presence of LFV in both scid mice and RAG-1 mutant mice points to the fact that colonization of the LFV by lymphocytes was not prevented by either the *scid* mutation or inactivation of the RAG-1 gene by homologous recombination. Moreover, LFV were identified morphologically in TNF α, LT and LT/TNF gene knockout mice which exhibit either abnormal development or agenesis of lymph nodes and PP but normal thymic development and T lymphopoiesis. Taken together, these observations imply that the LFV share characteristics with primary lymphoid tissues such as the thymus.

Analysis of LFV in normal adult mice indicated that the phenotypes of lymphocytes within them were different from those of IEL and from the major

populations of lymphocytes in the PP, isolated lymphoid follicles and in the lamina propria of classical villi. It could be deduced that the main population of lymphocytes in LFV had the phenotype TCR$^-$, CD3$^-$, CD4$^-$, CD8$^-$, B220$^-$, NK1.1$^-$, suggesting that they were neither mature T cells, B cells nor NK cells. The expression of Thy-1 antigen by many of the cells, particularly those located in the center and at the base of LFV, supports a T cell lineage. Thy-1 is a major cell surface molecule that is expressed very early in murine T cell development (Palacios *et al.,* 1987) and its expression continues throughout the T cell lineage in this species. The expression of other early thymocyte markers, CD25, CD4, Sca-2 (TSA 1), HSA, Pgp-1 and TSA 2, by lymphocyte sub-populations within LFV suggests the presence of cells with phenotypes similar to those of immature T cells. In addition to the major population of Thy-1$^+$, TCR$^-$, CD3$^-$, CD4$^-$ cells, a small population of CD4$^+$ cells was found in LFV. In contrast to mature T cells, these cells did not express either TCR or CD3 molecules. This population of cells will be discussed further in Chapter 5.

In view of the immature phenotype of the major population of lymphocytes in LFV, it was of interest to examine the role of the thymus in the expansion and differentiation of these lymphocytes. For this reason, the surface antigen phenotype of cells in LFV was studied in athymic nude mice. Moreover, the surface antigen phenotype of lymphocytes was examined in the LFV in mice with severe combined immunodeficiency (scid/scid) and in RAG-1 gene knockout mutants. These mice are deficient in functional T cells and B lymphocytes (Bosma *et al.,* 1983; Mombaerts *et al.,* 1992; Shinkai *et al.,* 1992) but they have functional thymic rudiments that are populated by T cell precursors that progress through differentiation to the point of rearrangement of the genes encoding the TCR (Shores *et al.*, 1990; Rothenberg *et al.*, 1993; Mombaerts *et al.*, 1992; Crompton *et al.*, 1994). Because TCR expression does not appear to occur at a high frequency in LFV, it was hypothesized that the lymphocytes in the LFV of scid and

RAG-1 mutants would express a surface antigen phenotype similar to that of the cells in the LFV of phenotypically normal mice.

4.2 THE SURFACE ANTIGEN PHENOTYPE OF LYMPHOCYTES IN LFV IN NUDE MICE

In order to determine the phenotype of the lymphocytes contained within the LFV in C57Bl/6 nude mice, studies were performed using a panel of monoclonal antibodies and indirect immunoperoxidase and immunofluorescence techniques. Comparisons were made between nude mice and their phenotypically normal counterparts. As in normal mice, scattered cells in LFV from nude mice were stained by mAb RA3-6B2 against the B220 antigen (Fig 4.1a). Only rare cells were stained by sheep anti- mouse Ig (Fig 4.1b). Figure 4.1a illustrates a cluster of $B220^+$ cells at the base of a LFV. The nature of these cells will be studied in more detail by dual colour immunofluorescence staining in Chapter 5.

The main population of lymphocytes in the LFV from nude mice expressed Thy-1 antigen (Fig4.2a) and this antigen was also expressed by large irregular cells in the sub-epithelial areas of the LFV and within the overlying epithelium. Most of the cells in the LFV expressed the leukocyte common antigen CD45 (Fig 4.2b). In contrast to normal mice, only rare Thy-1^+ cells were present in the lamina propria of adjacent villi and many of these did not have the appearance of lymphocytes. The majority of the lymphocytes in the LFV did not express either CD3, the α/β TCR or the γ/δ TCR (Fig 4.3a-c). Rare $CD3^+$ cells were observed within the epithelium on LFV and adjacent villi. The distribution of $CD4^+$ cells in LFV from nude mice was similar to that observed in normal mice (Fig 4.4 a). The $CD4^+$ cells tended to be located distally to a cluster of $CD4^+$ cells at the base of the LFV (Fig 4.4a) and to the area occupied by $B220^+$ cells (Fig 4.1a). The nature of the $CD4^+$ cells will be discussed in more detail in Chapter 5. Only rare cells in lamina propria of

Figure 4.1

Photomicrographs of frozen sections through LFV in the jejunum of a nude mouse. **a**- section stained with mAb RA3-6B2 (anti-B220). **b**- section stained with sheep anti-mouse Ig. Original magnification x 83.

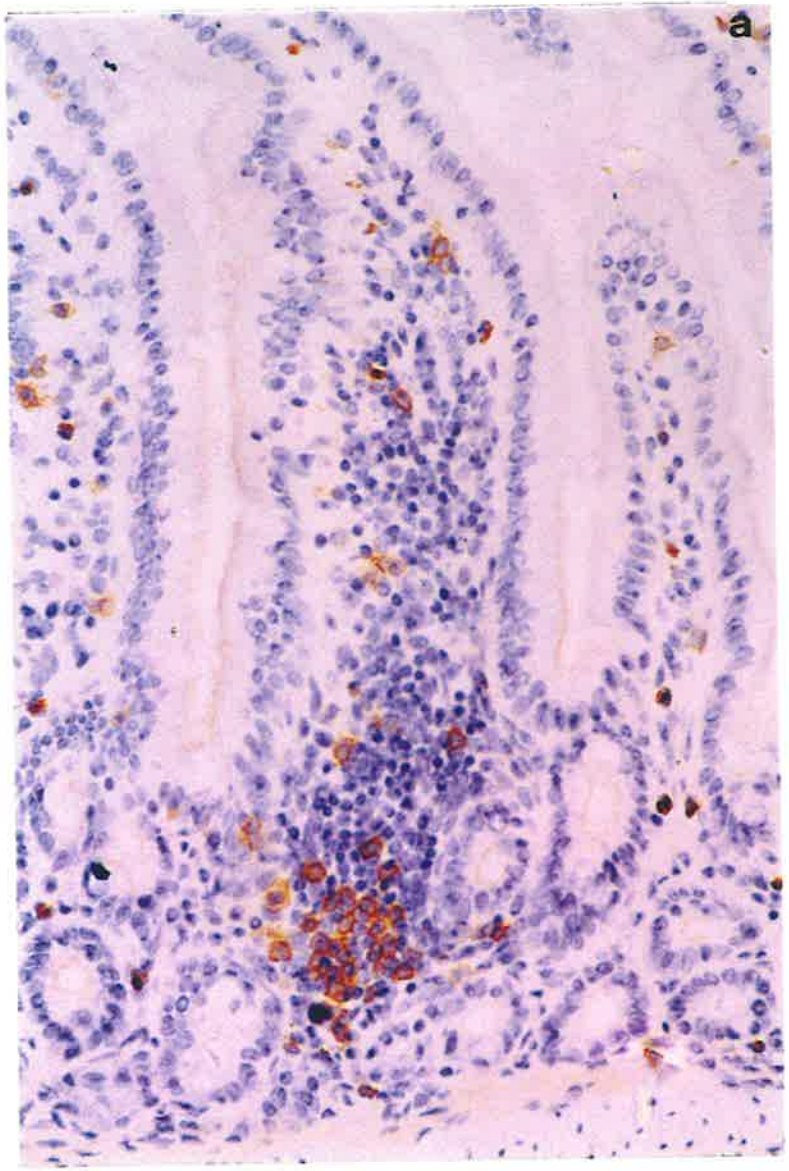
a

b

Figure 4.2

Frozen sections from the jejunum of a nude mouse, stained with monoclonal antibodies by the indirect immunoperoxidase technique. **a**- section stained with monoclonal antibody TIB-107 (anti-Thy-1.2). **b**- section stained with monoclonal antibody TIB-122 (anti-CD45). Original magnification x 83.

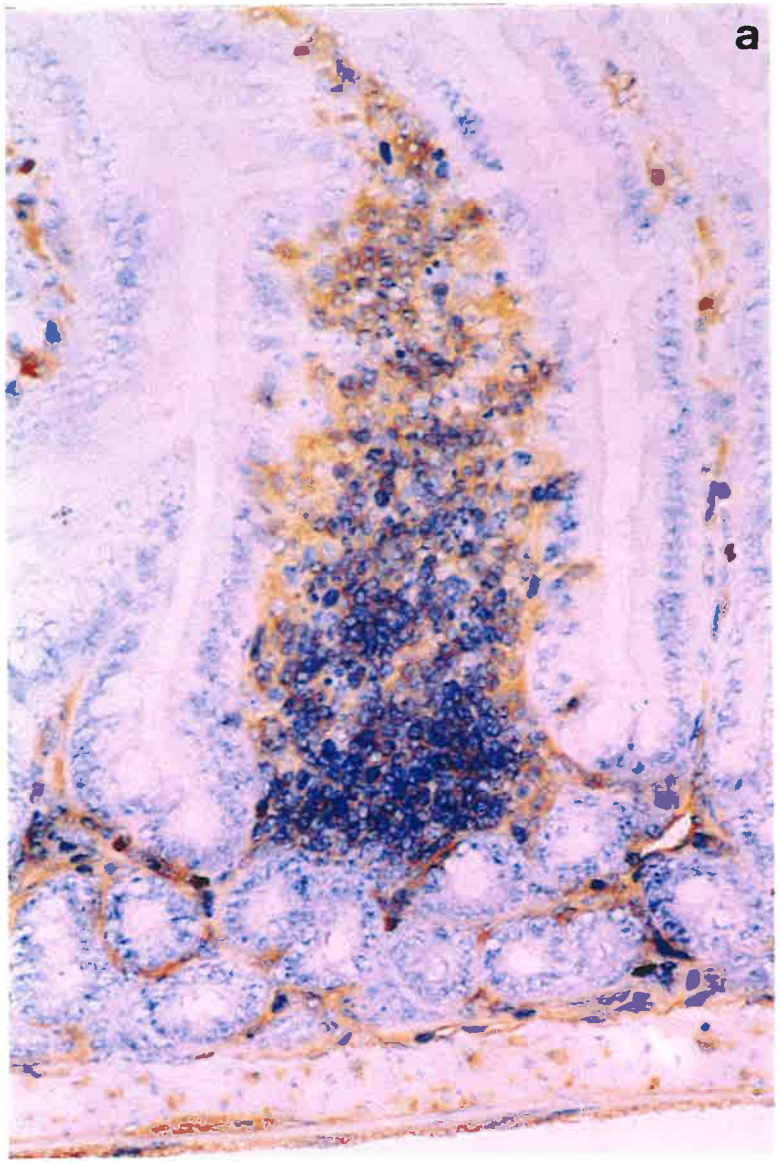
a

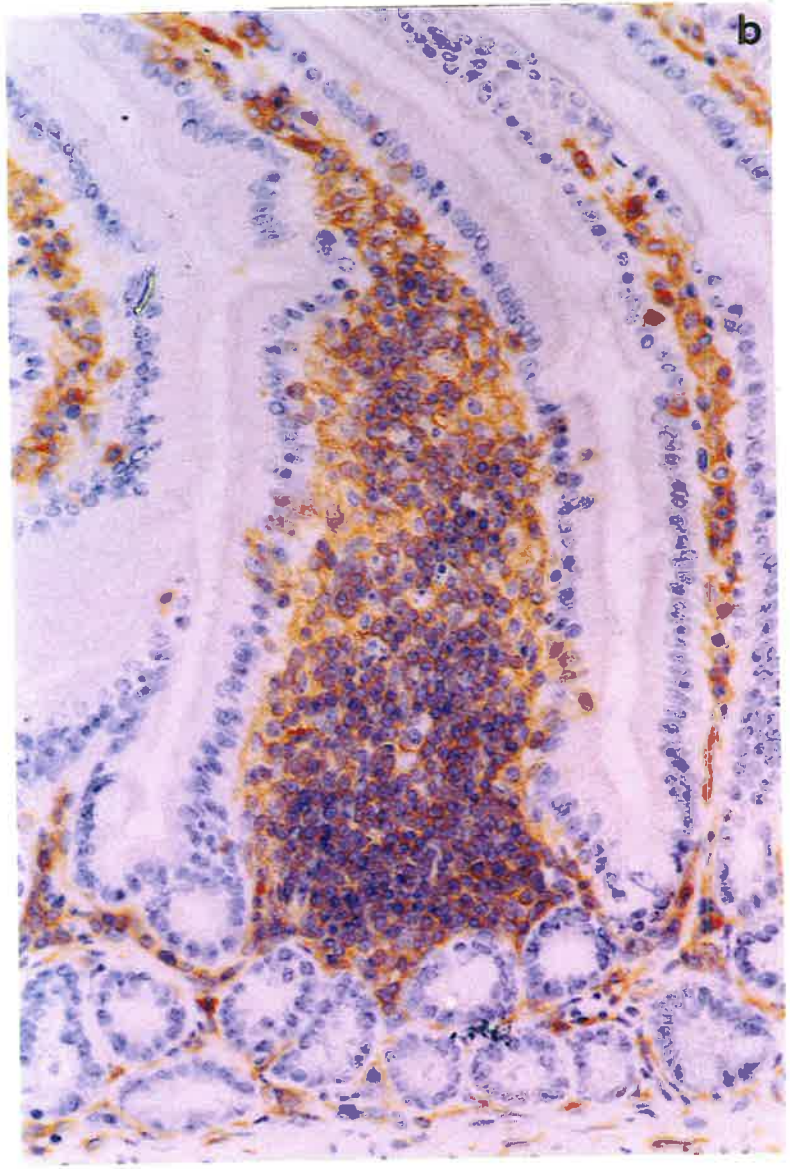
b

Figure 4.3

Frozen sections from the jejunum of a nude mouse, stained with monoclonal antibodies by the indirect immunoperoxidase technique. **a**- mAb 145-2C11 (anti-CD3), shows rare $CD3^+$ cells (arrow) in the LFV and within the epithelium on LFV and adjacent villi. **b**- mAb H57-597 (anti-TCR α/β) shows, rare $\alpha\beta$ TCR^+ cells (arrow) in LFV. **c**- mAb GL3 1A (anti-TCR γ/δ), shows no positive cells in lamina propria of LFV and occasional positive cells (arrow) within the epithelium. Original magnification x 83.

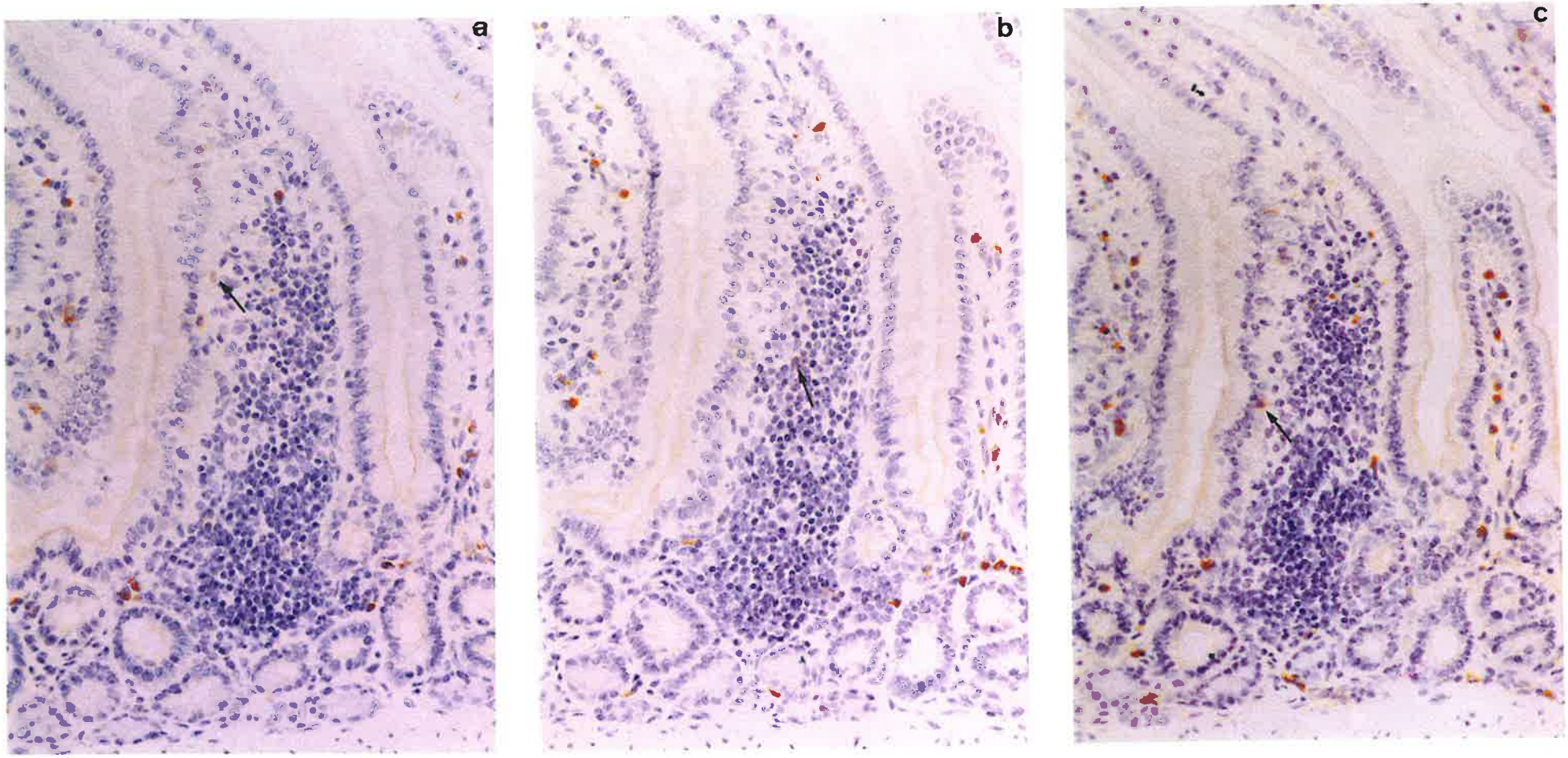
a
b
c

adjacent villi expressed CD4. Scattered cells in LFV were labelled by mAb YTS 169.4 (anti-CD8 α) and many of these were large and irregular in shape. It is likely that some are $CD8\alpha^+$ lymphoid dendritic cells (Wu et al, 1996). Occasional $CD8^+$ cells were also present within the epithelium of both LFV and adjacent villi (Fig 4.4b).

Staining by mAbs against antigens expressed by early thymocytes was similar in sections of LFV from normal and nude mice. Monoclonal antibodies PC-61 (anti-CD25), E3 81-204 (anti-Sca-2) and MTS-35 (anti-TSA-1; anti-Sca-2) all stained the majority of lymphocytes contained within the bases of LFV in nude mice (Fig 4.5a- 4.5c). Cells in the same distribution were also stained by mAbs M1/69 (anti-HSA) and IM7.8.1 (anti-Pgp-1) (not shown). Monoclonal antibody MTS 32 (anti-TSA-2) also stained cells in the bases of LFV from both nude mice (Fig 4.5d) and normal mice but in contrast, stained only occasional cells in the lamina propria of villi from nude mice. As mentioned in Chapter 3, the cells stained by MTS 32 in the lamina propria of villi from normal mice were probably $CD4^+$ T cells (Tucek *et al.*, 1992). Monoclonal antibodies MTS 33 and MTS 37 stained a population of non-lymphoid cells in LFV from nude mice that had a mainly sub-epithelial distribution (not shown). Essentially no cells in the LFV of either normal or nude mice were stained by mAb P136 (anti-NK.1.1), although this antibody stained presumed NK cells in sections of spleen from C57Bl/6 mice (not shown).

Finally the pattern of staining by mAbs that recognized antigens on non-lymphoid elements in LFV (mAbs MK-D6, M1/70, F4/80, N418, see Chapter 3) was similar in LFV from normal and nude mice (not shown).

4.3 THE SURFACE ANTIGEN PHENOTYPE OF LYMPHOCYTES IN LFV IN SCID MICE

The surface antigen phenotypes of cells in LFV in scid mice were studied by indirect immunoperoxidase and immunofluorescence techniques and compared with the

Figure 4.4

Frozen sections from the jejunum of a nude mouse, stained with monoclonal antibodies by the indirect immunoperoxidase technique. **a**- monoclonal antibody TIB 207 (anti-CD4), shows the CD4 positive cells in LFV and occasional $CD4^+$ cells in adjacent villi (arrow). **b**- monoclonal antibody YTS 169.4 (anti-CD8), shows scattered $CD8^+$ cells in the LFV and in the overlying epithelium of both LFV and adjacent villi. Original magnification x 83.

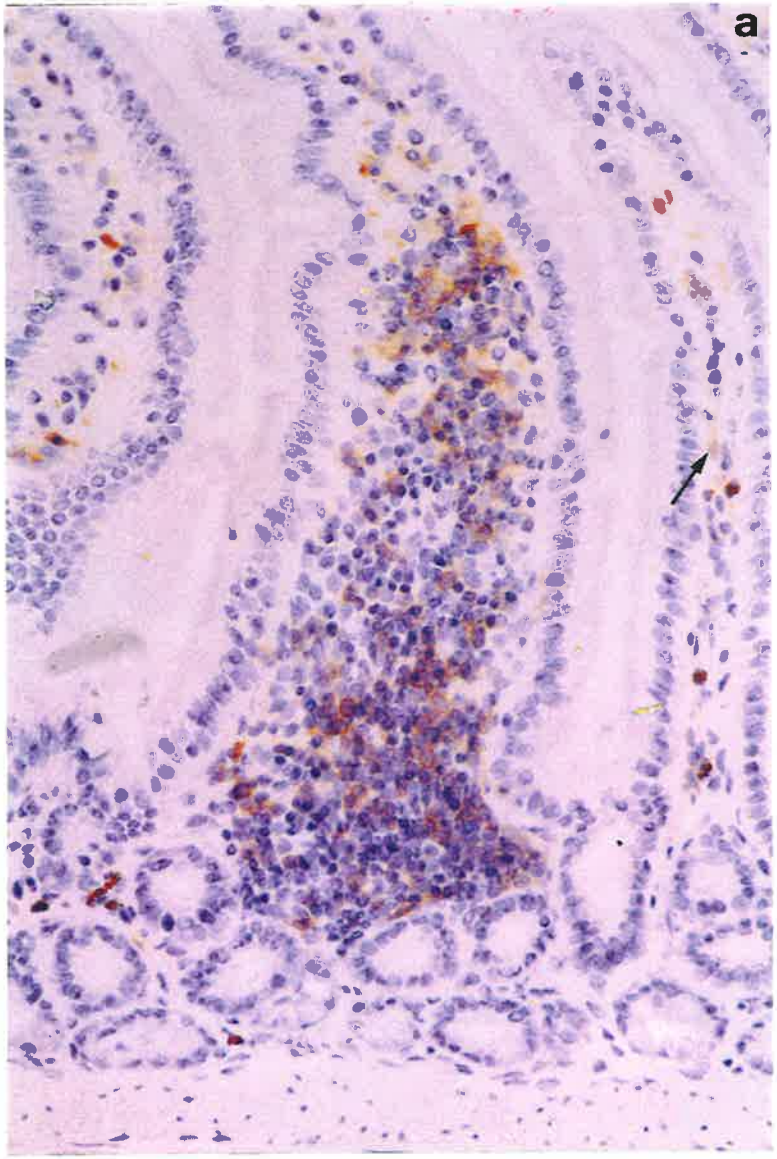
a

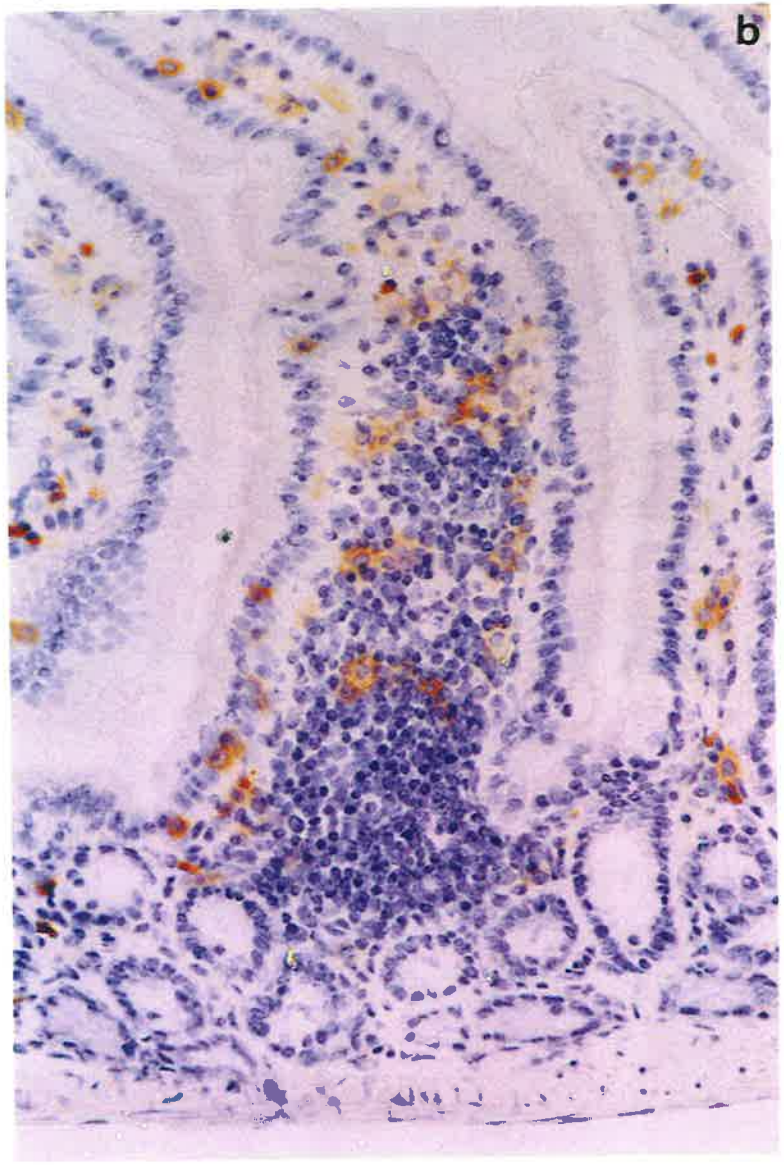
b

Figure 4.5

Frozen sections from the jejunum of a nude mouse, stained with monoclonal antibodies by the indirect immunofluoresence technique. **a**- section stained with mAb PC-61 (anti-CD25). **b**- section stained with mAb E3 81-204 (anti-Sca-2). **c**- section stained with mAb MTS 35 (anti-TSA-1/Sca-2). **d**- section stained with mAb MTS 32 (anti-TSA-2). Original magnification x 83.

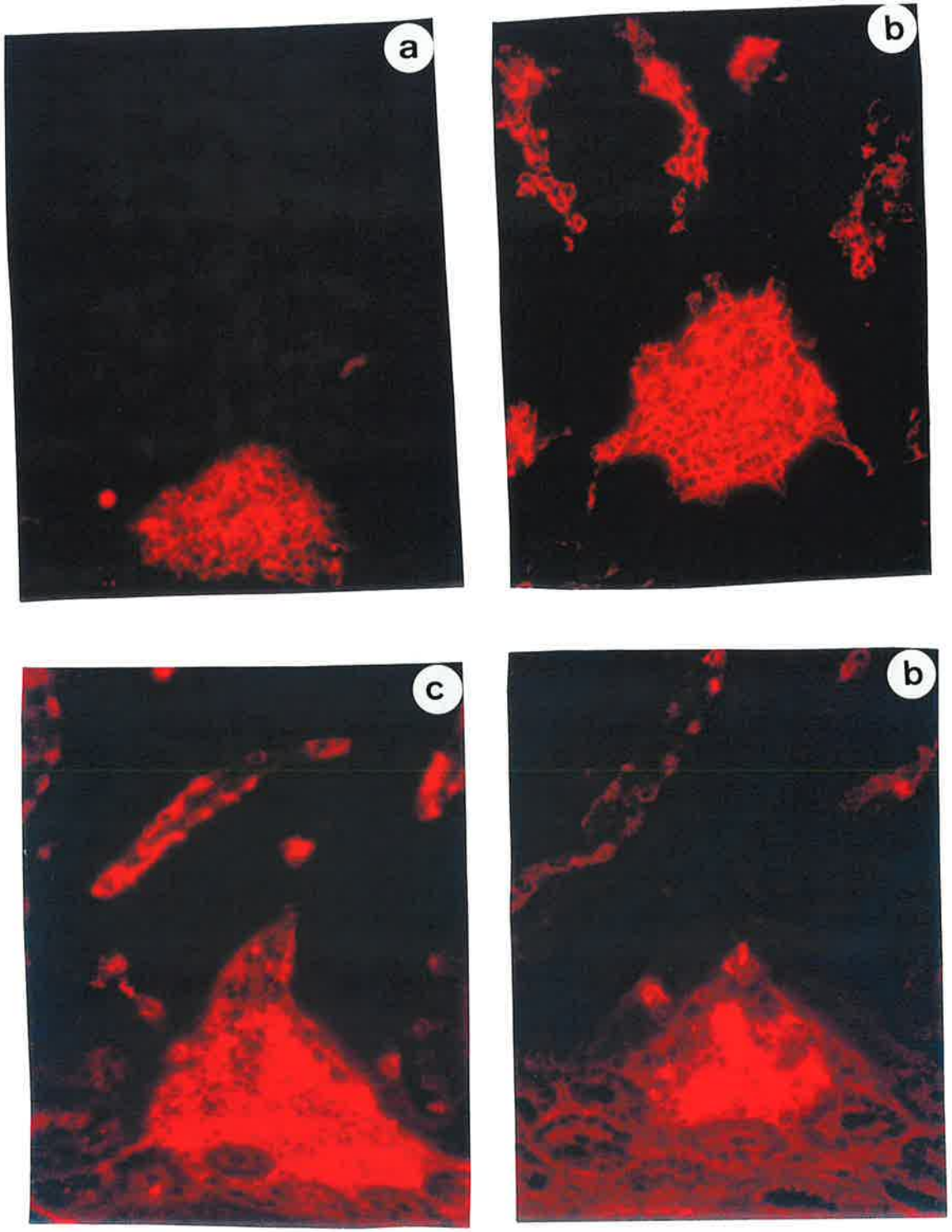
a
b
c
b

cells in the LFV from normal mice. As in normal mice, mAb RA3-6B2 (anti-B220) stained a small number of lymphocytes, mainly at the bases of LFV (Fig 4.6a). Sheep anti-mouse Ig stained only occasional lymphocytes (Fig 4.6b). As expected in scid mice, only occasional $B220^+$ or surface Ig^+ cells were found in adjacent villi.

The main population of lymphocytes in the LFV of scid mice were Thy-1^+ (Fig 4.7a) and $CD45^+$ (Fig 4.7b). Only endogenous peroxidase was detected in sections stained with mAbs against CD3, αβ TCR or γδ TCR (Fig 4.8). However, a population of $CD4^+$ cells was present in scid mice (Fig 4.9 a) as was the case in the LFV from normal mice. Monoclonal antibody YTS 169.4 (anti-CD8) stained scattered cells within the LFV and also IEL in the epithelium overlying both LFV and classical villi (Fig 4.9b).

Lymphocytes expressing CD25 (Fig 4.10a), Sca-2 (Fig 4.10b) and TSA-1/Sca-2 (not shown) were present in LFV from scid mice in numbers and distribution similar to those in LFV from normal mice. Moreover, in scid mice, mAbs M1/69 (anti-HSA) and IM 7.8.1 (anti Pgp-1) stained the majority of cells in LFV (not shown) and TSA-2^+ lymphocytes were also present. However, only occasional TSA-2^+ cells were observed in the lamina propria of adjacent villi (not shown). Monoclonal antibody MTS 37 stained a population of non-lymphoid cells in LFV from scid mice that had a mainly sub-epithelial distribution (not shown). The patterns of cells stained by other mAbs used in this study were similar to those observed in normal mice (not shown).

4.4 THE SURFACE ANTIGEN PHENOTYPE OF LYMPHOCYTES IN RAG-1 GENE KNOCKOUT MICE

Phenotypic analysis of lymphocytes in LFV in RAG-1 gene knockout mice was performed by indirect immunoperoxidase and immunofluorescence techniques, using the same panel of mAbs. The phenotype of cells in LFV in RAG-1 knockout mice was similar to that in scid mice. The main population of cells in LFV was $B220^-$ but as in LFV

Figure 4.6

Photomicrographs of frozen sections through LFV in the jejunum of scid mice. **a**- section stained with mAb RA3-6B2 (anti-B220). **b**- section stained with sheep anti-mouse Ig. Only eosinophils are stained. Original magnification x 83.

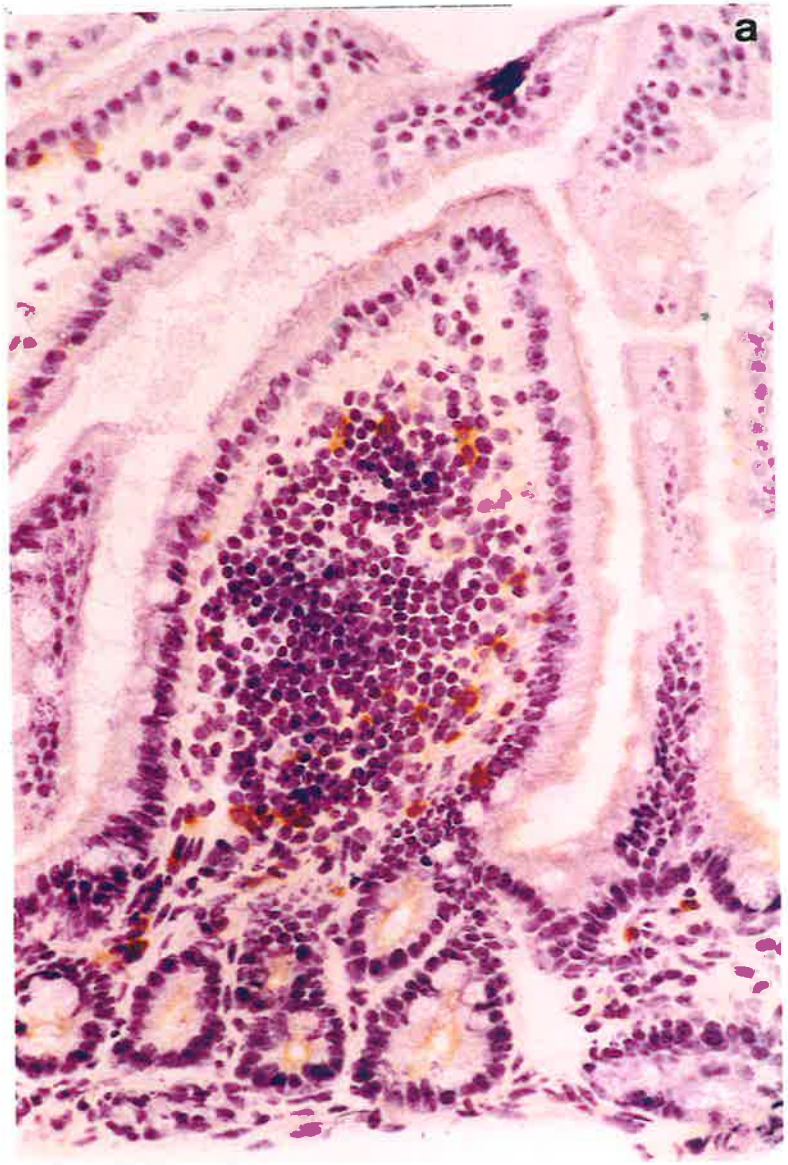
a

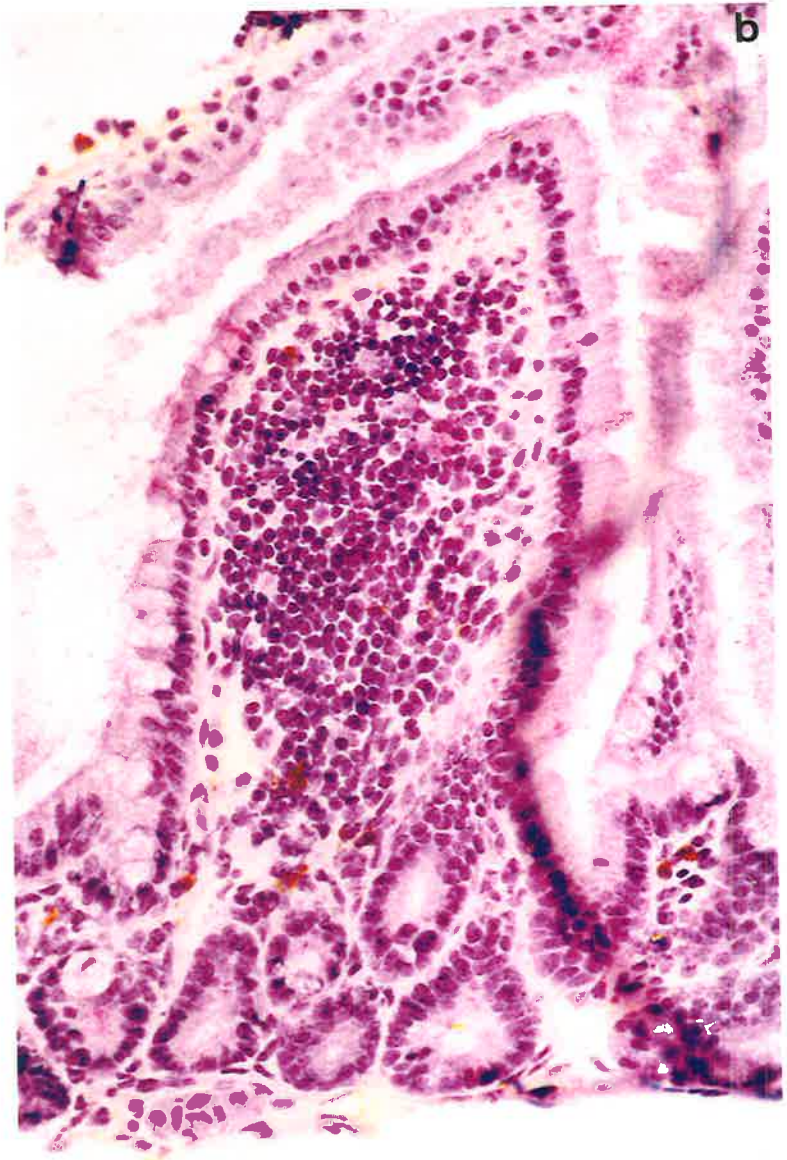
b

Figure 4.7

Frozen sections from the jejunum of a scid mouse, stained with monoclonal antibodies by the indirect immunoperoxidase technique. **a**- section stained with monoclonal antibody TIB-107 (anti-Thy-1.2). **b**- section stained with monoclonal antibody TIB-122 (anti-CD45). Original magnification x 83.

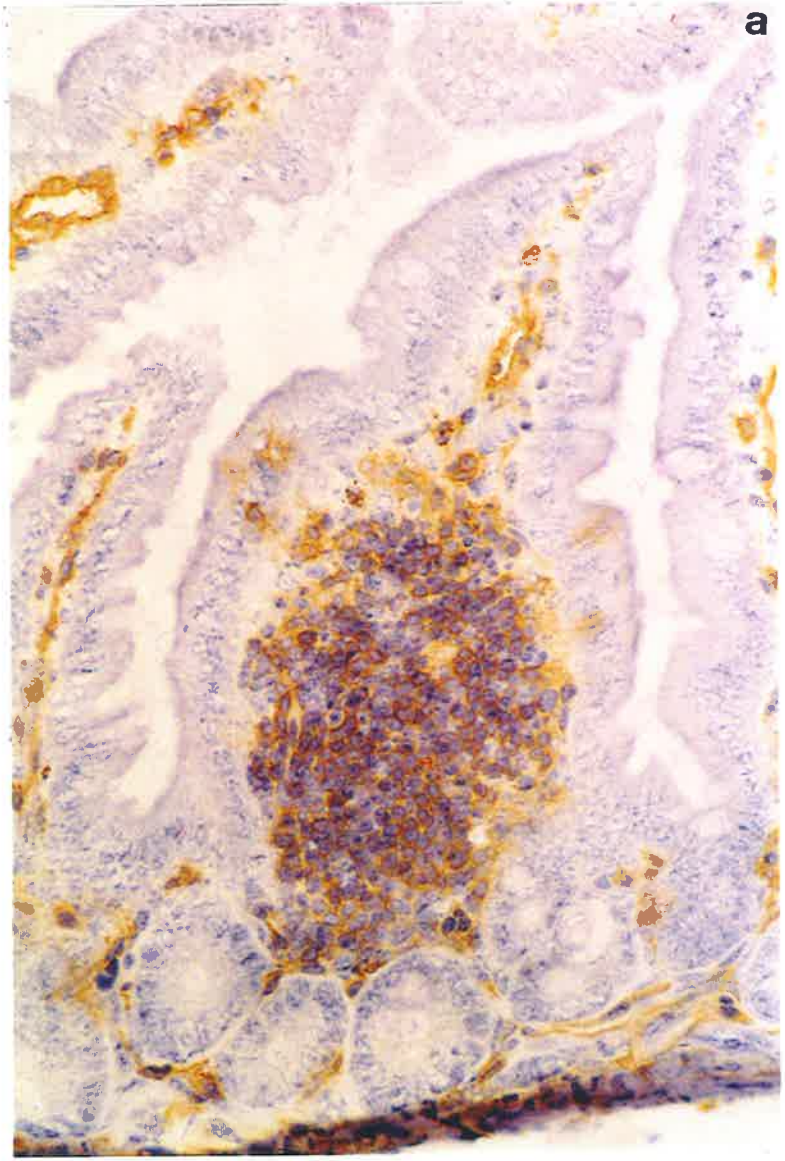
a

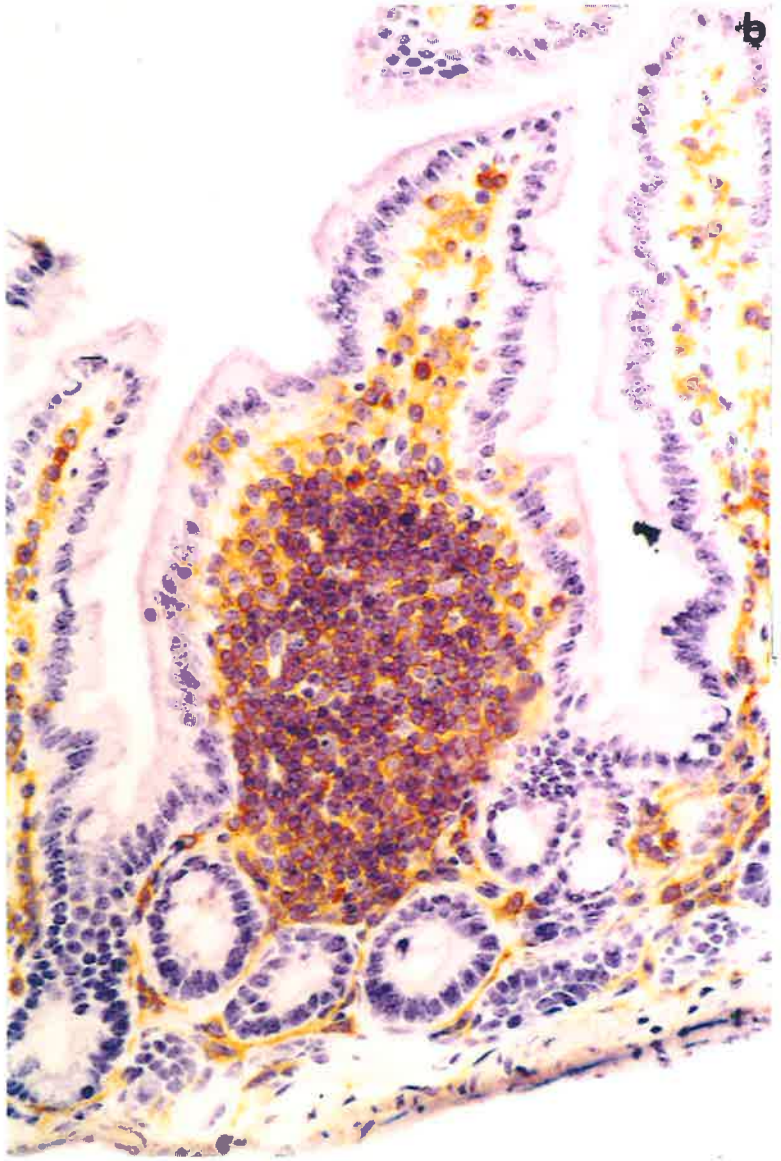
b

Figure 4.8

Frozen sections from the jejunum of a scid mouse, stained with monoclonal antibodies by the indirect immunoperoxidase technique. **a**- section stained with mAb 145-2C11 (anti-CD3). **b**- section stained with mAb H57-597 (anti- TCR α/β). **c**- section stained with mAb GL3 1A (anti- TCR γ/δ). In all cases, only eosinophils are stained. Original magnification x 83.

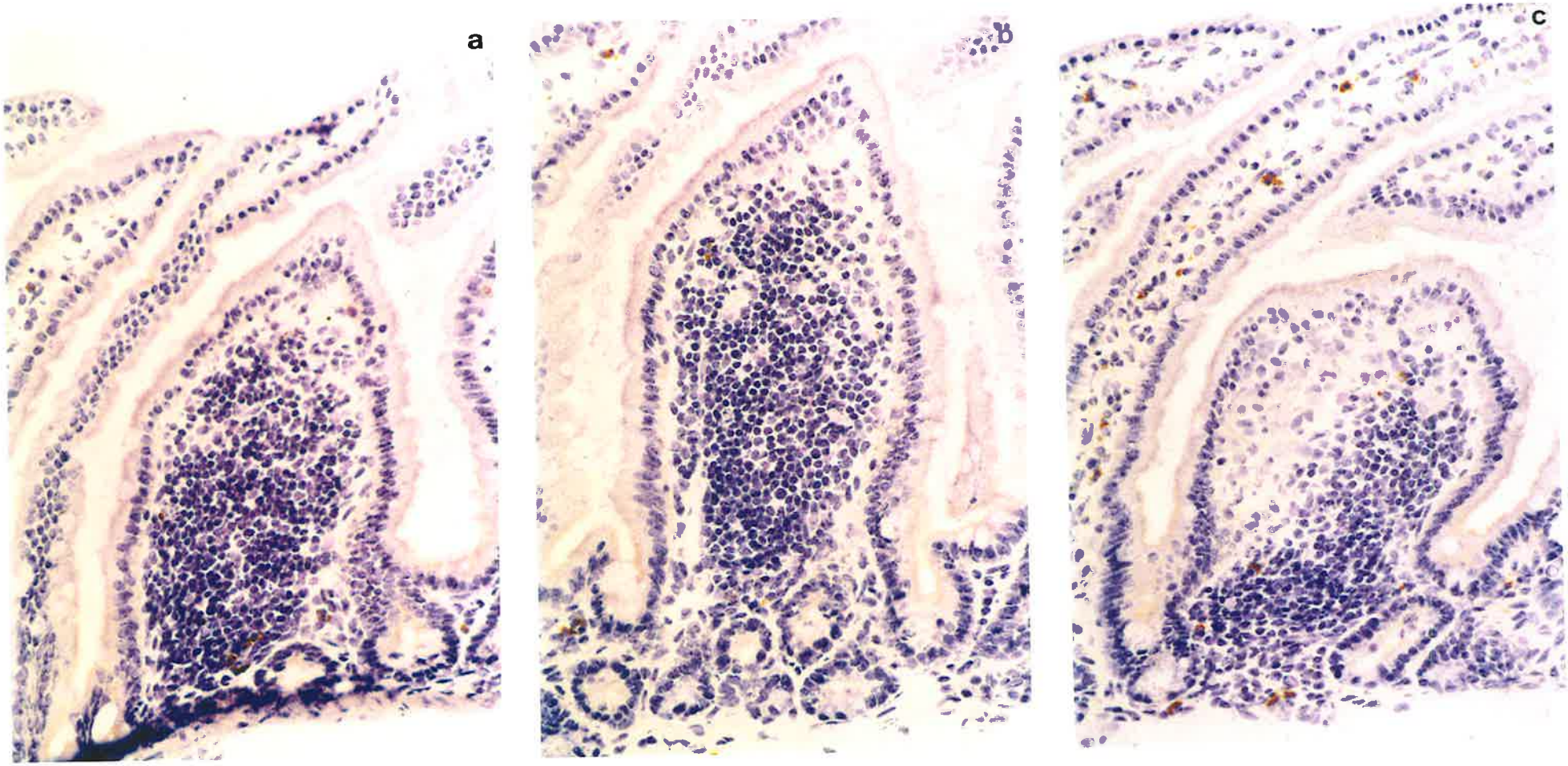
a
b
c

Figure 4.9

Frozen sections from the jejunum of a scid mouse, stained with monoclonal antibodies by the indirect immunoperoxidase technique. **a**- monoclonal antibody TIB 207 (anti-CD4), showing CD4 positive cells in the LFV. $CD4^+$ cells were rare in adjacent villi. **b**- monoclonal antibody YTS 169.4 (anti-CD8), showing scattered $CD8^+$ cells in the LFV and within the epithelium overlying both LFV and classical villi. Original magnification x 83.

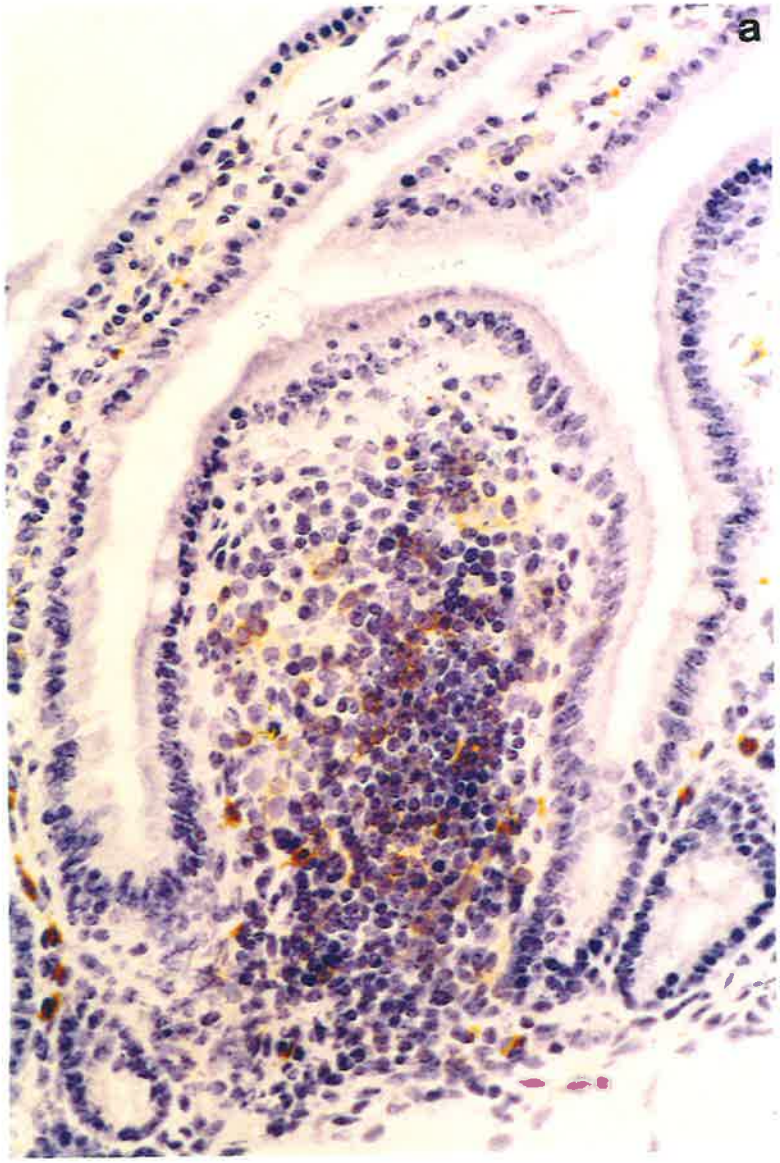
a

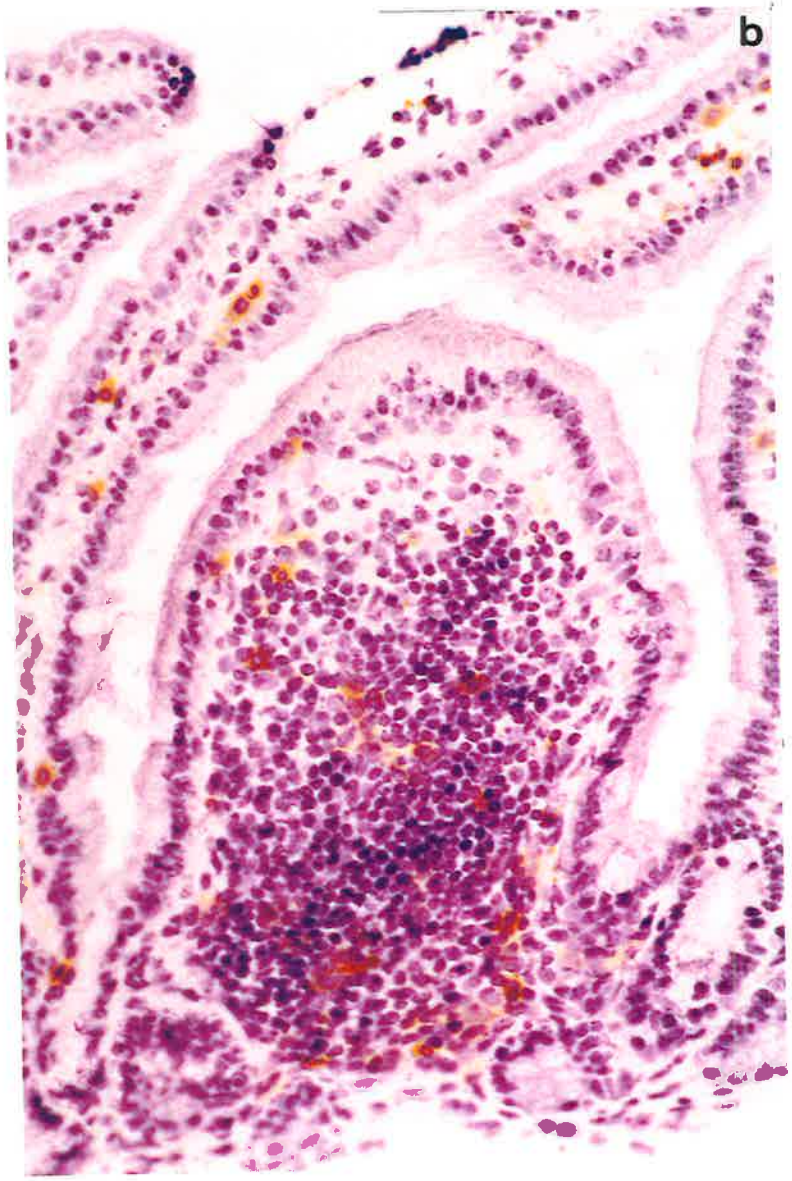
b

Figure 4.10

Frozen sections from the jejunum of a scid mouse, stained with monoclonal antibodies by the indirect immunofluoresence technique. **a**- section stained with mAb PC-61 (anti-CD25). **b**- section stained with mAb E3 81-204 (anti-Sca-2). Original magnification x 83.

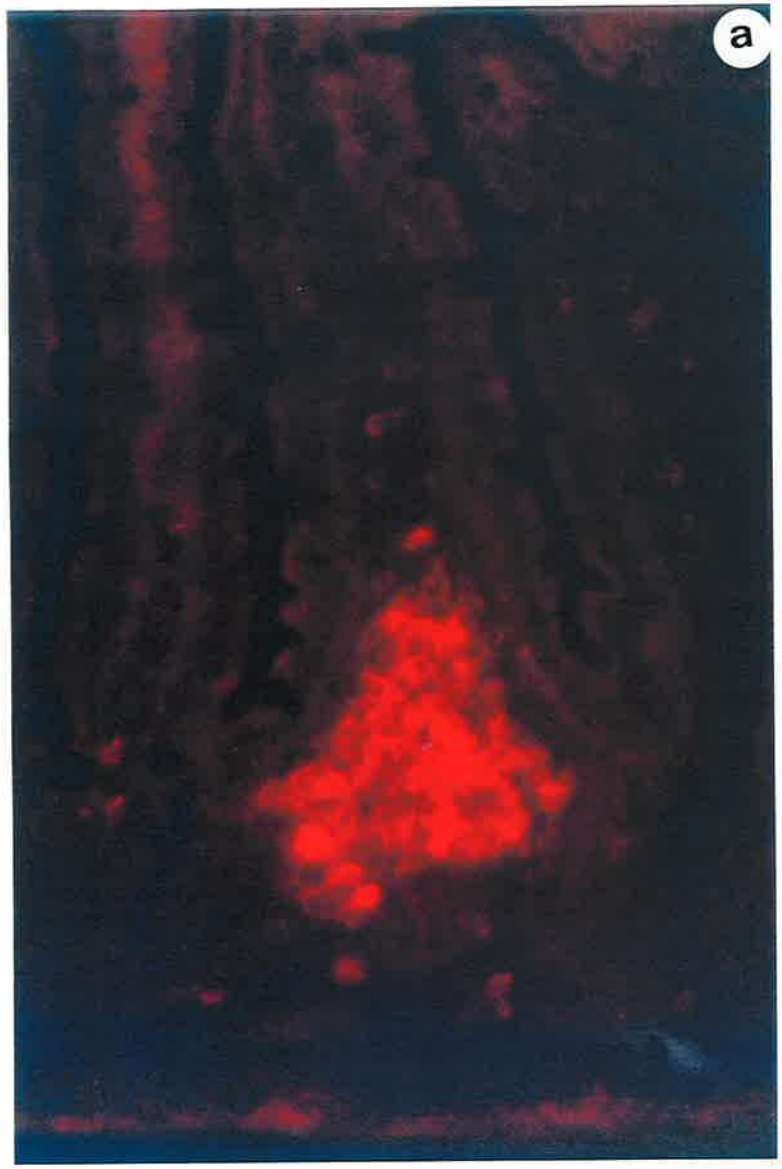
a

b

from normal mice and from the other mutants, small numbers of B220$^+$ cells were present (Fig 4.11a). None of the lymphocytes in LFV from RAG-1 gene knockout mice expressed surface Ig (Fig 4.11b) and only endogenous peroxidase activity was detected in cells in the lamina propria of adjacent villi.

Most of the lymphocytes in LFV from RAG-1 gene knockout mice expressed Thy-1 (Fig 4.12a) and CD45 molecules (Fig 4.12b). Furthermore, CD45$^+$ IEL were present in the epithelium overlying both LFV and classical villi. No cells were detected that expressed either CD3, $\alpha\beta$ TCR or $\gamma\delta$ TCR (Fig 4.13). Nevertheless, a population of CD4$^+$ cells was present in LFV from RAG-1 knockout mice, as described above in LFV from normal mice, scid mice and nude mice (Fig 4.14a). Occasional CD8$^+$ cells were detected within the LFV of RAG-1 gene knockout mice (Fig 4.14b) and within the epithelium overlying both LFV and classical villi, again as noted in normal mice and the above mutant mice.

Cells that expressed NK 1.1 were not detected in the LFV from RAG-1 gene knockout mice, although many NK 1.1$^+$ cells were observed in lamina propria of adjacent villi (Fig 4.15). Most of the lymphocytes in the centers and bases of LFV from these mice expressed CD25 (Fig 4.16a). The majority of cells in LFV were also labelled with mAb E3 81-204 (anti-Sca-2) (Fig 4.16b) and mAb MTS 35 (anti-TSA-1) (Fig 4.16c). The positive cells in adjacent villi appear to be dendritic cells, as evidenced by dual colour IF staining with the mAbs N418 plus E3 81-204 and N418 plus MTS 35 (see Chapter 3). The distributions of Sca-1$^+$, HSA$^+$ and Pgp-1$^+$ cells were similar to those in normal mice (Fig 4.17). It appears that Sca-1 is expressed mainly by non-lymphoid cells (Fig 4.17a), HSA is expressed by some lymphocytes and by non-lymphoid cells (Fig 4.17b) while Pgp-1 is expressed by most cells in the LFV (Fig 4.17c). The acquisition of surface Pgp-1 by mature T lymphocytes is a differentiation event linked to primary antigenic stimulation (Budd *et al.,* 1987). Therefore, the presence of Pgp-1$^+$ cells in scid and RAG-1 mutant

Figure 4.11

Photomicrographs of frozen sections of LFV in the jejunum of RAG-1 knockout mice. **a**- section stained with mAb RA3-6B2 (anti-B220). **b**- section stained with sheep anti-mouse Ig. Only eosinophils are stained. Original magnification x 83.

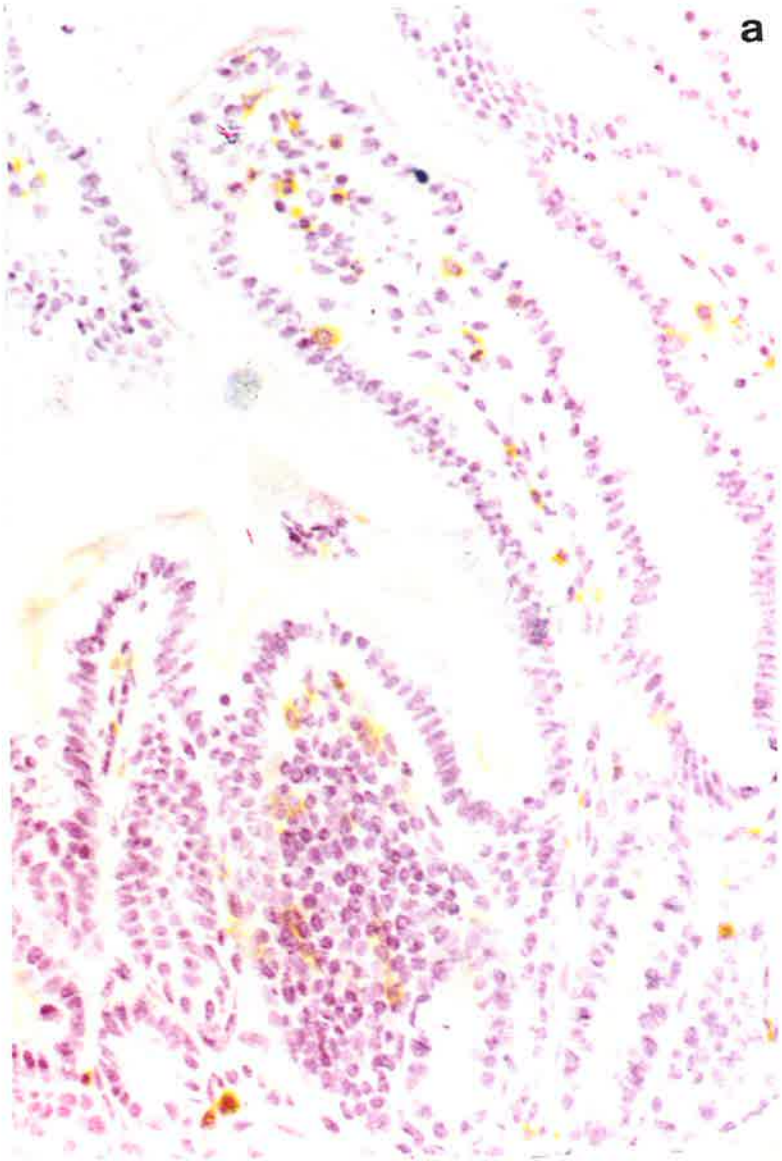
a

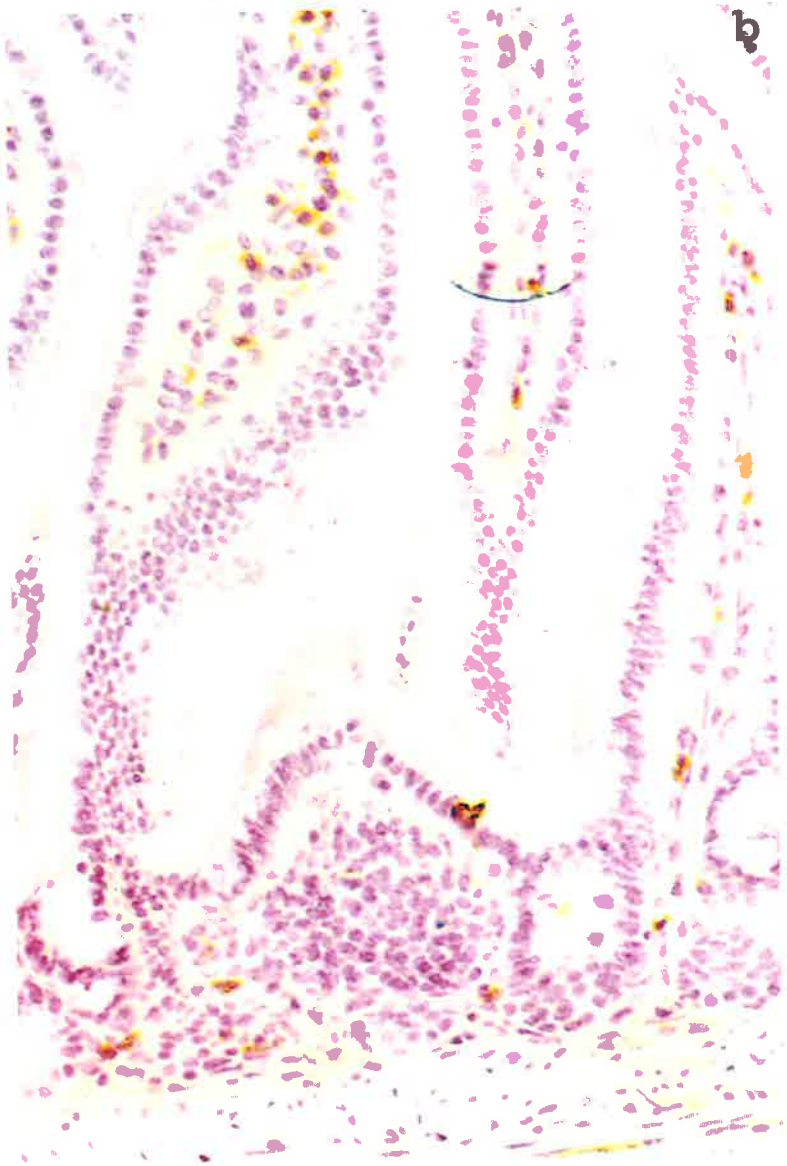
b

Figure 4.12

Photomicrographs of frozen sections of LFV in RAG-1 knockout mice. **a**- section stained with mAb TIB-107 (anti-Thy-1.2) (indirect immunofluorescence technique). **b**- section stained with mAb TIB-122 (anti-CD45) (indirect immunoperoxidase technique). Original magnification x 83.

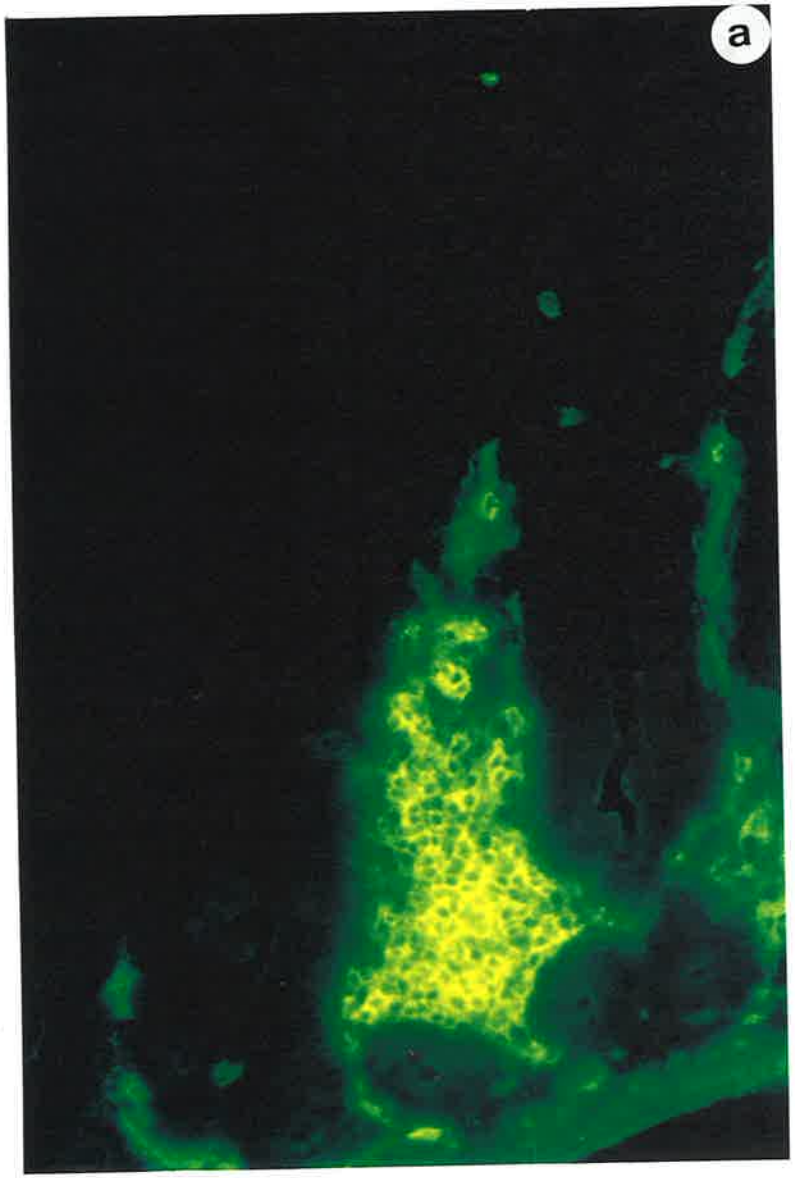
a

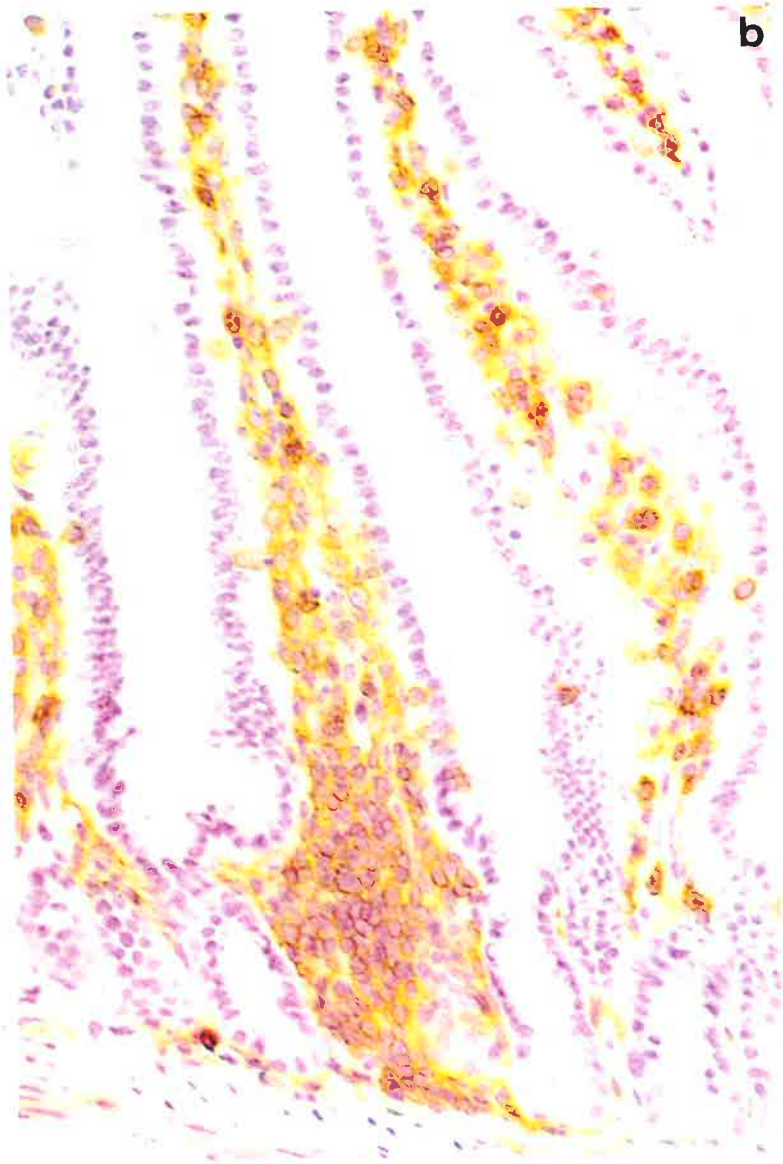
b

Figure 4.13

Serial frozen sections of LFV in the jejunum from a RAG-1 knockout mouse, stained with monoclonal antibodies by the indirect immunofluorescence technique. **a**- section stained with mAb 145-2C11 (anti-CD3). **b**- section stained with mAb H57-597 (anti-TCR α/β). **c**- section stained with mAb GL3 1A (anti-TCR γ/δ). Original magnification x 83.

a
b
c

Figure 4.14

Frozen sections of jejunum from RAG-1 knockout mice, stained with monoclonal antibodies by the indirect immunoperoxidase technique. **a**- monoclonal antibody TIB 207 (anti-CD4), shows the CD4 positive cells in the LFV. **b**- monoclonal antibody YTS 169.4 (anti-CD8), shows scattered $CD8^+$ cells in the LFV and within the epithelium overlying both LFV and adjacent villi. Original magnification x 83.

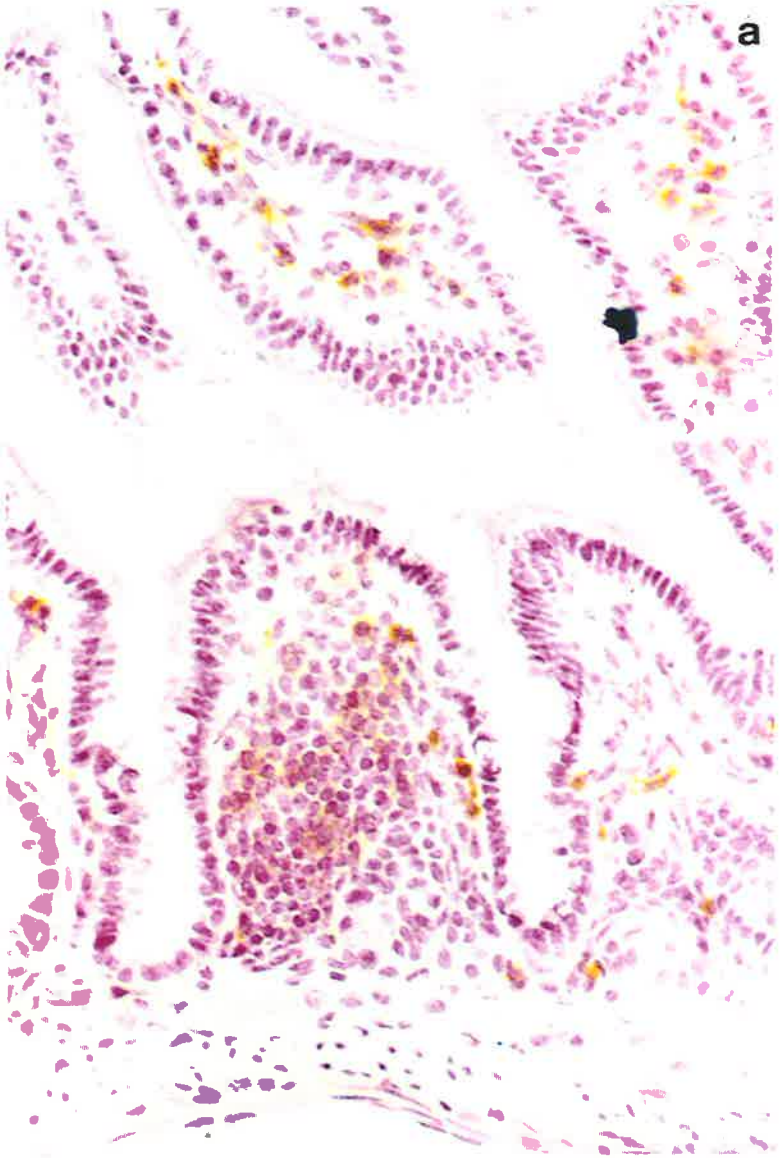
a

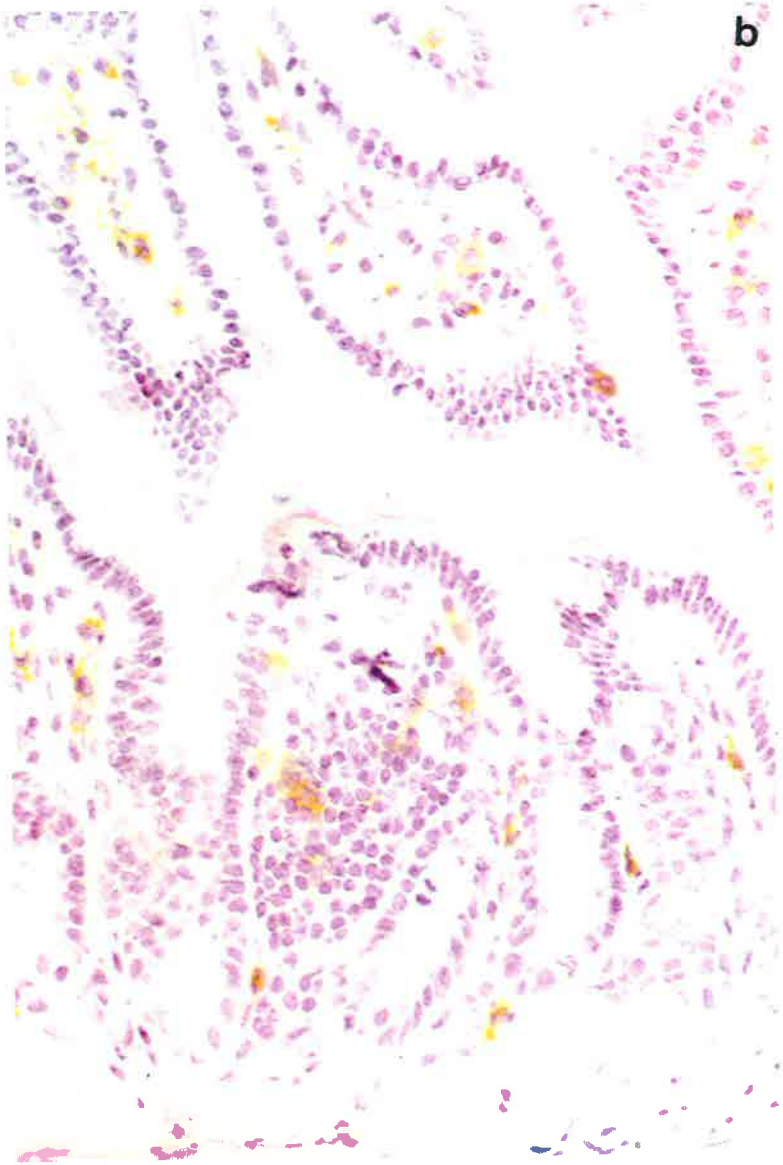
b

Figure 4.15

Frozen section of jejunum from a RAG-1 knockout mouse, stained with monoclonal antibody P136 (anti-NK 1.1) by the indirect immunofluorescence technique. Few NK 1.1 positive cells were detected in LFV but many positive cells were present in adjacent villi. Original magnification x 83.

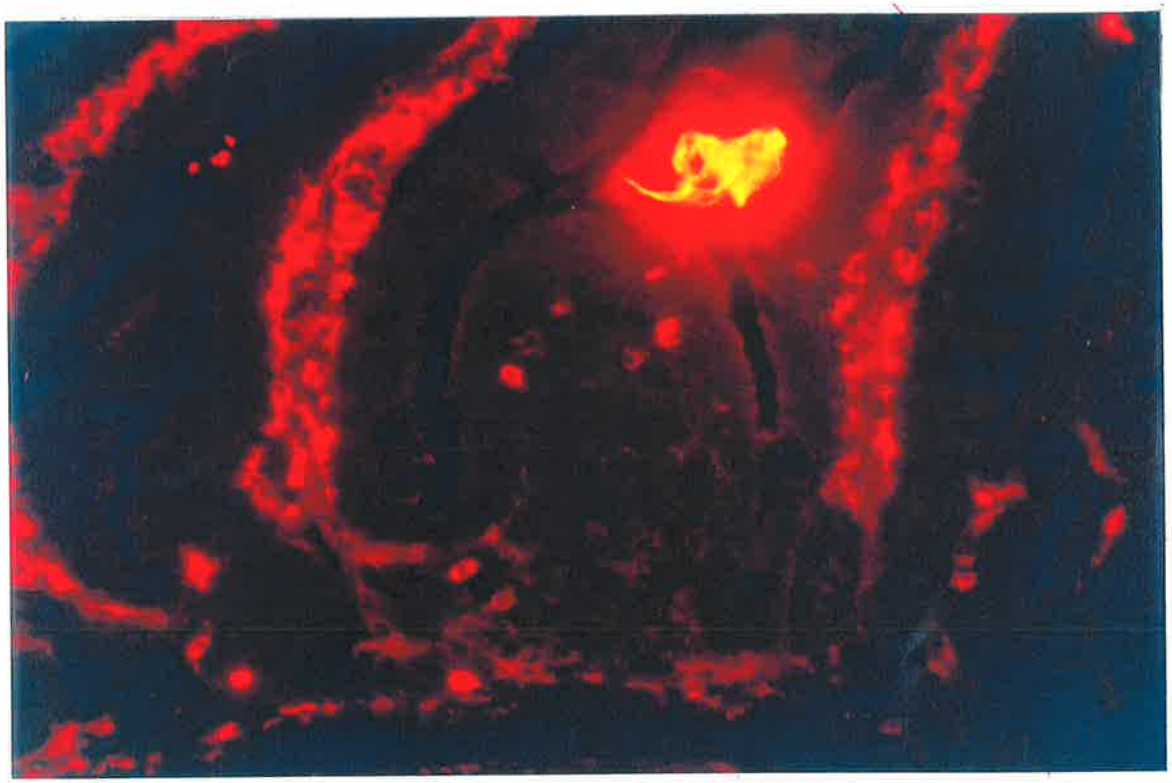

Figure 4.16

Frozen sections of LFV from RAG-1 knockout mice, stained with monoclonal antibodies by the indirect immunofluoresence technique. **a**- section stained with mAb PC-61 (anti-CD25). **b**- section stained with mAb E3 81-204 (anti-Sca-2). **c**- section stained with mAb MTS 35 (anti-TSA-1/Sca-2). Original magnification x 83.

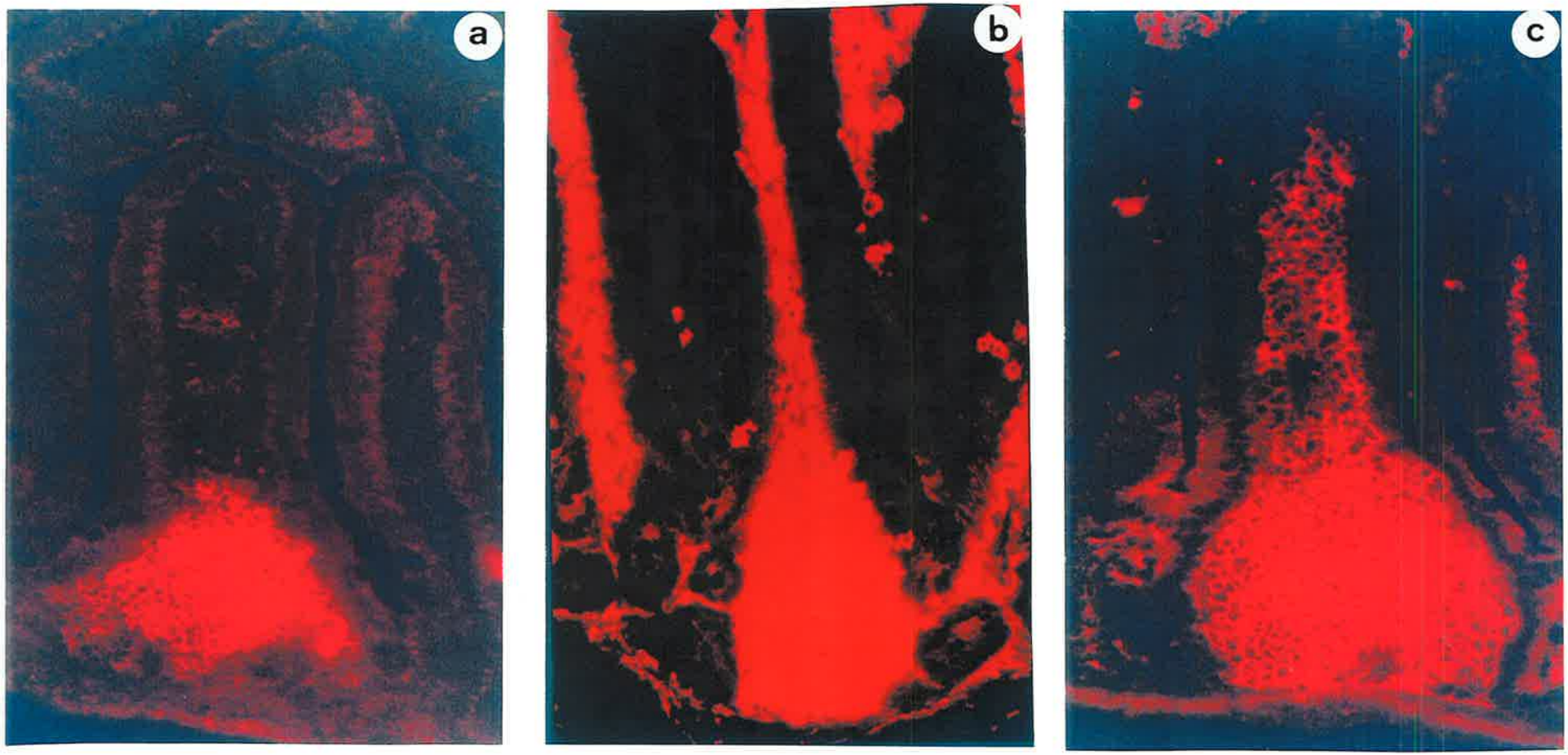
a
b
c

Figure 4.17

Frozen sections of LFV from RAG-1 knockout mice, stained with monoclonal antibodies by the indirect immunoperoxidase technique. **a**- section stained with mAb E13 161-7 (anti-Sca-1). **b**- section stained with mAb M1/69 (anti-HSA). **c**- section stained with mAb IM 7.8.1 (anti-Pgp-1). Original magnification x 83.

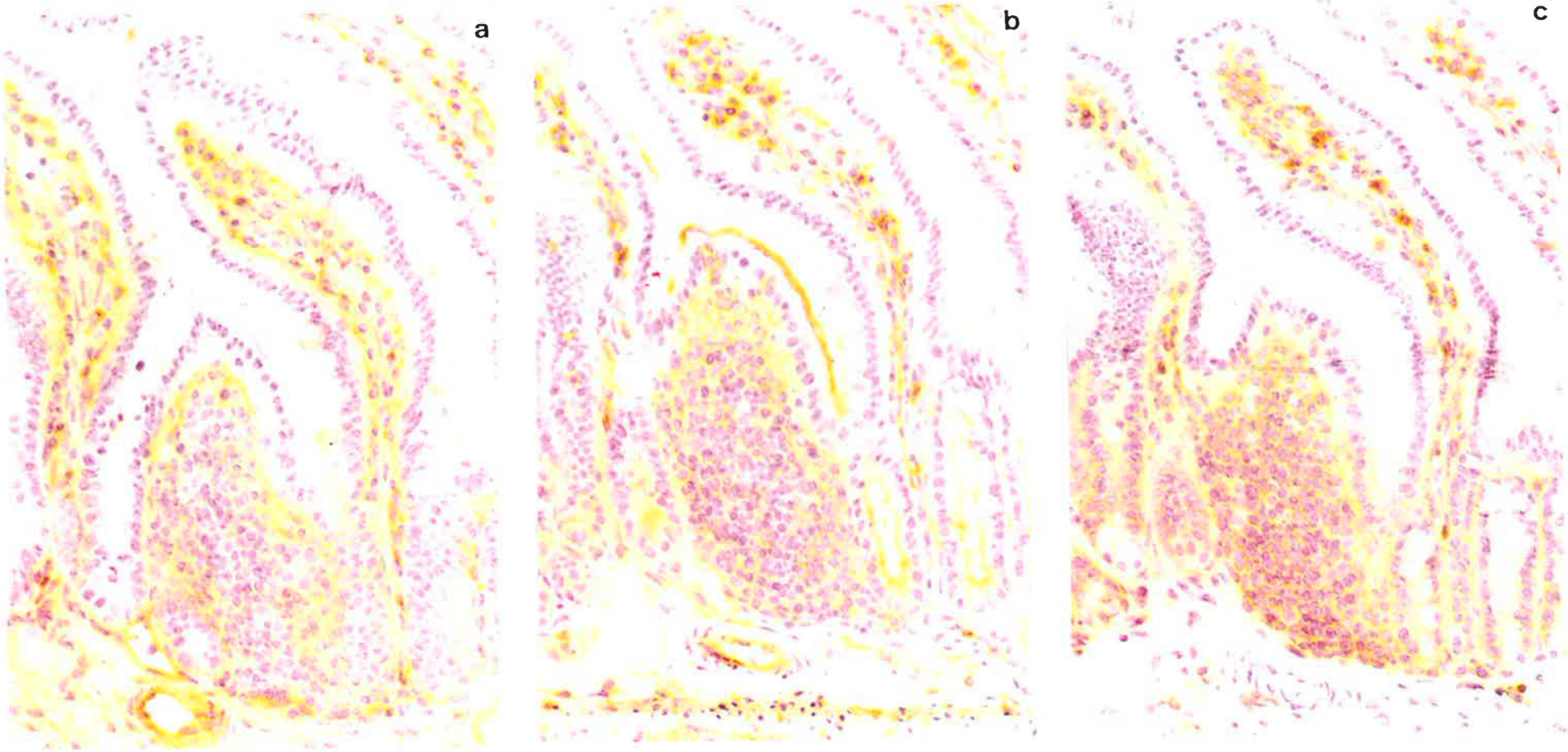
a
b
c

mice, which have no mature T cells, supports the view that the Pgp-1^{+} cells in these mice are immature. Monoclonal antibody MTS 32 (anti-TSA 2) stained a population of cells in the centers and bases of LFV (Fig 4.18a). As in nude mice, only occasional TSA 2 positive cells were detected in adjacent villi. The presence of TSA-2 positive cells in the LFV from RAG-1 gene knockout out mice is consistent with these cells being immature cells rather than mature T cells.

Monoclonal antibody MTS 33 stained large cells beneath the epithelium in LFV from RAG-1 knockout mice and occasional cells in adjacent villi (Fig 4.18b). Dual colour IF staining with MTS 33 and N418 mAbs (Chapter 3) has shown that most of MTS-33^{+} cells were either CD11c^{-} or CD11c^{lo}. As mentioned in Chapter 3, mAb MTS 37 appears to stain two cell types in LFV from normal mice. One of these consisted of large non-lymphoid cells in the sub-epithelial region. Double staining with mAbs MTS 37 and N418 (Chapter 3) indicated that while most dendritic cells in the LFV had the phenotype MTS 37^{-}CD11c^{+}, this sub-epithelial population expressed a MTS37^{+}CD11c$^{-/lo}$ phenotype. The other cell type consisted of lymphocytes and these also occupied the sub-epithelial region of the LFV. In the RAG-1 gene knockout mice, only the non-lymphoid cells sub-epithelial were stained by mAb MTS 37 (Fig 4.18c). As in normal mice, mAb MTS 20 stained the majority of non-lymphoid cells under the epithelium in LFV (not shown)

As in normal mice, CD11c^{+} cells were observed, in the subepithelial areas of LFV and scattered between the lymphocytes at the centers and bases of these structures (Fig 4.19).

Figure 4.18

Photomicrographs of frozen sections of LFV in the jejunum of RAG-1 knockout mice. **a,b**- sections stained with mAbs MTS 32 and MTS 33 (indirect immunofluorescence technique). **c**- section stained with mAb MTS 37 (indirect immunoperoxidase technique). Original magnification x 83.

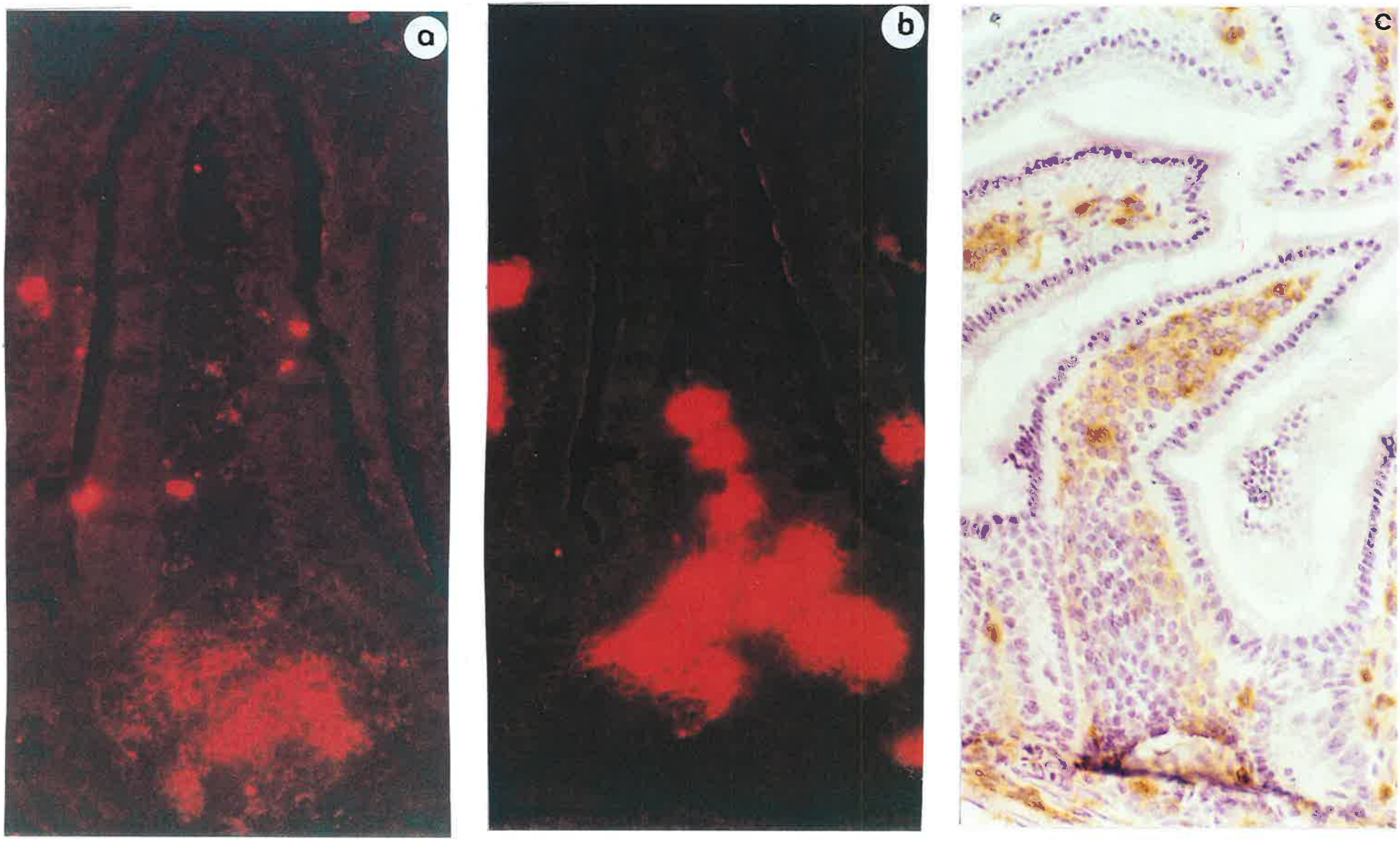
a
b
c

Figure 4.19

Frozen sections of LFV from RAG-1 knockout mice, stained with monoclonal antibody N418 (anti-CD11c) by the indirect immunoperoxidase technique shows many positive cells particularly in the sub-epithelial area of LFV and scattered between the lymphocytes at the center and base of LFV. Original magnification x 83.

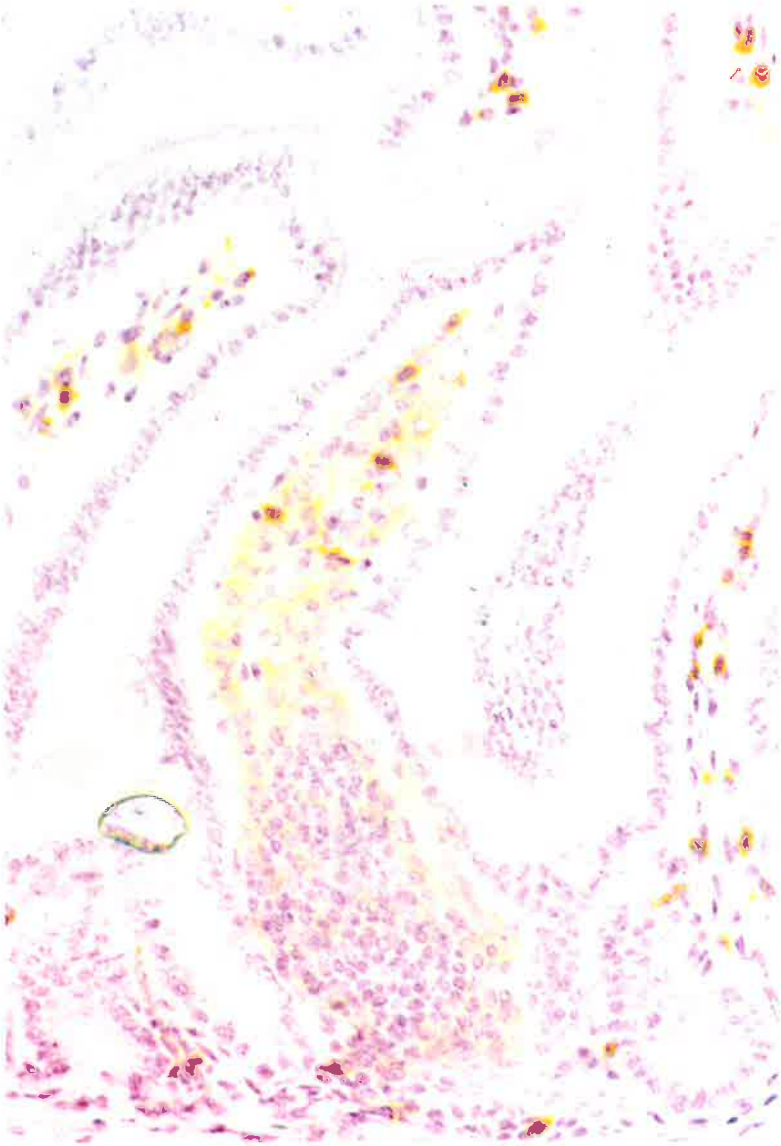

4.5 DISCUSSION

The results presented in this Chapter suggest the existence of at least three subsets of lymphocytes in LFV from the mutant (nude, scid, RAG-1 gene knockout) mice. These were Thy-1$^+$, TCR$^-$, CD3$^-$, CD4$^-$, CD8$^-$; Thy-1$^+$, TCR$^-$, CD3$^-$, CD4$^+$, CD8$^-$ and Thy-1$^+$, TCR$^-$, CD3$^-$, CD4$^-$, CD8$^+$. However, while CD4$^+$ cells were more numerous than CD8$^+$ cells and the fist two subsets undoubtedly exist, it cannot be excluded that some CD4$^+$CD8$^+$ double-positive cells are present. This question is addressed in Chapter 5. The presence of similar subsets of lymphocytes in LFV from the normal mice and the mutant mice indicates that the lymphocytes in these structures are generated without requirement for a thymic microenvironment and that the major population of lymphoid cells in LFV do not require antigen -receptor gene rearrangement for their development.

As in normal mice, most of the lymphocytes in LFV from the mutant mice expressed Thy-1 antigen. Most of these cells expressed the phenotype Thy-1$^+$, CD25$^+$, TCR$^-$, CD3$^-$, CD4$^-$, CD8$^-$. Co-expression of the Thy-1 antigen and the α chain of the IL-2 receptor is characteristic of cells that are at the triple negative stage of T cell development in the thymus (Shinkai *et al.,* 1992). While this population comprises a small proportion (4%) of thymocytes in wild type mice, it makes up a major fraction (40%) of the cells in the thymuses of RAG-2$^{-/-}$ mutant mice (Shinkai *et al.,* 1992). Similarly, in scid mice and RAG-1 gene knockout mice, thymocytes do not develop beyond the CD3$^-$CD4$^-$CD8$^-$ triple negative, IL-2R$^+$ stage (Shores *et al.,* 1990; Mombaerts *et al.,* 1992; Godfrey *et al.,* 1994). Therefore, the presence of Thy1$^+$CD25$^+$ cells as a major population in LFV from scid mice and RAG-1 gene knockout mice is consistent with these cells representing an early stage of T cell differentiation. The presence of other markers of immature T cells, such as Sca-2 (TSA-1), HSA, Pgp-1 and TSA-2 in LFV from the mutant mice supports this view. The biological properties of these cells will be discussed in Chapter 5.

It is interesting that the numbers of $B220^+$ cells in LFV from both normal and the mutant mice were greater than the numbers of surface Ig^+ cells. It can be argued that the $B220^+$ cells (particularly in RAG-1 gene knockout mice) are not B cells but immature T cells that express B220 molecule. $B220^+$ DN thymocytes constitute 6% of thymocytes in 6-week old C56Bl/6 mice (Gause *et al.*, 1988). The origin of these cells in the thymus has not been identified conclusively. However, it has been shown that the development of $B220^+$ DN T cells is dependent on the expression of MHC class 1, as demonstrated by the use of MHC class 1-deficient $\beta2\text{-}m^{-/-}$-lpr mice (Giese & Davidson, 1995). In Chapter 3, it was shown that the $B220^+$ cells in LFV were not dendritic cells as they did not express CD11c molecule. Further observations on the B220 positive cells are described in Chapter 5.

As mentioned in Chapter 3, a small population of lymphocytes in LFV from normal mice expressed the CD4 molecule. This subset was also present in LFV from nude mice, scid mice and RAG-1 gene knockout mice. The presence of $CD4^+$ cells in the mutant mice indicates that they are thymus-independent and that they are at a stage of differentiation that either does not require re-arrangement of TCR genes or precedes re-arrangement of these genes. Primitive T cell progenitors that express low levels of CD4 have been reported in the adult thymus (Wu *et al* , 1991a). This subset is thought to represent committed lymphoid stem cells that seed the thymus from bone marrow (Wu *et al.*, 1991a; Wu *et al.*, 1991b; Ardavin *et al.*, 1993; Wu *et al.*, 1996). The $CD4^+$ lymphocytes in LFV may be equivalent to this precursor population in the thymus. This subset will be discussed further in Chapter 5.

Finally, some deductions can be made about the maturation sequence of the lymphocytes in LFV. As mentioned in Chapter 3, mAb MTS 37 recognized both non-lymphoid cells that are located mainly beneath the epithelium and also a population of lymphocytes that is located among these non-lymphoid cells in the sub-epithelial region.

In the LFV from the mutant mice, the population of MTS 37^+ lymphocytes was missing. Based on expression of the MTS 37 antigen and CD25, there are two subsets of lymphocytes in LFV from normal mice. These are MTS 37^- $CD25^+$ and MTS 37^+ $CD25^-$ (see Chapter 3). Because MTS 37^+ $CD25^-$ lymphocytes are absent in the mutant mice, it may represent the more mature subset. This raises the intriguing possibility that the transition from MTS 37^- $CD25^+$ to the MTS 37^+ $CD25^-$ phenotype is dependent on, or concomitant with, re-arrangement of the genes encoding the TCR. This population of lymphocytes will be discussed further in Chapter 5.

CHAPTER 5

FURTHER CHARACTERIZATION OF THE LYMPHOCYTES IN LFV BY DUAL COLOUR IMMUNOFLUORESCENCE AND OTHER BIOLOGICAL PROPERTIES

5.1 INTRODUCTION

Phenotypic analysis of lymphocytes in LFV from normal mice revealed that most of the cells expressed Thy1 antigen. Numerically, most of these cells must have the phenotype Thy 1^+, TCR^-, $CD3^-$, $CD4^-$. However, there must also be a substantial population of cells with the phenotype Thy 1^+, TCR^-, $CD3^-$ $CD4^+$ and a smaller sub-population with the phenotype Thy 1^+, TCR^- $CD3^-$ $CD8^+$. However, with studies of only single markers, it is impossible to deduce whether expression of antigens such as CD4 and CD8 occur on distinct sub-populations or whether they are co-expressed by some cells. Furthermore, even with a widely expressed antigen such as Thy1, it is possible that small sub-populations of $Thy1^-$ are also present in LFV. This problem is confounded further by the addition of other mAb to the panel of reagents used to detect lymphocyte surface antigens. For instance, the lymphocytes that were located mainly in the centers and bases of LFV expressed the markers CD25, Sca-2, TSA-1, HSA, Pgp-1 and TSA-2. Given that isolation of lymphocytes from LFV in sufficient qualities for flow cytometric analysis is not technically possible at present, studies in *situ* with dual colour immunofluorescence provided an approach to examining the co-expression of key markers in T cell development.

A comparable pattern of lymphocyte phenotypes was observed in the LFV from mutant mice. The presence of essentially similar LFV in normal and in nude mice indicates that the lymphocytes in these structures are generated without requirement for a thymic microenvironment. Furthermore, the presence of similar subsets of lymphocytes in LFV from scid and RAG-1 mutant mice, which lack functional T cells (Schuler *et al.*, 1986; Mombaerts *et al.*, 1992), points to the fact that the lymphocytes in LFV do not have an obligatory requirement for the activities of classical T cells for their development. The cells in LFV appear to complete their normal development without expressing detectable

levels of re-arranged TCR gene products. This is an important difference between LFV in rats (which contain a significant population of $\alpha/\beta TCR^+$ cells) and mice and it poses the interesting dilemma that if LFV in mice are sites of extra-thymic T cell differentiation, then cells are exported prior to rearrangement of TCR genes or they exit from LFV immediately after this process has commenced.

One interesting difference between the lymphocytes in the LFV from normal Balb/c mice and those in the LFV from the mutant (nude, scid and RAG-1 gene knockout) mice was the expression of the MTS 37 antigen. While most lymphocytes in the central and basal regions of LFV from normal mice were MTS 37^-, those in the outer subepithelial regions expressed MTS 37 antigen. This MTS 37^+ sub-population of lymphocytes was absent in the LFV from the mutant mice. The MTS 37^+ lymphocytes in the outer-regions may, therefore, be more mature than the lymphocytes in the center of the LFV. In addition, mAb MTS 37 stained a stromal cell population in the subepithelial and basal region of the LFV. These cells are identified tentatively as dendritic cells but further work is required to exclude a possible epithelial origin. In T cell-deficient mutant mice, mAb MTS 37 stained only the large cells beneath the epithelium in LFV. It is an interesting question, therefore, as to whether expression of the MTS 37 antigen is dependent on successful rearrangement of TCR genes in the developing lymphocytes in the LFV or whether it depends on the activities of classical T cells. The absence of the MTS 37^+ sub-population in nude mice as well as in scid mice and RAG-1 gene knock-out mice suggests that expression of the MTS 37 antigen is regulated by classical thymus-derived T cells.

The work described in this Chapter, characterizes further the surface antigen phenotype of the cells in LFV by dual colour immunoflurescence. It also examines some other biological properties associated with development of classical T cells. These

include sensitivity of the lymphocytes in LFV to corticosteroids, cell division and expression of immuno-reactive RAG-1 enzyme protein.

5.2 FURTHER CHARACTERIZATION OF CELL SURFACE MARKERS BY DUAL COLOUR IMMUNOFLUORESCENCE

A $CD4^+$ subset, representing the earliest T precursor cells in the adult mouse thymus, is reported by Wu *et al.*(1991a). This population has been shown to share a number of surface antigens with bone marrow haematopoietic stem cells. Within the thymus, these cells express Sca-2 and many are in cell-cycle (Wu *et al.,* 1991a). These authors believe that this Sca-2^+ $CD3^-$ $CD4^+$ $CD8^-$subset is less mature than the established $CD3^-$ $CD4^-$ $CD8^-$ precursors, both in their ability to reconstitute the thymus and in their status of TCR gene-rearrangement (Wu *et al.,* 1991a). When this population was transferred intravenously into lethally irradiated mice, it displayed the capacity to develop into both B and T lymphoid cells but it did not possess myeloid or erythroid precursor activity. These observations suggested that the Sca-2^+ $CD4^+$ cells are lymphoid-committed stem cells (Wu *et al.,* 1991b). Interestingly, these $CD4^+$ precursors can also generate thymic dendritic cells (Ardavin *et al.,* 1993). Although the CD4 molecule is usually considered a marker of more mature T cells, it also expressed by a proportion of mouse bone marrow cells (Wineman *et al.,* 1992; Antica *et al.,* 1994).

In the light of these observations on progenitor cells in the thymus, it was of interest to determine the nature of the $CD4^+$ cells in LFV. As mentioned above, these cells were thymus-independent as shown by their presence in athymic nude mice. If they are indeed T cell progenitors, they are at a stage of differentiation that does not require expression of re-arranged TCR genes or CD3. The presence of $CD4^+$ cells in the classical villi of nude mice and their absence in both scid and RAG-1 mutant mice suggests that under normal conditions, the $CD4^+$ cells in LFV might progress to the expression of a

TCR at other anatomical sites and that these structures may be one source of extra-thymically-derived committed T cell progenitors.

To examine the co-expression of other differentiation antigens by the $CD4^+$ cells in LFV, dual-colour immunofluorescence analysis was performed in RAG-1 gene knockout mice. These mice that have no mature T or B cells and are , therefore, an ideal model in which to study the $CD4^+$ presumptive progenitor cells. The following antigens were examined by the use of appropriate combinations of mAbs; CD8/CD4; Sca-2/CD4; TSA-1/CD4; CD25/CD4; TSA-2 (MTS32)/CD4; B220/CD4 and CD11c/CD4. In each case, anti-CD4 was a biotin-conjugated mAb RM4-5 was revealed by a streptavidin-phycoerythrin (PE) conjugate, while the other primary mAb was detected indirectly with an FITC conjugate of $F(ab')_2$ rabbit anti-rat Ig. Specific staining with the antibodies in the indirect technique could be differentiated easily from a low level of background staining obtained with control sections incubated with PBS plus 10% normal mouse serum in place of the primary antibodies. With the system of filters used in this study, phycoerythrin-labelled cells appeared red on single exposure, orange/yellow on double exposure and yellow when photographed through the FITC filters alone. FITC-labelled cells appeared apple green when photographed using the FITC filters alone or on double exposure and were not visible when photographed via the TRITC filters. Dual labelled cells were lemon yellow when photographed sequentially through each set of filters by double exposure.

Double staining with mAbs RM4-5 (anti-CD4) and YTS 169.4 (anti-CD8) revealed that only rare double positive (lemon yellow) $CD4^+CD8^+$ cells were present in LFV (Fig 5.1). Most of the cells within the LFV were single positive $CD4^+$ (orange/yellow). A small number of single positive $CD8^+$ cells (green) were present within the LFV and these cells were also present in the overlying epithelium of both LFV and classical villi. As mentioned earlier, only rare cells in LFV were $CD3^+$ or TCR^+.

Figure 5.1

Two-color immunofluorescent staining of LFV from a RAG-1 knockout mouse using mAb RM4-5 (anti-CD4, PE) in combination with mAb YTS 169.4 (anti-CD8, FITC). Occasional double positive $CD4^{+}CD8^{+}$ cells in LFV (arrow)· Original magnification x 83.

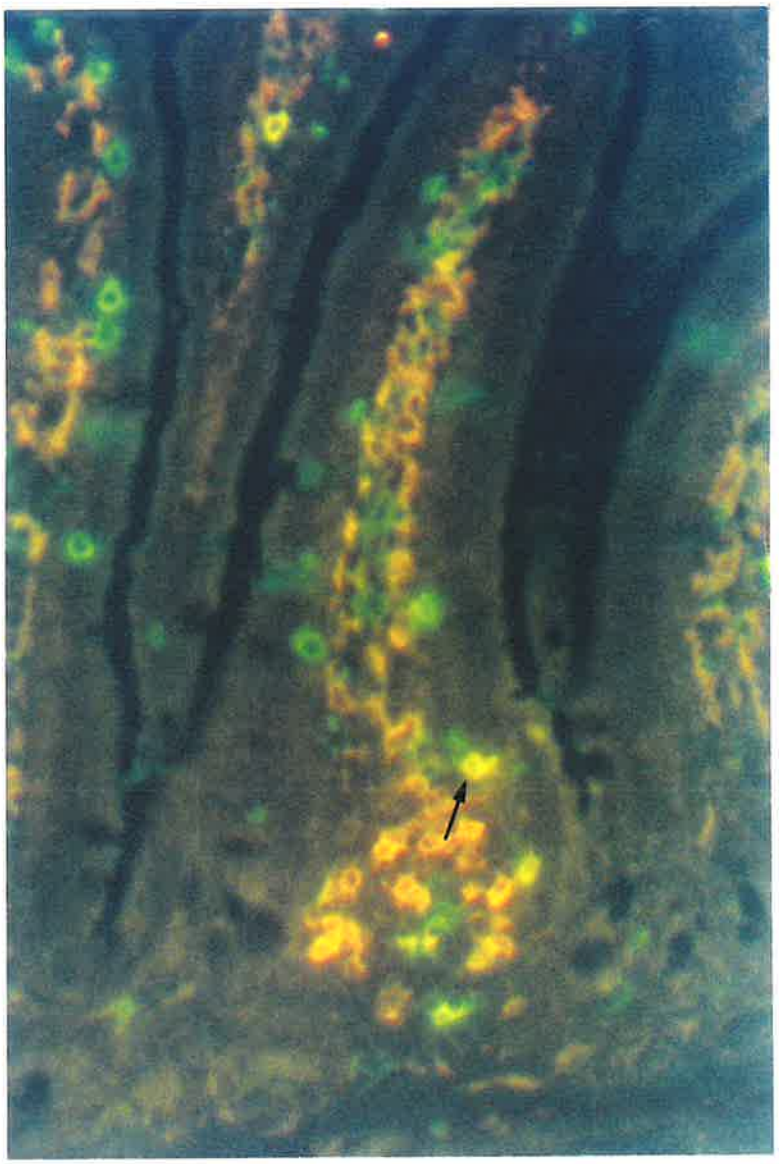

Therefore, the single positive $CD4^+$ and $CD8^+$ cells in LFV differ from mature $CD4^+8^-$ or $CD4^-8^+$ lymphocytes found in the periphery and most single positive cells in the thymus by the absence of surface TCR/CD3 complex.

Dual-colour staining using mAb RM4-5 (anti-CD4) in combination with either mAb E3 81 204 (anti-Sca-2) or MTS35 (anti-TSA-1/Sca-2) indicated that the $CD4^+$ cells in LFV also expressed Sca-2 (Fig 5.2a-c). Similarly, when combined with mAb PC-61, $CD4^+$ cells in LFV were found to co-express CD25 (Fig 5.2d-f). However, simultaneous staining with mAbs RM4-5 and MTS-32 showed that $CD4^+$ cells did not bear the TSA-2 molecule (Fig 5.3a).

The B220 isoform of the CD45 molecules is a marker of the B cell lineage (Coffman & Weissman, 1981b). However, it is also expressed by a subset of normal thymocytes (Gause *et al.*, 1988). $B220^+$ thymocytes constitute 6% of DN cells in the adult mouse thymus. The B220 isoform of CD45 is also expressed by the $CD4^-$ $CD8^-$ TCR $\alpha\beta^{intermediate}$ T cells found in the livers of mice homozygous for the lpr mutation (Huang *et al.*, 1994) and by both double negative $CD4^-CD8^-$ and single positive $CD4^+$ T cells in β_2-$m^{-/-}$-lpr mice (Giese & Davidson, 1995). In LFV, the numbers of B220 positive cells appeared to be greater than the numbers of sIg^+ cells. In order to investigate whether the $CD4^+$ cells in LFV express B220, dual-colour immunofluorescence analysis was carried out using mAb RM4-5 in combination with mAb RA3-6B2 (anti-B220). Most of the $CD4^+$ cells in LFV did not express the B220 isoform of CD45 (Fig 5.3b).

Mouse thymic dendritic cells express very low levels of CD4 (Vremec *et al.*, 1992). Moreover, a distinct sub-population of human thymic dendritic cells expresses high levels of CD4 (Sotzik *et al.*, 1994). To consider the possibility that some $CD4^+$ cells in LFV might be dendritic cells, a dual-colour analysis was carried out using mAb RM4.5

Figure 5.2

Frozen sections of jejunum from RAG-1 gene knockout mice, stained with monoclonal antibody RM4-5 (PE) in combination with either mAb E3 81-204 (FITC) or PC-61 (FITC). **a-c**, mAbs E3 81-204 (anti-Sca-2) and RM4-5 (anti-CD4), **d-f**, mAbs PC-61 (anti-CD25) and RM4-5 (anti-CD4). **a-** double exposure for FITC and PE· **b-** single exposure for PE· **c-** single exposure for FITC. **d-** double exposure for FITC and PE. **e-** single exposure for PE· **f-** single exposure for FITC (signal amplification). Original magnification x 83.

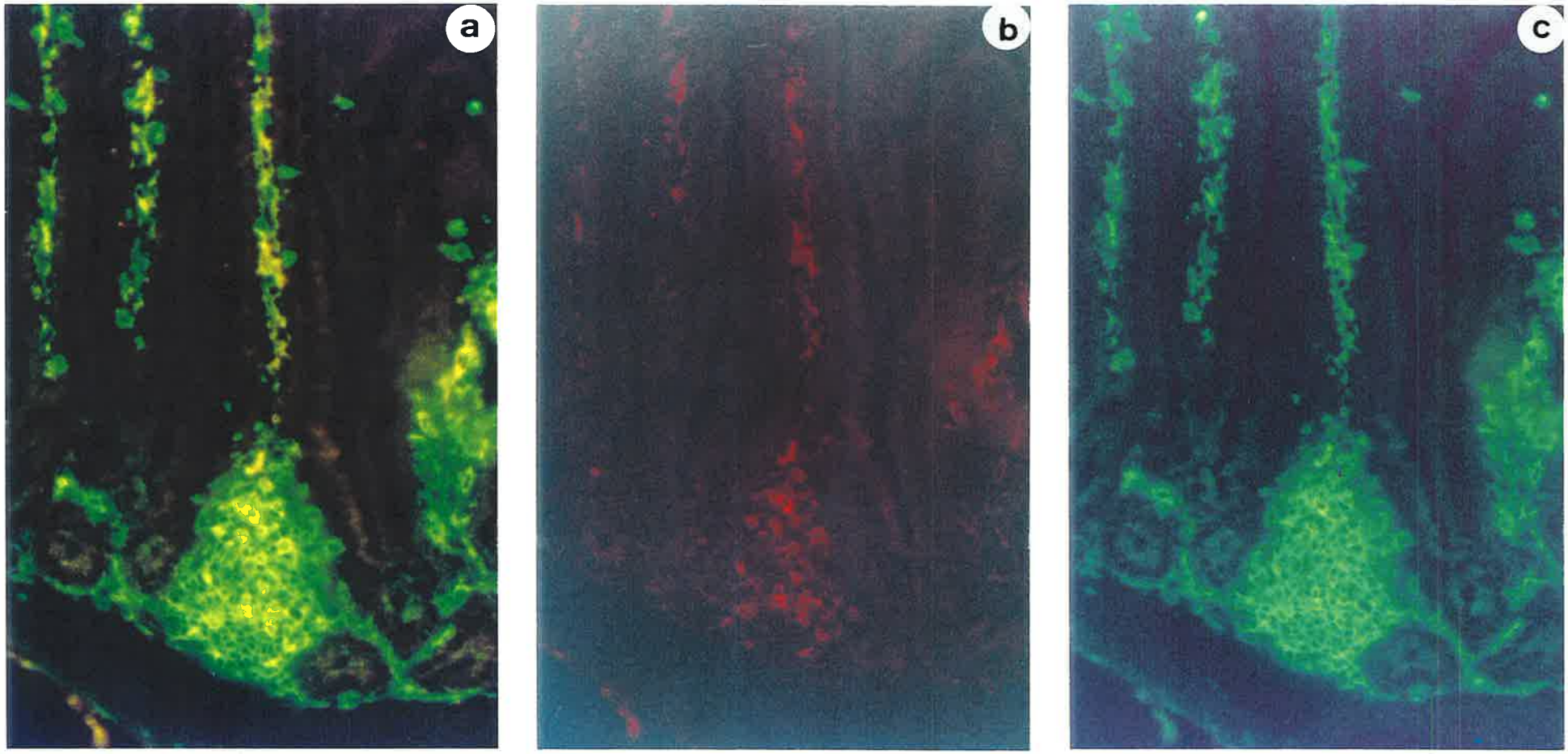
a
b
c

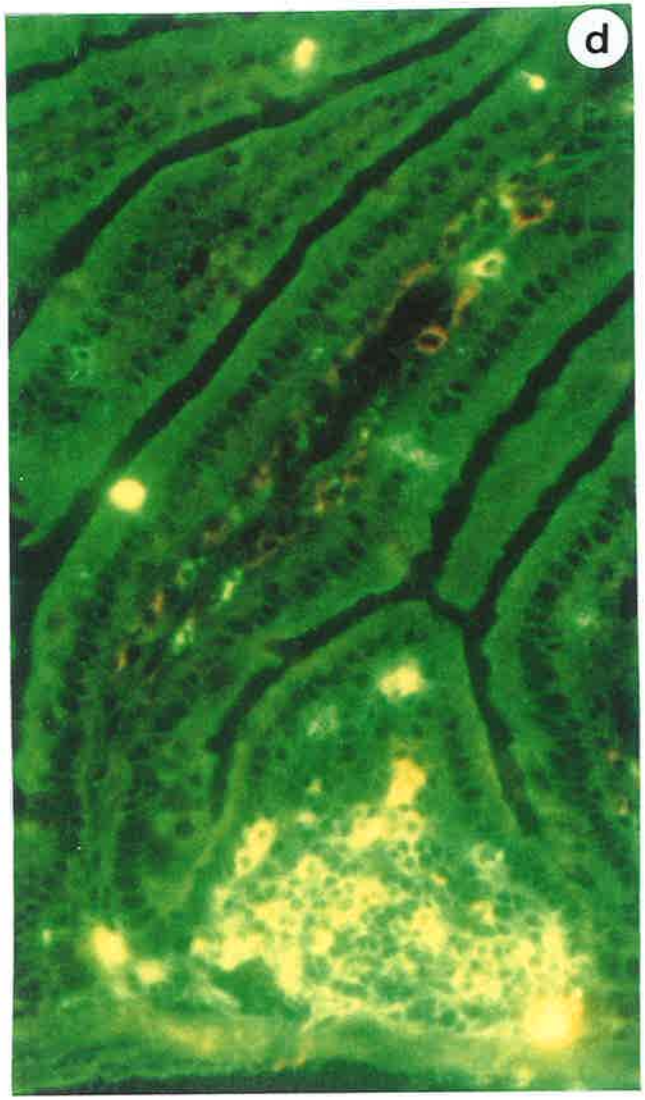
d

e

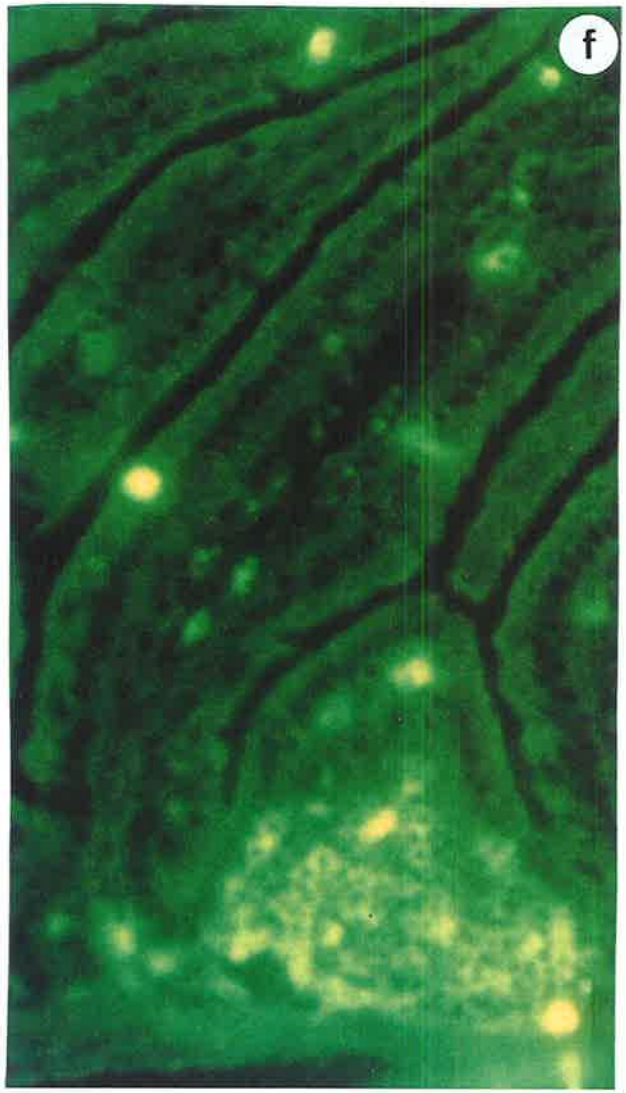
f

Figure 5.3

Frozen sections of LFV from RAG-1 gene knockout mice, stained with monoclonal antibody RM4-5 (anti-CD4) in combination with MTS 32 (anti-TSA-2), RA3-6B2 (anti-B220) and N418 (anti-CD11c). **a-** mAb MTS 32 (FITC, signal amplification) plus mAb RA4-5 (PE). No double positive $CD4^{+}TSA\text{-}2^{+}$ cells. **b-** most of the labelled cells express either CD4 or B220 but only 1 (arrow) expresses both antigens. **c-** this section contained only a few $CD4^{+}$ cells (arrow). However, CD11c-positive cells did not express CD4. Original magnification x 83.

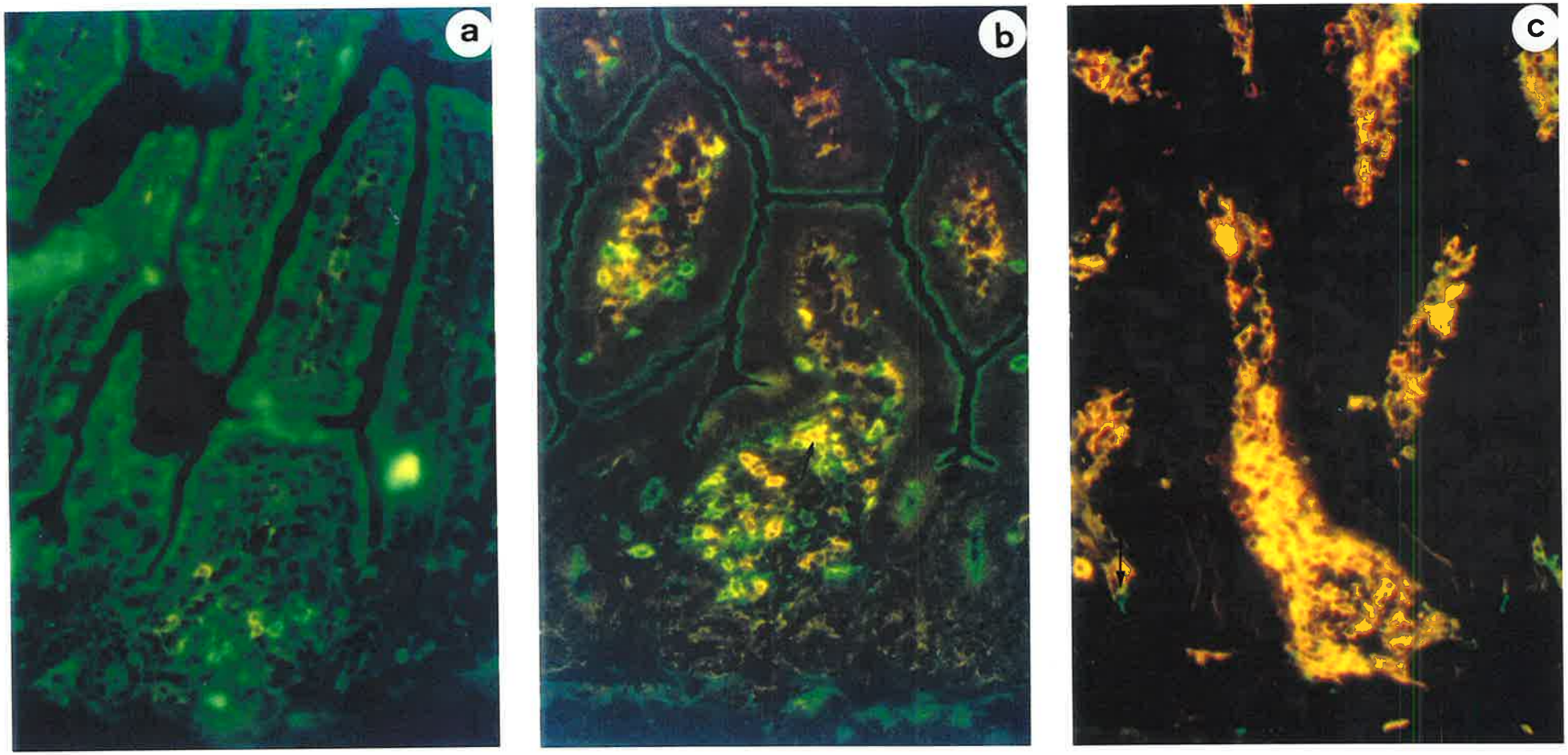
a
b
c

in combination with mAb N418 (anti-CD11c). No correlation was observed between the expression of these two markers (Fig 5.3c).

The results of double staining suggest that the $CD4^+$ cells in LFV were neither mature T cells, double positive ($CD4^+CD8^+$) T cells nor dendritic cells. In addition, they did not express either the TSA-2 or the B220 molecules. They may be, therefore, a distinct subset of lymphocytes that expresses markers such as Sca-2, TSA-1 and IL-2Rα that are also expressed by T cell progenitors in the thymus. These cells are possibly equivalent to the committed lymphoid progenitors in the thymus.

5.3 CORTISONE RESISTANCE OF LYMPHOCYTES IN LFV

Immature thymocytes are cortisone sensitive (Hugo *et al.,* 1990). Injection of mice with cortisone results in pyknosis of cortical thymocytes within 24 hours, with only minimal effect on medullary thymocytes (Weissman, 1973). Moreover, it has been shown that by 36 hours after cortisone treatment, the immature thymocytes are depleted and the thymus contains a large number of single positive cells that express either CD4 or CD8 (Godfrey *et al.,* 1992). This confirmed earlier work which showed that cortisone resistant thymocytes (CRT) are mainly single positive (Shortman *et al.,* 1988).

As a possible criterion for immaturity of the lymphocytes in LFV, their sensitivity to the effects of hydrocortisone acetate was examined. Eight week old Balb/c mice were injected with 2.5 mg of hydrocortisone acetate intra-peritoneally and killed 48 hours latter. The small intestine was fixed as a "Swiss roll" and paraffin sections were examined after staining with haematoxylin and eosin. Lymphocyte counts were performed on random sections through LFV and the results from the mice in each group (control, 1 mouse and cortisone-treated, 2 mice) were pooled. Comparison between the numbers of lymphocytes in longitudinal sections through LFV in the small intestines of the cortisone-treated mice and the untreated control mice (Table 5.1) indicated a

significant reduction in the numbers of cells in LFV from cortisone-treated mice ($P<0.005$).

Table 5.1-The effect of hydrocortisone on lymphocytes in LFV

LFV	Mean	Range
Cortisone treated (n=43)	86±36.6	23-163
Cortisone untreated control (n=28)	148±52.25	89-307

5.4 CELL DIVISION BY LYMPHOCYTES IN LFV

It has been shown that large lymphocytes in the outer thymic cortex are labelled within 3 hours after a single transcapsular administration of tritiated thymidine (Weissman, 1973). Small-and medium-sized lymphocytes that carry the label are found throughout the cortex and medulla 2-4 days later (Weissman, 1973). In order to examine whether LFV contain a dividing population of lymphocytes, 6 week old Balb/c mice were injected intraperitoneally with tritiated thymidine (^{3}HTdr) four times at 3 hourly intervals. Autoradiography on paraffin sections showed that a proportion of lymphocytes in LFV was labelled 3 hours after a single injection of ^{3}HTdr (Fig 5.4a). Most of the cells that were labelled were located in the basal portion of the LFV. Labelling with a single pulse of ^{3}HTdr indicates that approximately 7% of the lymphocytes within an LFV are in cell-cycle at any particular time. LFV from mice that had received four doses of ^{3}HTdr over a period of 12 hours contained larger numbers of labelled lymphocytes (Fig 5.4b). Labelled cells were concentrated in the center and at the base of LFV, although some labelled cells were also found towards the tip of the LFV. At this stage, approximately 25% of the lymphocytes within the LFV were labelled and had, therefore, been in cell cycle during this period.

Figure 5.4

Autoradiographs of paraffin sections of LFV in the small intestine from Balb/c mice. **a**- tissue collected from a mouse three hours after a single injection of ^{3}H TdR, **b**- tissue collected from a mouse 3 hours after the last of 4 doses of ^{3}H TdR administered at 3 hourly intervals. Original magnification x 83.

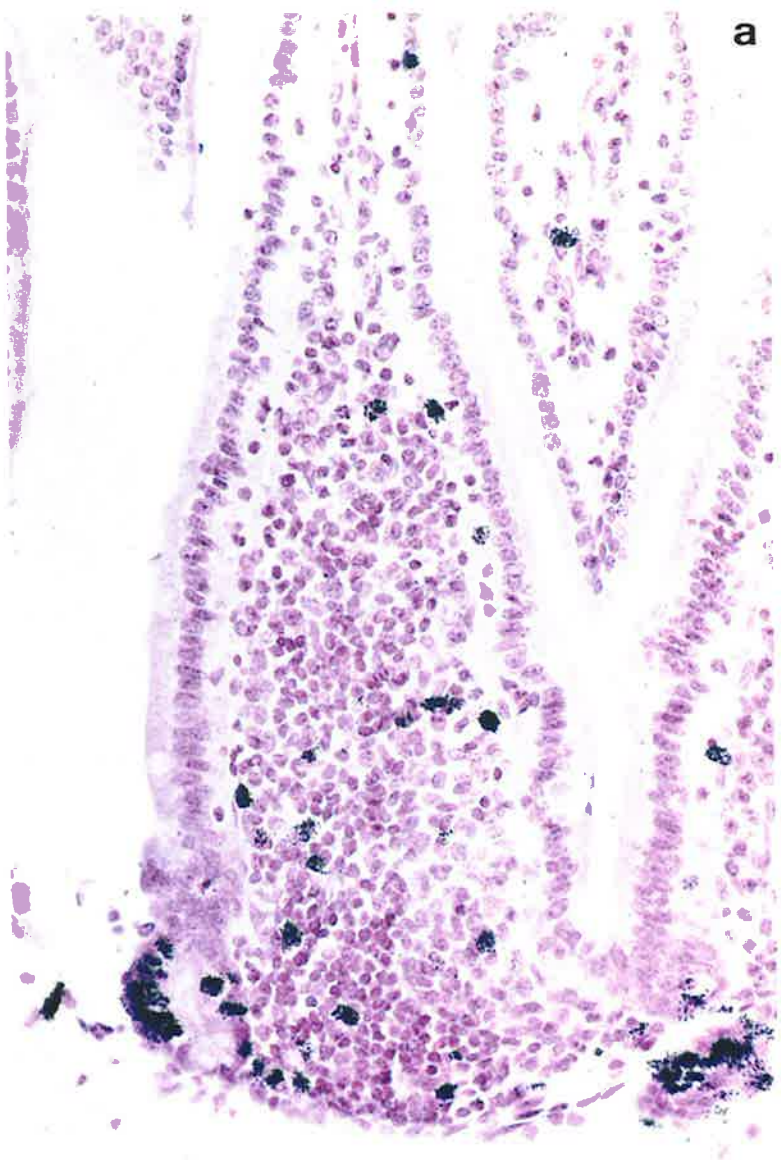
a

b

5.5 ASSESSMENT OF RAG-1 GENE EXPRESSION BY LYMPHOCYTES IN LFV

RAG-1 gene is known to be expressed in immature T-cells and is necessary for rearrangement of the TCR genes (Schatz *et al.,* 1989). There are two periods of high RAG-1 and RAG-2 mRNA expression during intrathymic development of T cells. The first wave peaks early, at the $CD25^+$ $CD4^-$ $CD8^-$ $CD3^-$ stage of development, while the second wave occurs later at the $CD4^+$ $CD8^+$ stage (Wilson *et al.,* 1994b). High expression of the RAG-1 and RAG-2 genes was detectable in the cortex but not in the medulla (Boehm *et al.,* 1991). Expression of both genes is normally terminated during subsequent maturation and neither $CD4^+$ $CD8^-$ or $CD4^-$ $CD8^+$ (single positive) sub-populations express either RAG-1 or RAG-2 genes (Turka *et al.,* 1991).

In the gut, there is a small population (10%) of triple negative ($CD3^-$ $CD4^-$ $CD8^-$) intraepithelial lymphocytes (Camerini *et al.,* 1993). This subset of IEL is more abundant in 3-week-old mice and these cells contain RAG-1 mRNA (Guy-Grand *et al.,* 1992). The expression of the RAG-1 gene in this $CD3^-$ subset of IEL suggests that a proportion of these cells may be T cell precursors.

To examine the possibility that LFV also contain a population of T cell precursors that are engaged in rearrangement of TCR genes, the expression of RAG-1 enzyme protein was examined in Balb/c mice by indirect immunofluorescence staining using polyclonal rabbit anti-mouse RAG-1 antibody. In the thymus, the cortical thymocytes were stained strongly by anti-RAG-1 antibody (Fig 5.5a) while the thymocytes in medulla were unstained. However, when applied to sections of gut, this antibody produced considerable non-specific staining of most elements, including the epithelium. This was reduced by absorbing a 1/50 dilution of the antibody with mouse spleen and mesenteric lymph node cells. Nevertheless, conclusions about the presence or

absence of specific anti-RAG-1 staining require qualification due to the background of non-specific staining. No unequivocal staining of lymphocytes was detected within LFV or in IEL in surrounding villi (Fig 5.5b). A few positive cells present in classical villi appeared to be stained non-specifically.

A more sensitive technique, such as in-*situ* hybridisation or PCR in in-*situ* might clarify this problem. Preliminary studies using an anti-sense RAG-1 riboprobe to detect RAG-1 transcripts by in *situ* hybridisation was unsuccessful. This probe was constructed from a 1 kilo-base sequence cloned from the rat RAG-1 gene by Mr Craig Murphy (Dept Microbiology & Immunology, University of Adelaide). Compared with a sense riboprobe, the anti-sense probe produced specific hybridisation over the cortex in sections of thymus. However, the anti-sense probe also bound strongly over the thymic medulla, despite all attempts to prevent non-specific binding by use of different temperatures for hybridisation (50°C, 55°C, 65°C) and stringent wash (53°C, 60°C, 65°C), different percentage of formamide in stringent wash, using, pre-hybridisation solution and Rnase treatment. Similar problems of non-specific binding by this riboprobe have also been encountered on rat thymus (Murphy, personal communication).

Figure 5.5

Frozen sections from thymus and jejunum from Blab/c mice, stained with polyclonal rabbit anti-mouse RAG-1 antibody by indirect immunofluorescence technique. **a**- thymocytes in the cortex of the thymus (left) are stained, while the thymocytes in the medulla (right) are unstained. **b**- RAG-1 was not detected within LFV or in IEL in adjacent villi. Original magnification x 83.

a

b

5.6 DISCUSSION

The subset of $CD4^+$ cells in LFV from both the normal and mutant (nude, scid and RAG-1 gene knockout) mice are described in detail in Chapter 3 and Chapter 4. The results of double staining suggest that the $CD4^+$ cells in LFV were neither mature T cells, dendritic cells nor double positive ($CD4^+CD8^+$) T cells. Moreover, they did not express TSA-2 and B220 molecules. They appear to be a distinct subset of lymphocytes that expresses the markers Sca-2 (TSA-1) and CD25, which are associated with T cell progenitors. These cells are possibly equivalent to the $CD4^+$ committed lymphoid progenitors (described) in the thymus. One way of determining whether these cells can differentiate further to produce T cells would be to separate $CD4^+Sca\text{-}2^+CD25^+TCR^-$ lymphocytes from preparation of mucosal lymphocytes by cell sorting, and to use these cells to either re-constitute foetal thymic organ cultures or to reconstitute irradiated thymuses in vivo by intra-thymic injection (Petrie *et al.*, 1990).

The TSA-2^+ (MTS 32^+), $CD4^-$ subset of lymphocytes in LFV may be more mature than the TSA-2^- (MTS 32^-), $CD4^+$ subset. This finding was of interest because mAb MTS-32 reacts with 95% of thymocytes, as shown by flow cytometric analysis (Godfrey *et al.,* 1990). It stains all $CD4^+$ $CD8^+$ and $CD4^-$ $CD8^+$ lymphocytes and the majority of the $CD4^-$ $CD8^-$ and $CD4^+$ $CD8^-$ subsets (Tucek *et al.,* 1992; Vicari *et al.,* 1994). However, when used to stain tissue sections, the thymus medulla appeared to be negative (Godfrey *et al.,* 1990). A minor subset of $CD4^+$ 8^- thymocytes are negative for this marker (Tucek *et al.,* 1992). This subset appears to contain mature $CD4^+$ single positive cells because the $CD4^+$ 8^- MTS-32^- thymocytes are phenotypically enriched for cells that are HSA^+, Qa-2^+ and $CD69^+$ when compared with their less mature MTS-32^+ counterparts (Vicari *et al.,* 1994). Moreover, most peripheral $CD4^+8^-$ T cells are recognized by mAb MTS-32 (Tucek *et al.,* 1992).

As mentioned in Chapter 3 and Chapter 4, the lymphocytes that are located mainly at the bases of LFV with the phenotype $CD25^+$ $MTS37^-$ are more immature than the lymphocytes with the phenotype $CD25^-$ $MTS37^+$ that are located particularly in the sub-epithelial region of the tip and lateral margins of the LFV. The labelled cells with thymidine that located mainly in the center of LFV support this view. Moreover, in rat, after infusion of ^{3}HTdr for 6 days, the majority of newly labelled lymphocytes were TCR^- and located at the base of the LFV (Mayrhofer & Brooks, 1995).

In addition to investigating the surface antigen phenotypes of the lymphocytes in LFV, some other phenotypic characteristics were examined. Injection of 2.5 mg of hydrocortisone acetate intra-peritoneally led to an approximately 42% reduction in the cellularity of LFV. This indicates that at least some of the lymphocytes in LFV share with immature thymocytes sensitivity to glucocorticoid steroid hormones. Further work is needed to explore whether a specific subset of lymphocytes in LFV is depleted by steroid treatment. In particular, it would be of interest to examine the surface antigen phenotype of the residual cortico-steroid resistant lymphocytes in euthymic mice and also to observe the sensitivity of the lymphocytes in the LFV of scid mice and RAG-1 gene knockout mice. Cell surface markers of particular interest would be CD4, CD25, Sca-2, B220 and TSA-2. A significant proportion of the lymphocyte in LFV were found to be in cell cycle. Three hours after injection of ^{3}HTdr, approximately 7% were labelled and these were located mainly at the base of the LFV. After twelve hours of repeated injection, 25% of the lymphocytes were labelled. The latter time approximates to the cell cycle time for mammalian cells. It follows, therefore, that at least a quarter of the cells in LFV are (or have been) in cell cycle during that period. Furthermore, early incorporation of label occurred in cells near the base of the LFV, with labelled cells occurring move distally at the larger period of incorporation. It is unlikely that the labelled cells entered the LFV during the period of a three hours pulse, suggesting that the base of the villus is a site of rapid cell division, with recently divided cells moving distally towards the sub-epithelial

areas. These findings can be correlated with the disposition of lymphocytes in the LFV. As described in Chapters 3 and 4 the $CD4^+$, $CD25^+$, $B220^+$, $TSA\text{-}1^+/Sca\text{-}2^+$ and $TSA\text{-}2^+$ lymphocytes tended to be located at the base of LFV. These cells are possibly related to the labelled cells.

In rats, LFV are also significant sites of cell division but they are excluded from the recirculating pool of lymphocytes (Mayrhofer & Brooks, 1995). A similar gradient of ^{3}HTdr incorporation has been observed into basal lymphocytes early after infusion and later into distal lymphocytes. This gradient of ^{3}HTdr is accompanied by expression of TCR/CD3 by cells labelled at later times after commencement of infusion of the isotope. These observations, together with the findings in mouse LFV described above, support the hypothesis that LFV are populated largely by immature lymphocytes of the T cell lineage and that they are primary lymphoid tissues. However, the product of the RAG-1 gene was not detected in murine LFV. Neither Kanamori et al., (1996) nor the study described herein has detected either the transcriptional or the translational activities of recombinase activating genes in crypto-patches or LFV. However, it is important to note that although the anti-RAG-1 antibody used in the present study detected RAG-1 protein in sections of thymus, it was not detected in IEL in sections of gut. IEL have been shown to contain mRNA encoding RAG-1 by RT-PCR using RNA extracted from isolated cells and by in *situ* hybridisation using tissue sections. It is possible, therefore, that the levels of RAG-1 protein expressed by IEL and perhaps by lymphocytes in LFV are less than those expressed by thymocytes and below the detection threshold of the indirect immunofluorescence technique. Unfortunately, the results of preliminary in *situ* hybridisation experiments using a rat-specific 1 kB anti-sence riboprobe did bot yield interpretable results. Further studies using alternative smaller probes are required to avoid the problem of non-specific binding encountered with the 1 kB probe.

Evidence to support the potential of the small intestine to initiate and regulate T-cell development from bone marrow precursors comes from the work of Mosley and Klein (1992). They engrafted fetal intestine beneath the kidney capsule of adult thymectomized, irradiated, bone marrow reconstituted mice. Beginning at week 2 post-engraftment, clusters of lymphocytes appeared in the grafts within the lamina propria. Moreover, Saito and his colleagues (1998) have shown that engraftment of small intestine containing crypto-patches from nude mice beneath the kidney capsule of scid mice resulted in the development of T cells in the intestine and MLNs of the recipients. In the intestine, $CD3^+$ T cells are detected in the intestinal epithelium (IELs) and to a lesser extent in the LP five weeks after engraftment.

Although thymus derived IEL may be the progeny of blasts resulting from antigenic stimulation in the Peyer's patches (Guy-Grand *et al.,* 1978), the origin of thymus-independent IEL is unclear. Whether these cells accomplish their maturation from bone marrow-derived progenitors completely within the small intestinal epithelium or whether part of that maturation occurs elsewhere is unknown. A possible site external to the epithelial compartment of the intestine is the LFV. While electron microscopy studies have shown that the lymphocytes in crypto-patches may migrate into the overlying villus epithelium (Saito *et al.,* 1998), it is difficult to envisage how local tissue migration could distribute cells to the entire epithelial layer of the small intestine. However, it has been shown that c-kit^+ Lin^- CP cells in scid mice are able to generate TCR $\alpha\beta$ and $\gamma\delta$ IEL (Saito *et al.,* 1998). It is possible that in mice, the triple negative $CD3^-CD4^-CD8^-$ lymphocytes in LFV could be the progenitors of thymus-independent IEL and that they could acquire the TCR(α/β or γ/δ) and the CD8$\alpha\alpha$ homodimer only after they have migrated and localized to the epithelium. If this is true, the question arises as to how these cells migrate out of the lamina propria of LFV and into the epithelial layer and how they disseminate along the gut wall. A likely route is via the blood circulation and the presence

of progenitors in thoracic duct lymph should be investigated. In rats, it would appear that commitment to expression of the α/β TCR and the CD4 and CD8 co-receptors occurs within LFV. However, it remains possible that more primitive cells exit LFV in rats and give rise to IEL that express the γ/δ TCR.

There are considerable difficulties associated with the isolation of lymphocytes from LFV, primarily due to the small size of these structures, their diffuse distribution and the lack of appropriate markers which clearly distinguish between the $CD3^-CD4^-CD8^-$ triple negative cells in LFV and the subpopulation of triple negative IEL. Until this problem is solved, studies on LFV will continue to rely on in *situ* detection of tissue antigens, gene transcripts and cell division. The important questions of cell lineage and the differentiation potential of the lymphocytes in LFV awaits studies utilising adoptive transfer and in vitro culture of defined cell populations.

CHAPTER 6

CHARACTERIZATION OF ISOLATED LYMPHOID AGGREGATIONS IN THE MUCOSA OF THE HUMAN SMALL INTESTINE

6.1 INTRODUCTION

The gut-associated lymphoid tissues are thought to function as secondary lymphoid organs (Keren, 1992), although recent evidence suggests that the epithelium of the human small intestine may be a site of primary extrathymic T cell differentiation (Latthe *et al.,* 1994; Lynch *et al.,* 1995; Lundqvist *et al.,* 1995). The organized gut-associated lymphoid tissues in the small intestine consist principally of Peyer's patches (PP) and the mesenteric lymph nodes (Keren, 1992).

Peyer's patches are aggregations of lymphoid follicles which generally have an anti-mesenteric distribution, although in humans they are situated occasionally at random around the circumference of the gut wall (Cornes, 1965a). The number and size of PP increases for at least the first 10 years of life and reaches a maximum at puberty (Cornes, 1965a). The number of follicles in each patch varies from as few as five to several hundreds but decreases with age beyond puberty (Cornes, 1965b). The most obvious component of the PP (Spencer et al., 1986a; Spencer et al., 1986c; Brandtzaeg & Bjerke, 1990) is the follicle, consisting of a germinal center (GC) and the surrounding corona of B cells. Overlying the follicle is the dome region, consisting mainly of T cells and the specialized follicle-associated epithelium (FAE). The FAE contains specialized microfold (M) cells (Brandtzaeg & Bjerke, 1990; Owen *et al.,* 1986; Fujimura *et al.,* 1990) that have been shown in mice to transport macromolecules and infectious agents from the gut lumen into the PP (Owen, 1977; Wolf *et al.,* 1981). The interfollicular regions contain T cells, interdigitating cells and high endothelial venules (HEVs). PP are important sites of lymphocyte recirculation (Keren, 1992).

Other forms of lymphoid aggregations that have been described in the wall of the human small intestine are isolated lymphoid follicles (ILF), which lie within the mucosa and submucosal lymphocyte aggregations (SLA), which lie within the muscularis mucosa

(Morson & Dawson, 1979). These are observed commonly on histologic examination, but they are not visible macroscopically (Shorter & Tomasi 1982; Price, 1985; Whitehead, 1990). The number of these lymphoid aggregations increases in the more distal parts of the small intestine (Whitehead, 1990). Both ILF and SLA are accepted as normal components of the small intestine (Price, 1985) and they are assumed to represent solitary PP follicles (Mayrhofer, 1984). The presence of M cells in the FAE overlying similar structures in guinea pigs (Rosner & Keren, 1984) supports this view.

Solitary lymphoid structures that may be sites of primary extrathymic T cell differentiation have been described recently in rat (lymphocyte-filled villi) (Mayrhofer &Brooks, 1995) and murine (crypto-patches) (Kanamori *et al.,* 1996) small intestine. This study seeks to test the hypothesis that similar structures occur in human small intestine. The distribution and structures of the various forms of solitary lymphoid tissue that are found in the mucosa of the normal human small intestine have been compared with the Peyer's patches. Furthermore, comparisons have been made between the surface antigen phenotypes of the lymphocytes within these structures.

6.2 RESULTS

6.2.1 Histological Observations

6.2.1.1 Peyer's patches (PP)

Peyer's patches were identified in tissue samples from ileum (Case 1) and jejunum (Case 2). The follicles in the jejunal PP were smaller than those in the ileal sample but otherwise, the histological appearance conformed with published descriptions (Keren, 1992). These specimens provided recognized mucosal secondary lymphoid tissues for histological and immunohistological comparisons with the other lymphoid aggregations described herein. Typical follicles in an-ileal PP are illustrated in Fig 6.1.

Figure 6.1

Haematoxylin and eosin stained section of human small intestine, showing an ileal Peyer's patch with distinct follicles, containing germinal centers. Interfollicular regions are situated between the follicles. Original magnification x 17.

6.2.1.2 Structure of isolated lymphoid follicles (ILF) and submucosal lymphoid aggregates (SLA)

ILF (Fig 6.2) and SLA (Fig 6.3a) were encountered frequently in sections prepared from the 4 specimens of jejunal mucosa and the 2 specimens of ileal mucosa. Counts on sectioned "Swiss-rolls" of mucosa indicated a frequency of ILF of approximately 1 per 269 villi in the jejunum and 1 per 28 villi in the ileum. ILF were present in sections of both the mesenteric and anti-mesenteric portions of the gut circumference. The mean diameter of a typical ILF was considerably larger (250 μm, equivalent to 50 sections of 5 μm thickness) than that of a typical villus (110 μm, equivalent to 22 sections) and they were covered with epithelium that contained frequent IEL and some goblet cells. The lymphoid tissue occupied most of the lamina propria and extended to the muscularis mucosa. In some ILF, particularly those in the specimen from a blind loop (Case 2), the central follicle of small lymphocytes contained a GC (Fig 6.2). In only occasional random profiles of ILF did the lymphoid tissue penetrate the superficial layers of the muscularis mucosa.

Serial sections of ILF showed that there was variability in the degree to which these structures extended into the muscularis mucosa. Some were entirely mucosal (Fig.6.2), in others a few superficial fibres of the muscularis were reflected around the base of the ILF, while in typical ILF the submucosal portion extended deep into the muscularis (Fig 6.3c). Nevertheless, in all cases the basic structure was as described above.

In most cases, SLA were located entirely within the muscularis mucosa and they consisted of loose aggregations of small lymphocytes, with no evidence of follicular organization (Fig 6.3a). However, in some instances, SLA were observed to breach the superficial layers of the muscularis mucosa (Fig 6.3b). When SLA were sectioned from edge to edge, it was revealed in all cases that they were connected to a mucosal lymphoid

Figure 6.2

Haematoxylin and eosin stained section of human small intestine, showing an isolated lymphoid follicle (ILF). Typical ILF were considerably broader than typical villi. Those in case 2 contained a distinct germinal center, GC in this photomicrograph. They were covered with epithelium that contained frequent intraepithelial lymphocytes (IEL) and some goblet cells. Original magnification x 41.

Figure 6.3

Submucosal lymphoid aggregates in jejunal mucosa. **a**- typical submucosal lymphoid aggregate, lying within the muscularis mucosa. **b**- in deeper sections through the structure illustrated in b, the muscularis mucosa is reflected and the lymphoid aggregation extends into the mucosa. **c** - serial sections reveal that the submucosal lymphoid aggregate (b) is part of the submucosal extension of an isolated lymphoid follicle containing a germinal center. The submucosal part lies within reflections of the muscularis mucosa. **d**- higher power view of the submucosal part of the isolated lymphoid follicle illustrated in a-c. A high endothelial venule (large arrow) is sectioned longitudinally and contains lymphocyte nuclei (small arrow) within the endothelium. H&E. Original magnification, a-c x 17, d x 83.

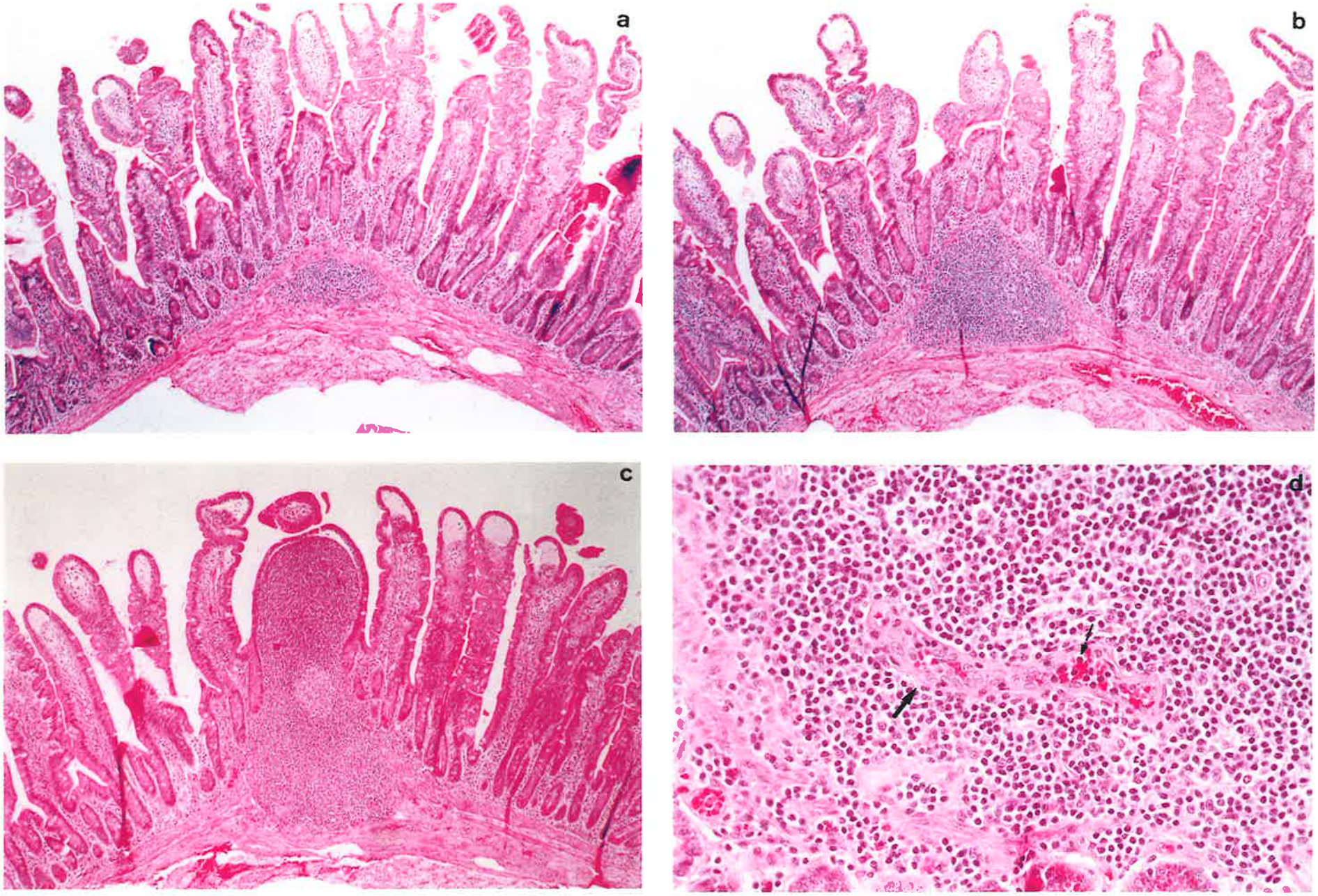
a
b
c
d

follicle via a collar-stud-like constriction (Fig 6.3c). SLA and ILF are, therefore, parts of a single structure which has both submucosal and mucosal extensions. The mucosal portion has morphological similarities to the follicle of a Peyer's patch, while the submucosal part (Fig 6.3d) has vessels resembling HEV. The submucosal portion may be analogous to the interfollicular areas in PP, which at the perimeter, extend beneath the muscularis mucosa.

6.2.1.3 Lymphocyte-filled villi (LFV)

Approximately 1 per 230 villi in jejunum had a modified structure, with large numbers of lymphocytes packed in the lamina propria (Fig 6.4). These "lymphocyte-filled villi" had a mean diameter (105μm, equivalent to 21 sections of 5 μm thickness) which was similar to that of classical villi (110 μm, equivalent to 22 sections). LFV did not contain organized follicles and serial sections showed that they did not extend through the muscularis mucosa at any point. Lymphocytes were most densely packed at the base of LFV and were least dense towards the villus tip and immediately subjacent to the overlying epithelium. HEV were never observed in these structures. IEL were numerous in LFV and often formed clusters within the epithelium, which also contained fewer goblet cells than epithelium covering adjacent villi. LFV were not detected in the specimens of ileum.

6.2.1.4 Intraepithelial lymphocytes (IEL) in the epithelium covering ILF and LFV.

There appeared to be larger numbers of IEL in the epithelium covering ILF and LFV than in the epithelium of adjacent villi. In contrast to the adjacent villi, where the IEL were distributed mainly along the basement membrane, IEL in the epithelium of ILF and LFV were distributed at all levels, similar to the distribution of IEL in the FAE overlying PP. In LFV in particular, IEL tended to be clustered within the epithelium. The

Figure 6.4

A lymphocyte-filled villus in the jejunal mucosa. The villus is broader than surrounding classical villi, the lamina propria is packed with lymphocytes and the epithelium contains a greater density of intraepithelial lymphocytes. H&E. Original magnification x 41.

results of counts (Table 6.1) showed that IEL were more frequent in the epithelium of classical villi in the jejunum than in the ileum and that their numbers are significantly higher ($P<0.005$) in the epithelium overlying ILF, LFV and PP than in the epithelium covering surrounding classical villi.

6.2.2 Identification of Cell Surface Markers by Immunohistochemistry

6.2.2.1 Peyer's patches (PP) and classical villi

Immunohistochemical staining of PP showed the presence of B cells in the follicle and the T cells in the interfollicular region. The dome area contained B cells, T cells and MHC class II-positive accessory cells as described by others (Spencer *et al.*, 1986a; Brandtzaeg & Bjerke, 1990). The MHC class II positive cells were also present in the interfollicular areas.

Of particular interest for comparison with the other mucosal lymphoid structures, sections of ileal and jejunal PP were stained with mAbs UCHL-1 and FMC7, to determine T cells with the CD45RO and CD45RA phenotypes respectively (Fig 6.5). The majority of T cells in PP expressed the CD45RO splice variant (Fig 6.5b and d). It is noteworthy that most of the cells in the GC of the ileal PP expressed both the CD45RA (Fig 6.5a) and the CD45RO (Fig 6.5b) splice variants, whereas GC in the jejunal PP expressed the CD45RA splice variant strongly (Fig 6.5c) and were stained only weakly with the antibody against the CD45RO splice variant (Fig 6.5d). In contrast B cells in the follicle mantle zones of PP from both regions expressed only the CD45RA splice variant (Fig 6.5a,c). The epithelium of classical villi and the FAE of the PP from both jejunum and ileum were both stained by mAb FMC 52 (anti-MHC class II) (not shown).

Table 6.1: Numbers and surface antigen markers of intraepithelial lymphocytes (IEL) in classical villi and the lympho-epithelium overlying various mucosal lymphoid structures in the small intestine.

Tissue	Total IEL[a]	Percentage of labelled IEL[b]						
		CD3+	CD7+	CD4+	CD8+	CD45RO+	CD45RA+	CD19+
JEJUNUM								
Isolated lymphoid follicles (ILF)	42.3 ±4.7	97.0 ±2.5	95.9 ±2.8	37.1 ±5.4	79.5 ±10.5	98.3 ±1.8	4.6 ±5.6	1.2 ±1.2
Lymphocyte-filled villi (LFV)	46.0 ±4.7	91.7 ±6.6	94.8 ±7.9	30.2 ±10.2	72.8 ±15.7	95.7 ±5.3	0	0
Peyer's patches (PP)	44.9 ±4.2	92.0 ±3.3	90.6 ±1.2	38.6 ±8.9	66.2 ±5.9	93.7 ±0.2	29.4 ±13.3	12.3 ±0.3
Classical villi	25.9 ±4.5	98.6 ±0.8	93.3 ±1.5	11.1 ±4.4	95.4 ±3.7	98.9 ±1.3	0.2 ±0.4	0.6 ±1.3
ILEUM[c]								
Isolated lymphoid follicles (ILF)	29.5 ±4.8	86.5 ±6.0	89.4 ±3.2	11.0 ±11.5	78.4 ±6.9	83.4 ±8.3	8.4 ±4.9	1.1 ±2.3
Peyer's patches (PP)	33.6 ±8.1	68.2 ±4.8	70.3 ±5.2	17.8 ±6.2	62.5 ±7.9	89.8 ±4.3	29.5 ±7.8	11.0 ±8.1
Classical villi	11.4 ±2.4	84.0 ±3.8	88.7 ±4.1	1.7 ±2.3	86.9 ±5.2	87.1 ±7.1	4.1 ±2.8	0.7 ±2.1

[a]Means of total IEL per 100 epithelial cells, calculated from 5 ILF, 5 LFV, 5 PP follicles or 10 classical villi in H&E stained sections.
[b]Means of differential counts for each marker, calculated from 5 ILF, 5 LFV, 5 PP follicles or 10 classical villi in frozen sections.
[c]Lymphocyte-filled villi were not observed in specimens of ileum.

Figure 6.5

Expression of CD45 splice variants by T cells and B cells in Peyer's patches, detected by an indirect immunoperoxidase technique on frozen sections. **a**- ileal Peyer's patch follicles stained with monoclonal antibody FMC7. B cells in the mantle zone and germinal center express the CD45RA. Most T cells in the interfollicular areas are not stained. **b**- ileal Peyer's patch follicles stained with monoclonal antibody UCHL-1. In addition to T cells in the interfollicular area and dome and scattered T cells in the follicle (stained darkly), B cells in the germinal center are stained with intermediate intensity. Small B cells in the mantle zone are unstained. **c**- jejunal Peyer's patch follicles stained with monoclonal antibody FMC7. B cells in the mantle zone and the germinal center express the CD45RA splice variant. **d**- jejunal Peyer's patch follicles stained with monoclonal antibody UCHL-1. B cells in the mantle zone do not express the CD45RO splice variant and cells in the germinal center express this isoform only weakly. T cells in the interfollicular area, in the dome and scattered in the germinal center are stained. Original magnification x 17.

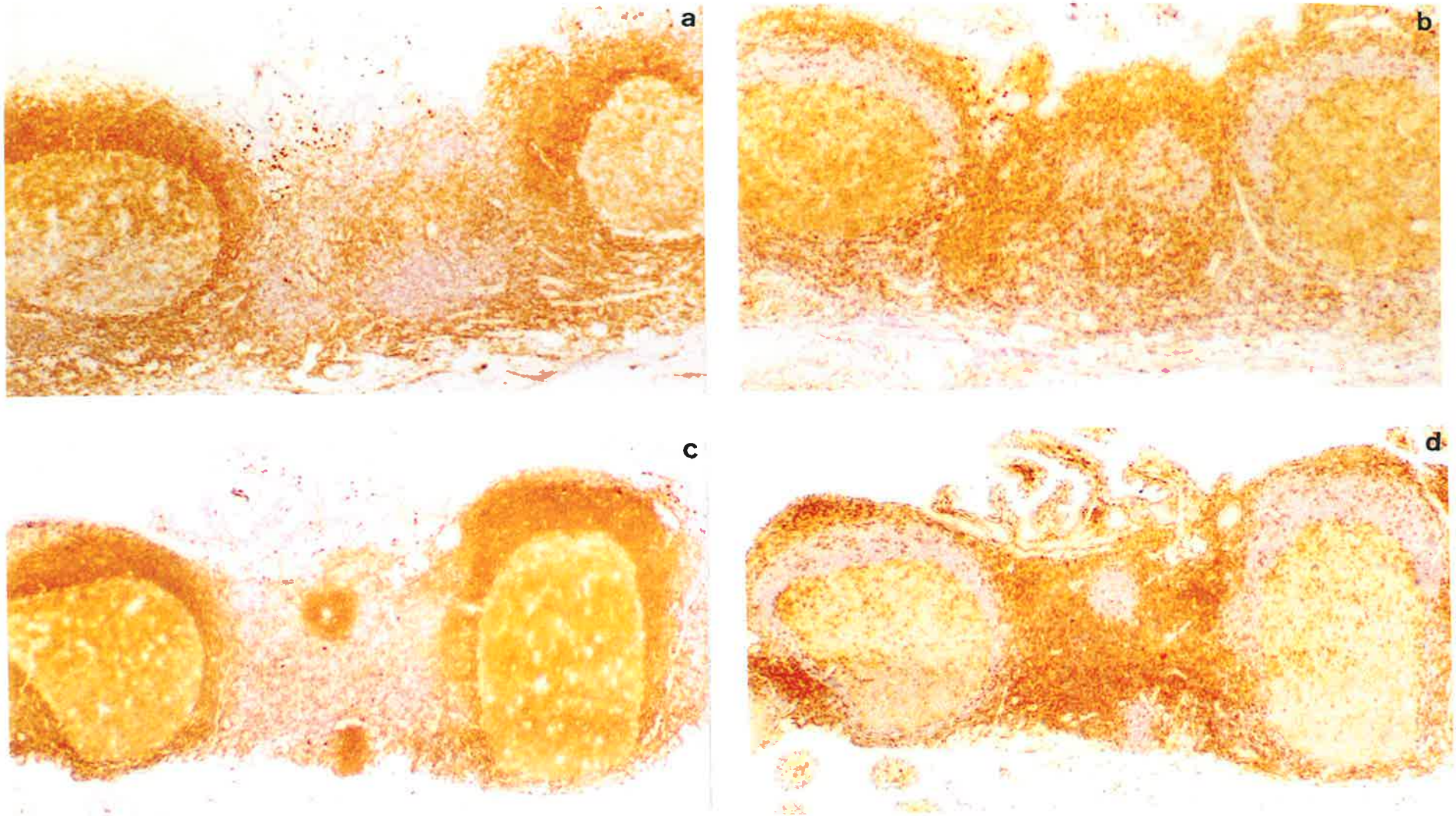
a
b
c
d

6.2.2.2 Isolated lymphoid follicles (ILF)

Sections of ILF, including the submucosal portions (i.e., the so-called SLA), were examined immunohistochemically with the panel of mAb. Approximately serial sections are shown in Fig 6.6, 6.7 and 6.8. Staining with mAbs FMC63 (anti-CD19, Fig 6.6a), L26 (anti-CD20, not shown) and with mAb FMC-52 (anti-MHC class II, Fig 6.6b), confirmed that the follicles contained mainly B cells. Some B cells were scattered also in the overlying dome region. In sections of ILF containing GC, such as the one illustrated from a specimen of blind loop of jejunum (Case 2), cells in the GC expressed lower levels of CD19 and CD20 than the small B cells in the mantle zone. Both germinal center and mantle zone B-cells expressed the CD45RA splice variant (mAb FMC7, Fig 6.6c). Many cells in the GC expressed the transferrin receptor (CD71, mAb OKT9, Fig 6.7). Scattered cells in the GC expressed CD4 (Fig 6.8d), CD25 (not shown) and CD3 (Fig 6.8c). Strongly CD45RO-positive cells in the GC are believed to be T cells and the remaining cells were either negative or stained weakly (mAb UCHL-1, Fig 6.8a).

Most lymphocytes in the submucosal portions of ILF illustrated in Fig 6.6 were not stained by mAbs that detected B cell markers (CD19, CD20, MHC-class II) but they were stained by mAb directed against the T cell markers. A serial section stained with mAb OKT11 (anti-CD2) is shown in Fig 6.8b and staining with antibodies against CD3 (Fig 6.8c), CD4 (Fig 6.8d), CD5 (Fig 6.8e) and CD7 (Fig 6.8f) was similar. However, in some ILF, the B cell follicle extended further towards the base of the ILF. T cells predominated in the dome beneath the epithelium of the ILF. The majority of T lymphocytes in both areas expressed the CD45RO splice variant (Fig 6.8a) and scattered cells expressed the activation markers CD25 (not shown) and CD71 (Fig 6.7). Large, irregular cells in both of these T cell areas stained with mAb FMC52 and they are believed to be interdigitating dendritic cells (Fig 6.6b).

Figure 6.6

Expression of surface markers by lymphocytes in approximately serial frozen sections from an isolated lymphoid follicle in the jejunum, detected by the indirect immunoperoxidase technique. Scattered large, densely stained cells are eosinophils containing endogenous peroxidase. **a**- monoclonal antibody FMC63 (CD19). B cells in the mantle zone and germinal center of the follicle are stained. Cells in the submucosal extension are mainly unstained. **b**- monoclonal antibody FMC52 (MHC class II). B cells in the follicle are stained. Also stained are large dendritic cells in the dome and the submucosal extension at the base. **c**- monoclonal antibody FMC7 (CD45RA). B cells in the mantle zone and germinal centre are stained, as are scattered cells in the submucosal extention. Original magnification x 41.

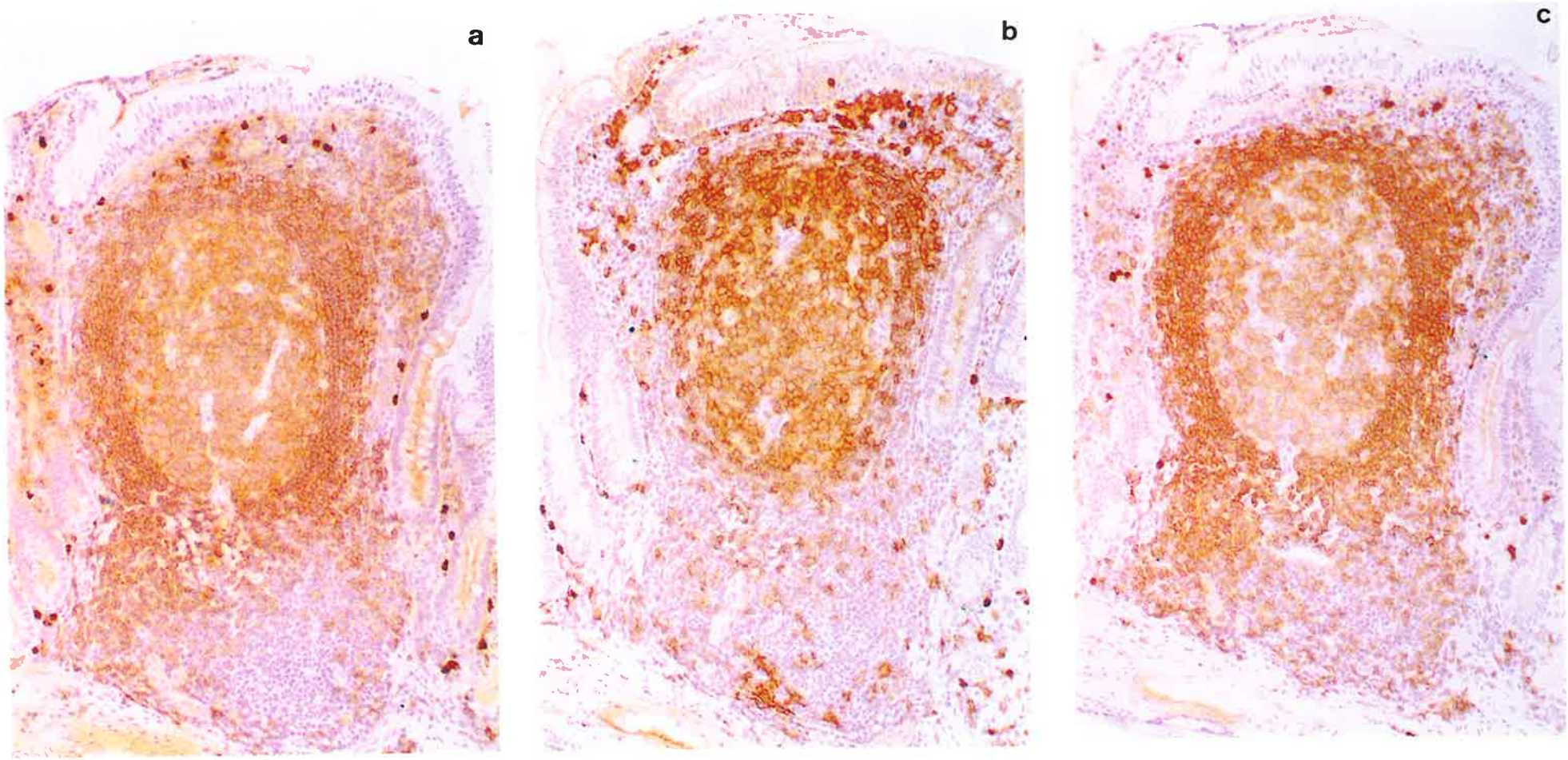
a
b
c

Figure 6.7

Isolated lymphoid follicle in normal jejunal mucosa. Serial frozen section (continued from Fig 6.6) was stained with monoclonal antibody OKT9 by the indirect immunoperoxidase technique. B cells in the germinal center, many in the mantle zone and some scattered cells in the dome and at the base of the ILF are stained. Original magnification x 41.

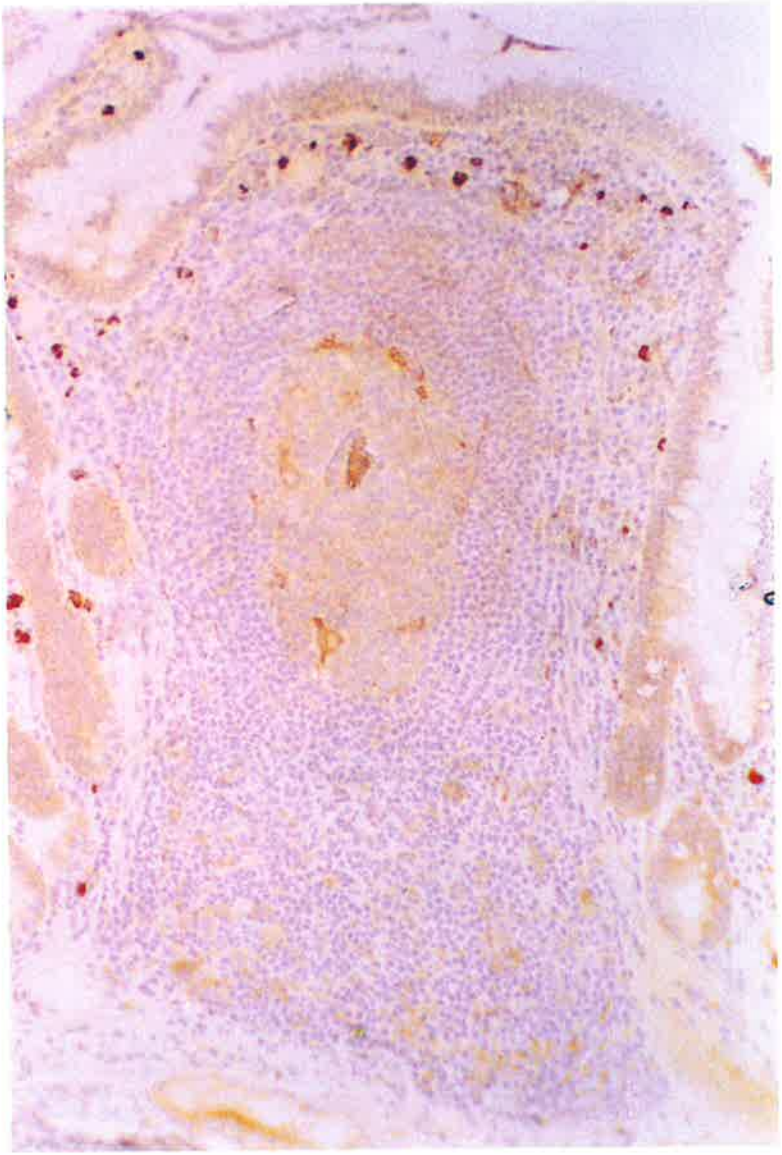

Figure 6.8

Isolated lymphoid follicle in normal jejunal mucosa. Serial frozen sections (continued from Figs 6.6 and 6.7) were stained with UCHL-1 monoclonal antibody and antibodies against T-cell markers by the indirect immunoperoxidase technique. **a**- monoclonal antibody UCHL-1 (CD45RO). The majority of T cells in the submucosal region are stained, as are scattered T cells in the dome region and in the germinal center. Germinal center B cells are unstained. **b**- monoclonal antibody OKT11 (CD2). T cells are stained in the submucosal region, as are scattered cells in the dome and germinal center. **c**- monoclonal antibody OKT3 (CD3). **d**- monoclonal antibody OKT4 (CD4). **e**- monoclonal antibody WM13 (CD5). **f**- monoclonal antibody HB2 (CD7). The distribution of cells stained with monoclonal antibodies against CD3, CD4, CD5 and CD7 is similar to the distribution cells expressing CD2. Original magnification x 41.

a

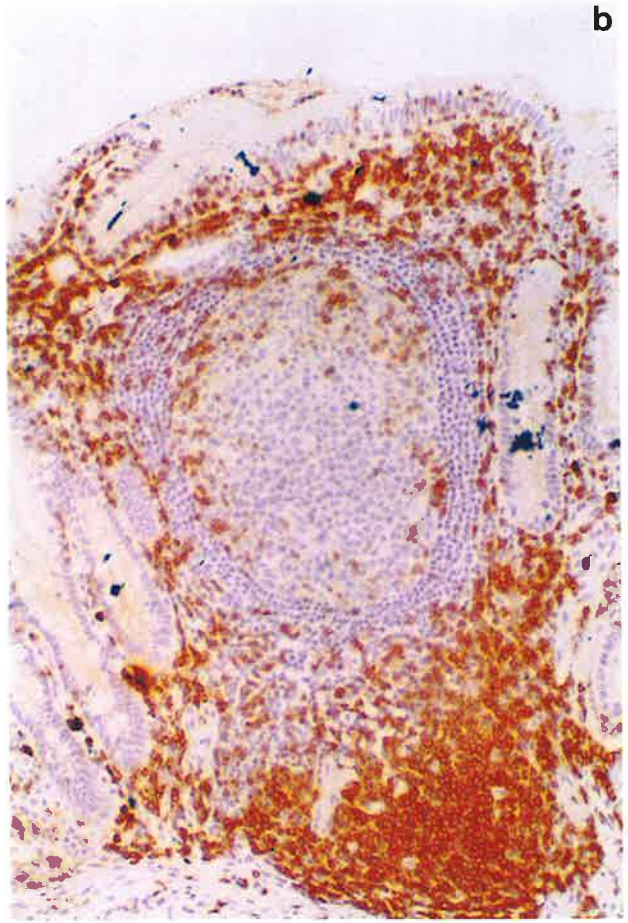
b

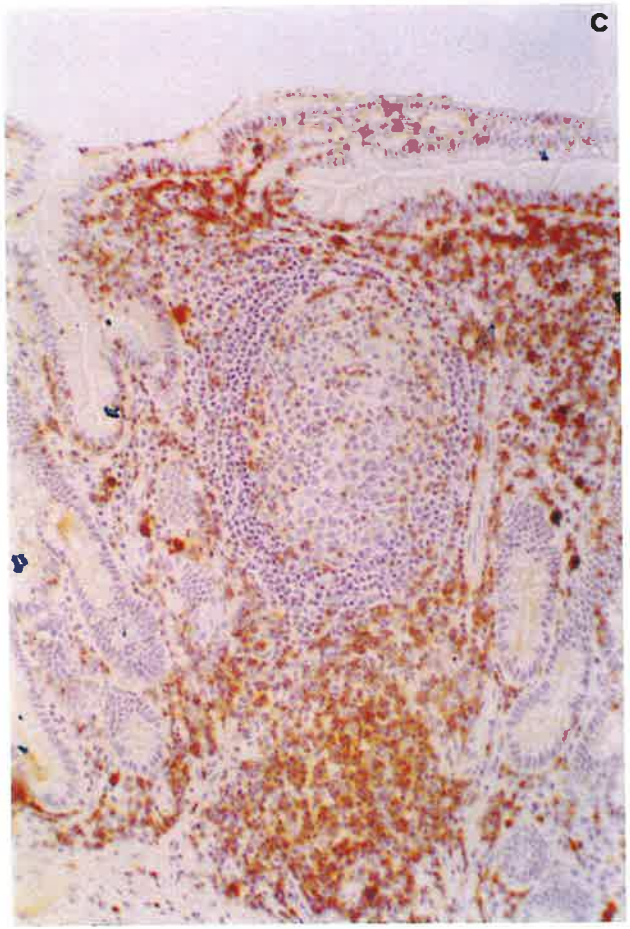
c

No lymphocytes in ILF expressed CD1a (mAb OKT6) (Fig 6.9a). A small number of YB5.B8-positive cells (c-kit) in the T cell areas of ILF (Fig 6.9b) were shown to be mast cells by staining of Carnoy-fixed sections in combination with Alcian blue (Fig 6.9c).

In preparing serial frozen sections of ILF for immunohistochemical staining, it was observed that there was variability in the degree to which these structures extended into the muscularis mucosa. Some were entirely mucosal (Fig 6.10a), in others a few superficial fibres of the muscularis were reflected around the base of the ILF, while in typical ILF the submucosal portion extended deep into the muscularis. Nevertheless, in all cases the basic structure and distribution of lymphocyte subsets were as described above although the basal T cell areas were smaller in the mucosal variants of ILF and the HEVs were placed laterally, adjacent to the surrounding crypts (Fig 6.10b).

6.2.2.3 Lymphocyte-filled villi (LFV)

As described above, LFV were observed only in jejunal specimens and they were distinguished from ILF by their size, by the fact that they were always confined to the mucosa and because they did not contain obvious follicles. An important feature of crypto-patches (Kanamori *et al.,* 1996) and LFV in rodents is that they contain very few B cells. Therefore, LFV were sectioned serially and alternate sections were stained with mAb directed against either CD19 or CD20.

Due to the time-consuming process of identifying the structures in unstained frozen sections, this immunohistochemical study was limited to tissue from a specimen of normal jejunum (Case 5) and a specimen from a blind loop of jejunum (Case 2). The observations on B lymphocytes in 15 LFV examined in this way are presented in Figures 6.11 and 6.12 and summarized in Table 6.2. Among the 5 LFV were examined in the specimen of normal jejunum (Case 5), no cells were detected that expressed CD19 or

Figure 6.9

Isolated lymphoid follicle in normal jejunal mucosa. Frozen sections were stained with monoclonal antibodies against markers of immature T cells by the indirect immunoperoxidase technique. **a**- monoclonal antibody OKT6 (CD1a). No lymphocytes are stained. **b**- monoclonal antibody YB5.B8 (ckit) . Scattered cells in the dome are stained. **c**- staining by both YB5.B8 monoclonal antibody and Alcian blue shows that the cells expressing ckit in the dome region are mast cells. Original magnification x 41.

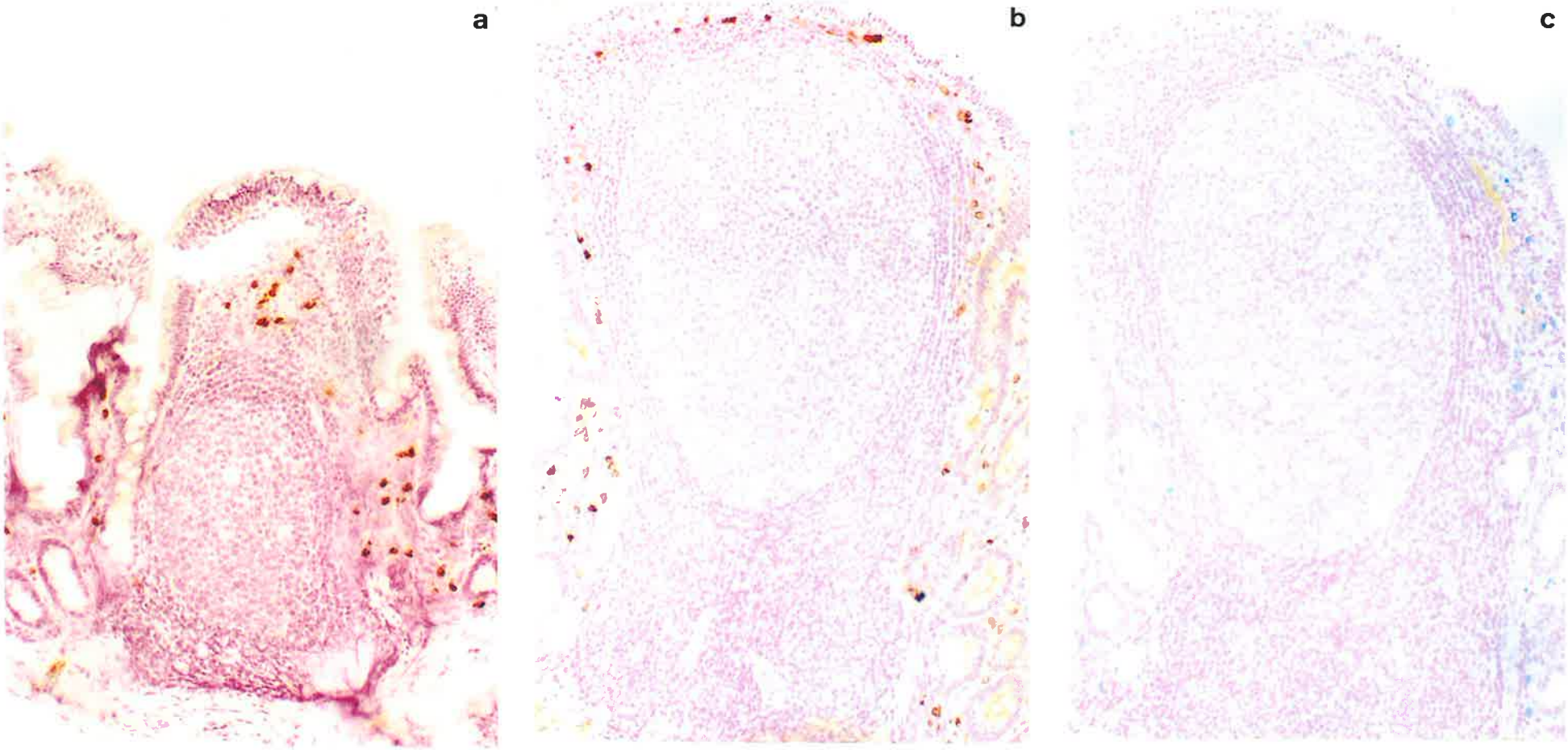
a
b
c

Figure 6.10

Frozen sections from a mucosal variant isolated lymphoid follicle in the jejunal mucosa. **a**- staining with monoclonal antibody FMC7 (CD45RA) shows a small follicle of B cells containing a germinal centre near the base (confirmed in a serial section stained to demonstrate CD19). This section passes through two high endothelial venules (arrows). **b**- higher power view of the base of the follicle, showing one of the high endothelial venules (arrow heads). Original magnification a x 41, b x 83.

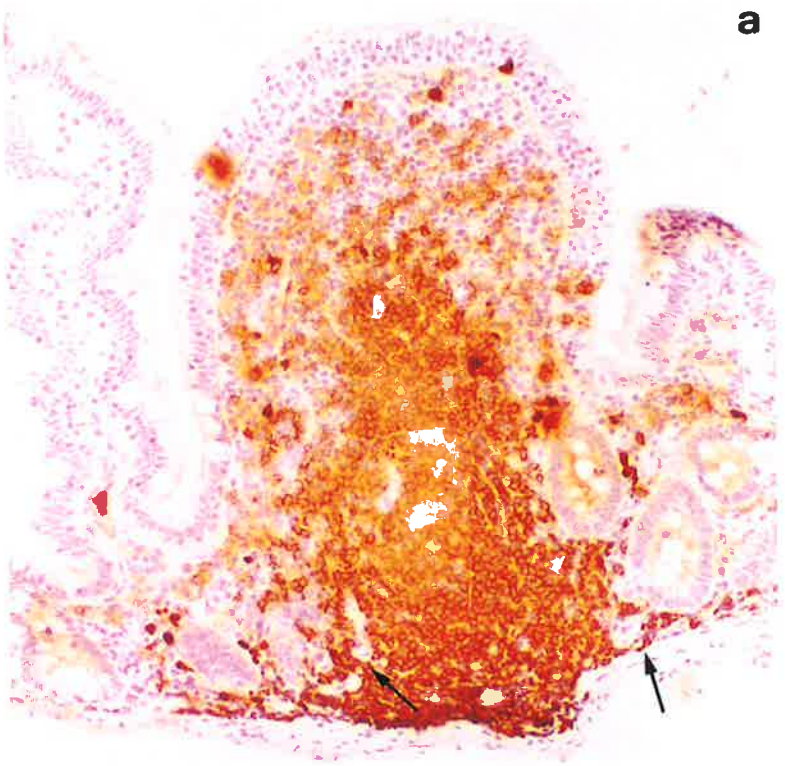
a

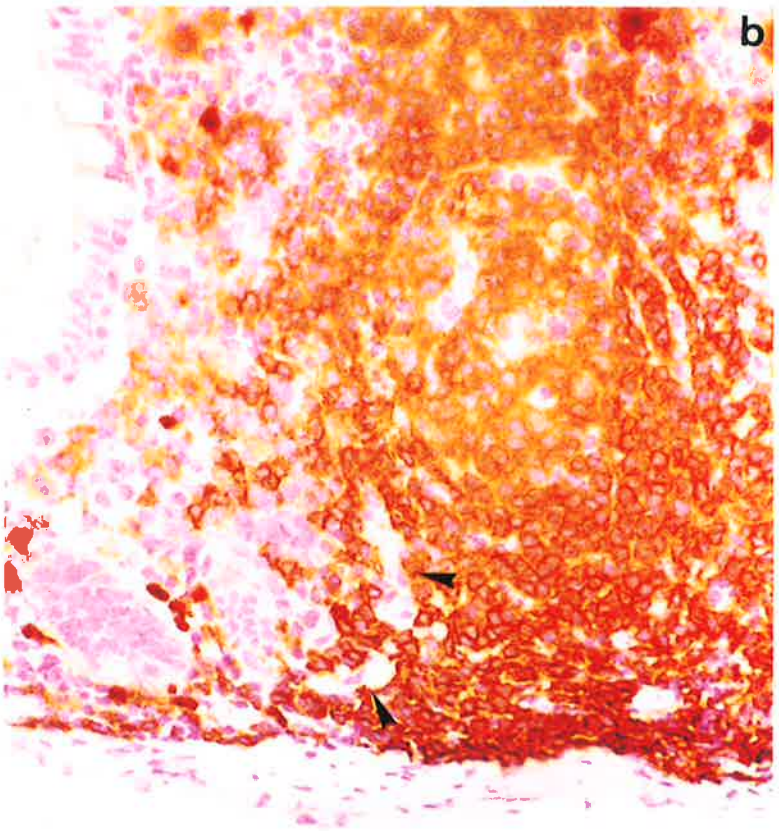
b

CD20 (Fig 6.11a) in four and in the fifth, occasional CD19-positive lymphocytes were seen in a scattered distribution. It appears that B lymphocytes are not, therefore, a prominent component of LFV in normal jejunum and most LFV do not contain either a cluster of B cells or an organized follicle of B lymphocytes. In contrast, all LFV examined in sections of mucosa from a blind loop of jejunum contained B cells. The numbers varied from occasional CD19-positive cells in a scattered distribution (5LFV) (Fig 6.12a) to a small cluster (Fig 6.12b) of CD19 or CD20-positive cells at the base (4 LFV) or a small follicle of stained cells (Fig 6.12c) without a GC (1 LFV). Although these structures all conformed broadly to the morphological criteria that we have used to define LFV, they appear to be heterogenous with respect to content of B lymphocytes. This may reflect the greater antigenic load expected from an intestinal blind loop. Some of these LFV have similarities to the mucosal variants of ILF (see below). It is interesting that the presence of follicles was seen only in tissue from the blind loop, where germinal centers were also observed in ILF.

Table 6.2: Presence of B lymphocytes in serially sectioned jejunal lymphocyte-filled villi (LFV).

Tissue	Presence of B lymphocytes			
	B lymphocyte follicle	B lymphocyte cluster	Scattered B lymphocytes	No B lymphocytes
Normal jejunum (5)[a] (Case5)	0	0	1b	4[b,c]
Blind loop (10)[a] (Case 2)	1[b]	4[b,c]	5[b]	0

[a]Total number of LFV examined
[b]Serial sections stained with anti-CD19 (mAb FMC63)
[c]Alternate sections stained with anti-CD20 (mAb L26).

Figure 6.11

Lymphocyte-filled villus in normal jejunal mucosa (case 5). Serial frozen sections were stained with monoclonal antibodies by the indirect immunoperoxidase technique. **a**-monoclonal antibody L26 (CD20), showing that the lymphocyte-filled villus contains no detectable B cells. **b**- monoclonal antibody FMC52 (MHC-II). Large dendritic cells, beneath the epithelium and scattered in between the lymphocytes in the core and at the base are stained. **c**- monoclonal antibody FMC7 (CD45RA). Only endogenous peroxidase-positive cells in the lamina propria. Original magnification x 83.

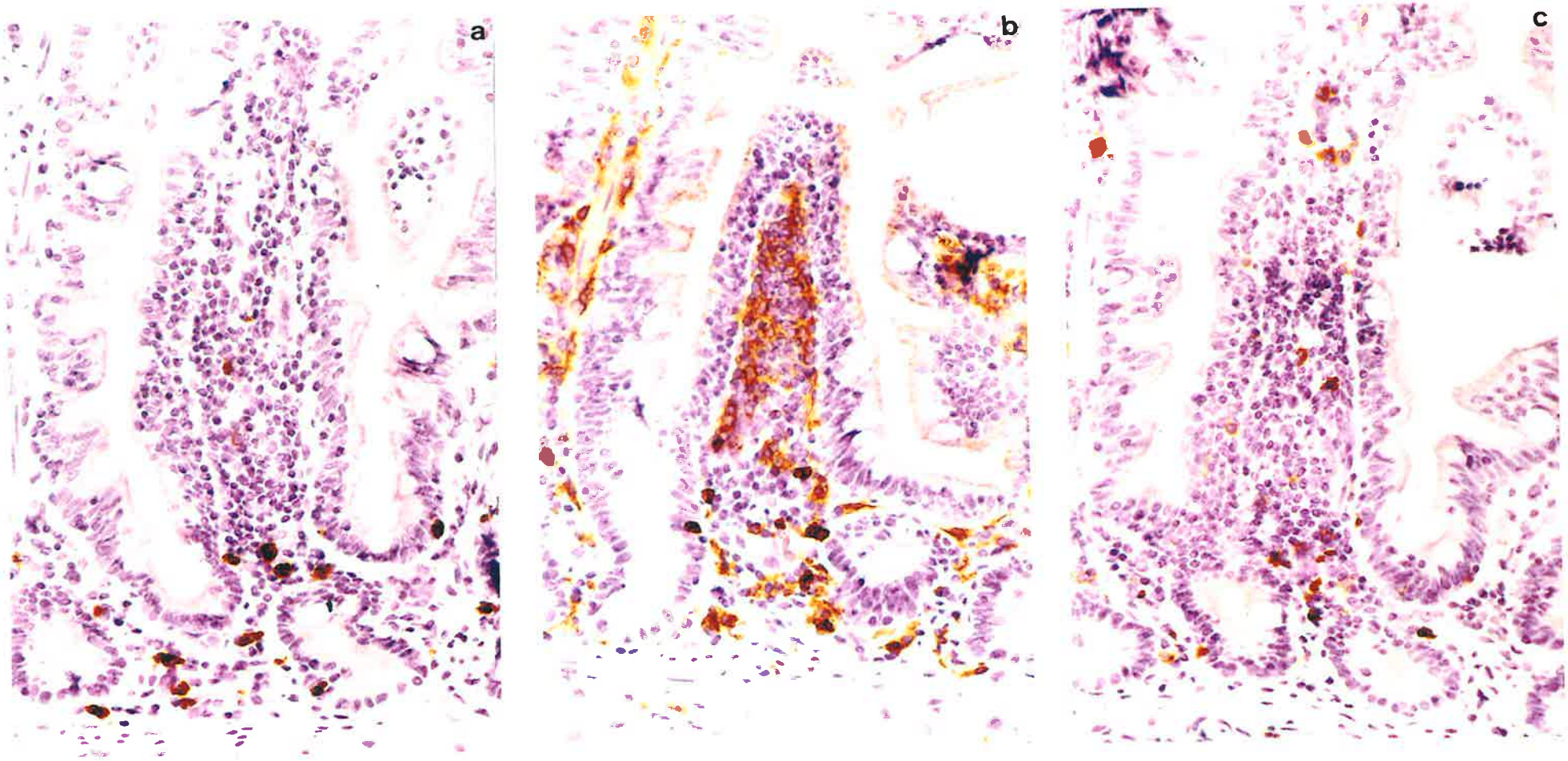
a
b
c

Figure 6.12

Lymphocyte-filled villi in the mucosa from a jejunal blind loop (case 2). **a-c**, frozen sections stained with monoclonal antibody FMC63 (CD19). **d-e**- frozen section from the same structure shown in c, stained with monoclonal antibody FMC52 (MHC class II) and FMC7 (CD45RA) respectively. **a**- scattered CD19-positive B cells in the lamina propria (arrows). **b**- a small cluster of B cells at the base of a lymphocyte-filled villus (arrow). **c**- a lymphocyte-filled villus with a small B cell follicle at the base (arrow). **d-** serial section from c, showing MHC class II-positive B cells, scattered dendritic cells in the lamina propria and staining of the overlying epithelium. **e**- serial section from c, showing B cells express CD45RA molecule. Original magnification b x 41, a, c-e, x 83.

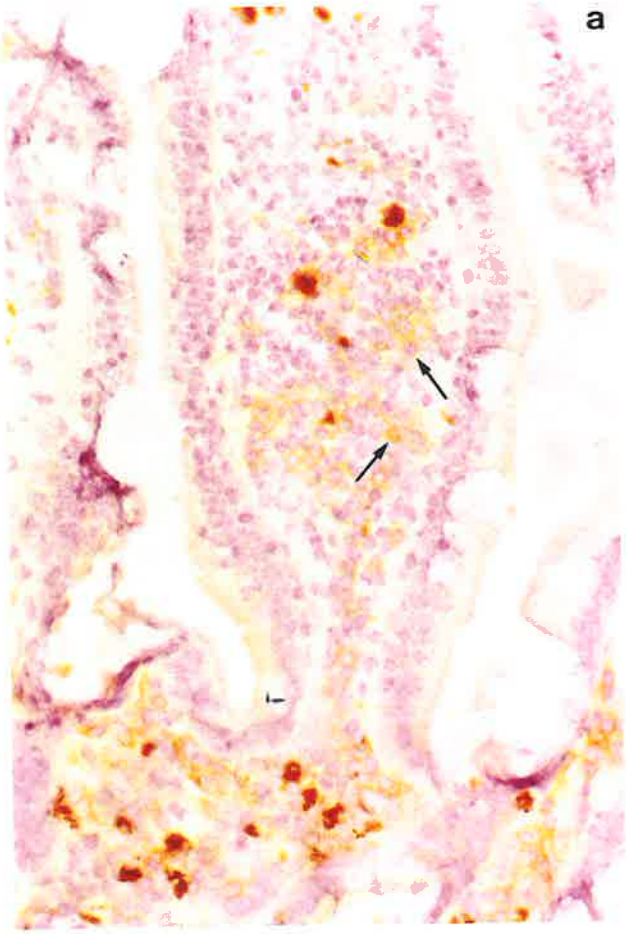
a

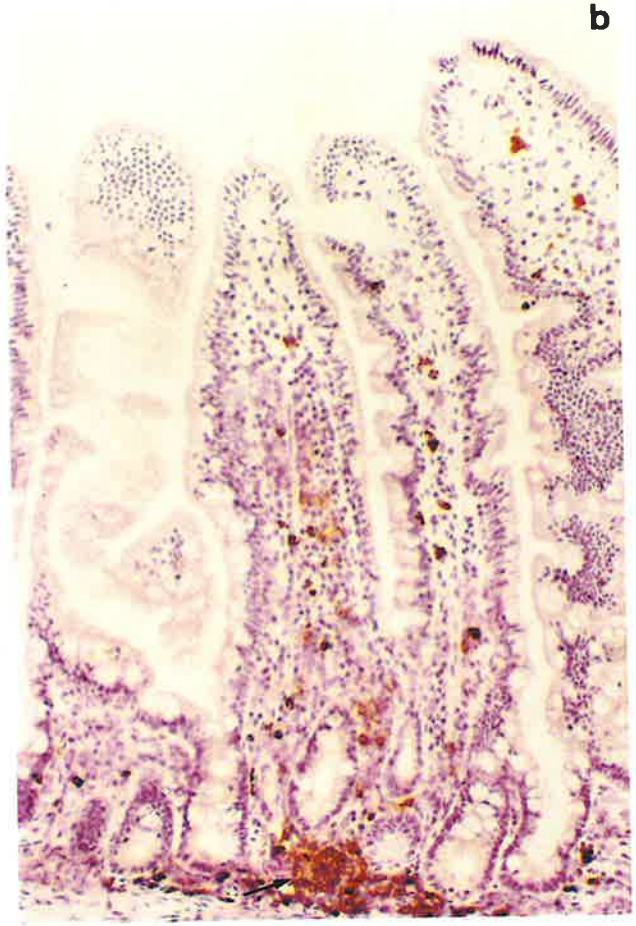
b

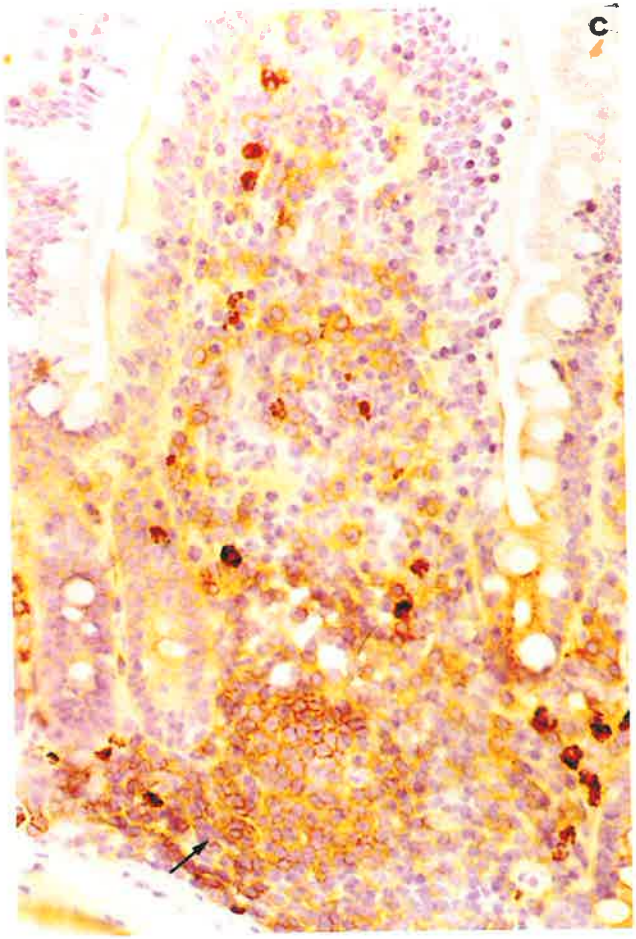
c

The surface antigen phenotypes of other cells in LFV were examined with a panel of mAbs. In full longitudinal sections of LFV, enterocytes in the proximal halves of the villi expressed MHC class II molecules while distal enterocytes expressed progressively less MHC class II molecules (Fig 6.12d). Expression of MHC class II molecules was, therefore, similar in LFV and classical villi with respect to distribution but the level of expression appeared greater in the epithelium of LFV. The phenotypes of IEL in the epithelium of LFV are described below. Within the lamina propria of the LFV, mAb FMC52 (anti-MHC class II) stained large cells with irregular morphology (Figs 6.11b, 6.12d). These were located in the subepithelial areas and were scattered also between the lymphocytes in the cores and bases of the villi. They are believed to be dendritic cells. In those LFV which contained a small B cell follicle (LFV in blind loop) (Fig 6.12c), the B cells in the follicle also expressed MHC-II (Fig 6.12d) and CD45RA (Fig 6.12e). In those LFV with no B-cells in the lamina propria, no $CD45RA^+$ cells were detected (Fig 6.11c).

Most of the lymphocytes in the lamina propria of the LFV were stained by mAbs that recognize the T cell marker CD3 (Fig 6.13a) and staining was similar with mAbs against CD2 (not shown), CD5 (Fig 6.13b) and CD7 (not shown). In those LFV that did not contain B cells, all of the lymphocytes appeared to be T cells that also expressed the CD45RO splice variant (Fig 6.13c). The majority of the T cells in LFV expressed CD4 (Fig 6.13d), while only scattered cells expressed CD8 (not shown). Although HEV were observed in the T cell areas at the bases of ILF and adjacent to the surrounding crypts in the mucosal variants of ILF, similar structures were not found in LFV.

To detect any lymphocytes that resembled immature thymic T cells, LFV were stained with mAbs directed against c-kit (YB5.B8) and CD1a (T6, OKT6). No cells were detected that expressed CD1a (Fig 6.14a). Occasional cells that expressed c-kit were

Figure 6.13

A lymphocyte-filled villus in normal jejunal mucosa (case5). Serial frozen sections were stained with monoclonal antibodies against the T-cell markers CD3, CD4, CD5 and with mAb UCHL-1. **a**- monoclonal antibody OKT3 (CD3) and, **b**- monocolnal antibody WM13 (CD5), showing many T cells in the lamina propria and in the villus epithelium (cf. adjacent villi). **c**- monoclonal antibody UCHL-1 (CD45RO), showing that most of the T cells in the lamina propria and in the villus epithelium have a memory phenotype. **d**- monoclonal antibody OKT4 (CD4), showing that most lymphocytes in the lamina propria express CD4, while most intraepithelial lymphocytes are unstained. Original magnification x 83.

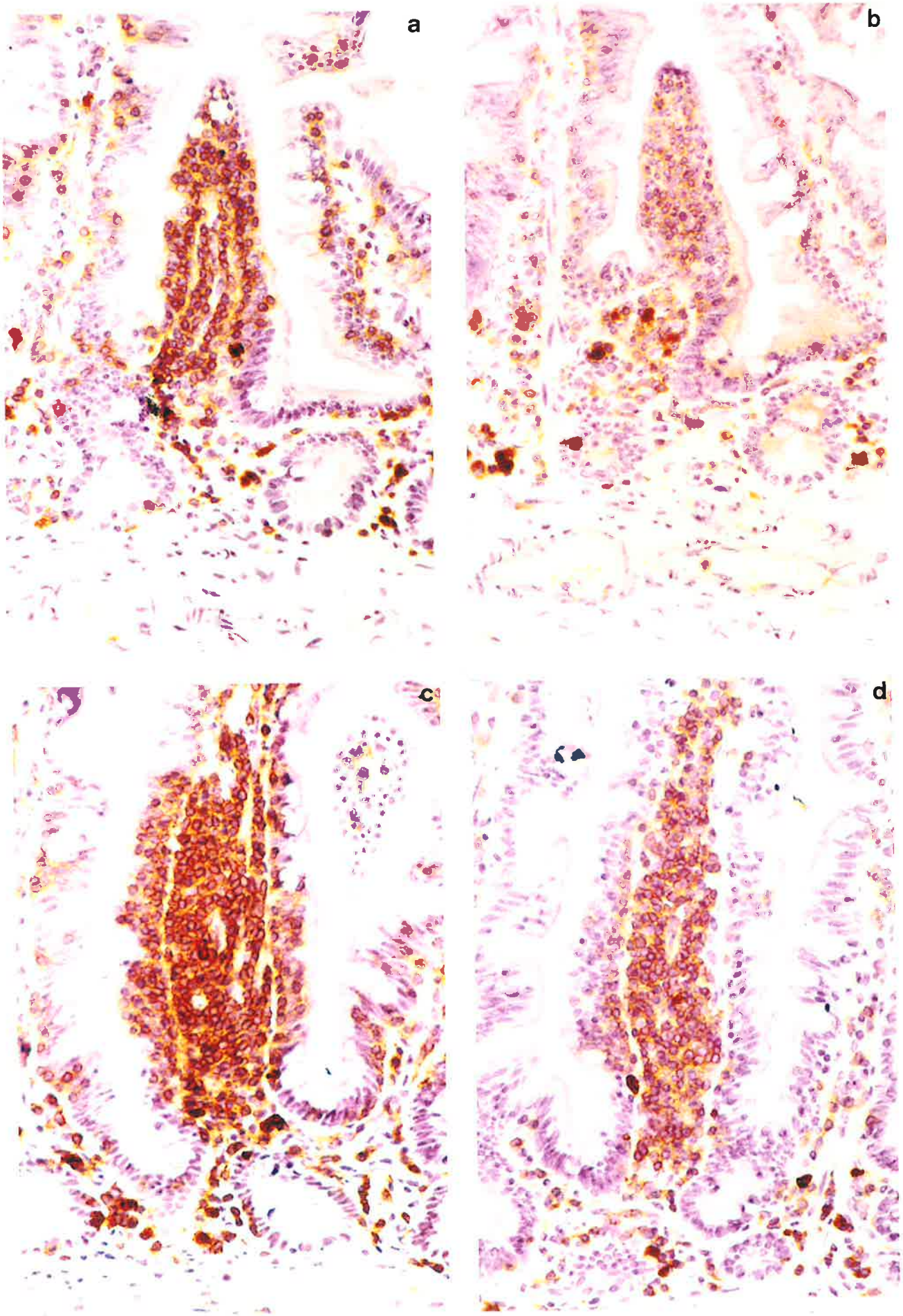
a
b
c
d

Figure 6.14

Lymphocyte-filled villus in normal jejunal mucosa (case 5). Serial frozen sections were stained with monoclonal antibodies OKT6, YB5.B8 and OKT9 by the indirect immunoperoxidase technique. **a**- monoclonal antibody OKT6 (CD1a). No lymphocytes are stained. b- monoclonal antibody YB5.B8 (ckit). Scattered cells are stained. **c**- monoclonal antibody OKT9 (CD71). Scattered cells in the lamina propria and epithelial cells in the crypt and over the distal halves of the villi are stained. Original magnification x 41.

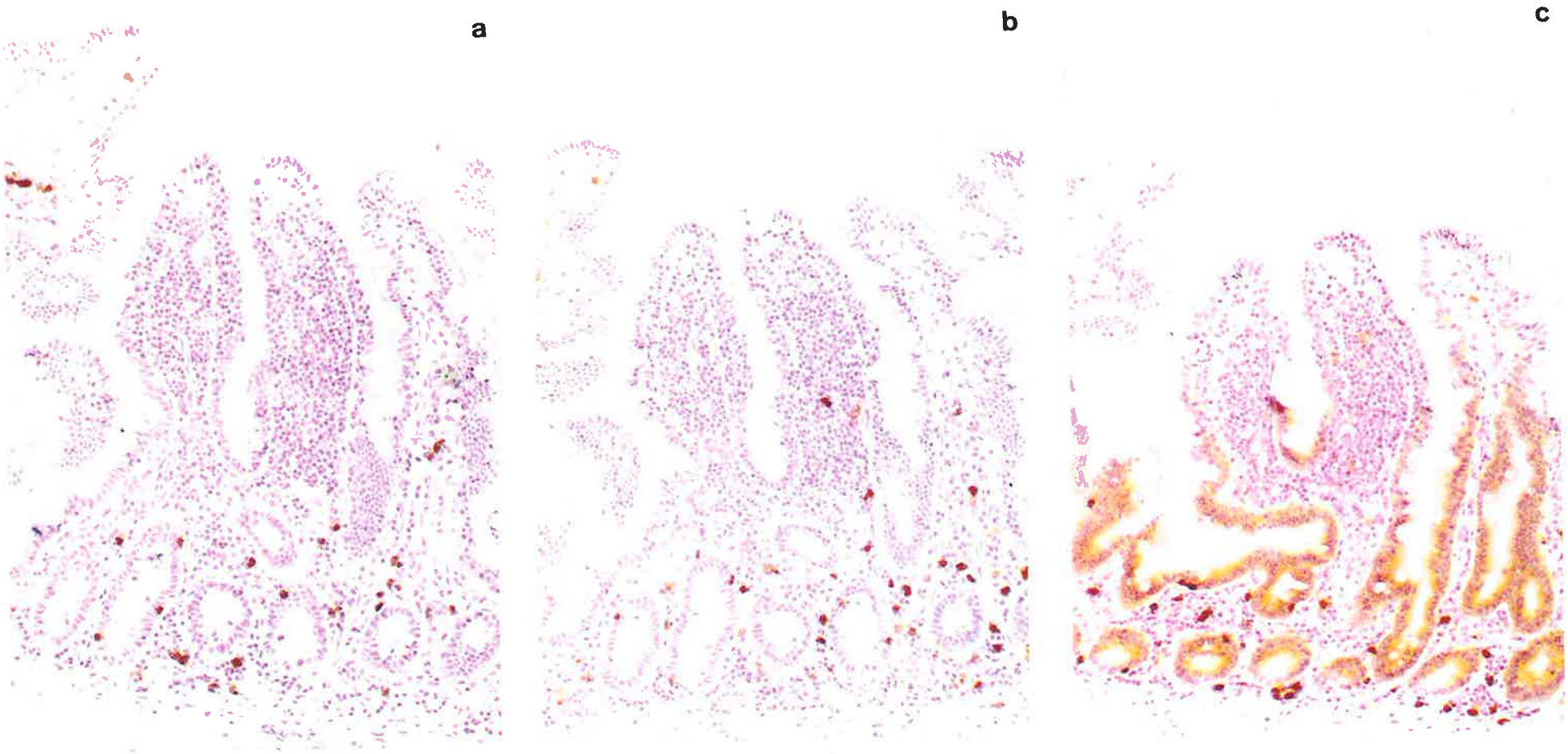
a
b
c

detected (Fig 6.14b) but dual staining with Alcian blue in Carnoy-fixed sections indicated that these were mast cells (not shown). Few, if any, lymphocytes expressed CD25 (mAb 7G7-B6) and only occasional cells expressed CD71 (mAb OKT9, Fig 6.14c). Similar results were obtained irrespective of whether or not LFV had a detectable B cell component. Table 6.3 summarizes the tissue distribution of the cell-surface molecules detected with the complete panel of monoclonal antibodies in ILF and LFV.

6.2.3 Subsets of Intraepithelial Lymphocytes (IEL) in the Epithelium of Lymphoid Aggregations

Most of the IEL in the FAE of ILF and PP, and in the epithelium overlying LFV, were stained by mAbs directed against CD3 and CD7 (Table 6.1). These cells are, therefore, T lymphocytes. The proportions of IEL that expressed these markers were similar in classical villi and in ILF when these structures were compared either in the jejunum (99% versus 97%) or the ileum (87% versus 84%). The proportions of T lymphocytes in the FAE of jejunal PP and in the epithelium of LFV in the jejunum were similar (92% verses 91%) but significantly lower ($P<0.005$) than the proportion observed in either classical villi or ILF. T lymphocytes were in lowest proportion in the FAE of ileal PP (70%). B lymphocytes were rare (<2%) in all epithelia, except for the FAE of PP in the jejunum (12%) and ileum (11%) and they were not seen in the epithelium overlying LFV.

In LFV, as in classical villi in the jejunum, essentially all IEL expressed the CD45RO splice variant (Fig 6.13c), approximately 70% expressed CD8 and 30% expressed CD4 (Table 6.1). A few IEL in the epithelium of classical villi in the ileum (<5%) and in the epithelium overlying ILF in the jejunum (5%) and ileum (8%) expressed the CD45RA splice variant (Table 6.1, Fig 6.6c, 6.10a). However, approximately one third of IEL in the FAE of PP in the jejunum and ileum expressed the CD45RA splice

Table 6.3: Distribution of lymphocyte subsets in isolated lymphoid follicles (ILF) and lymphocyte filled villi (LFV).

Antibodies	Distribution				
	ILF			LFV	
	Germinal Center	Mantle Zone	Dome & Base regions	Normal	Blind loop
anti-CD19	Most	Most	Scattered	-	Variable
anti-CD20	Most	Most	Scattered	-	Variable
anti-MHC-II	Most	Most	Scattered[a]	Scattered[a]	Scattered[a]
anti-CD45RA	Most	Most	Scattered	-	Variable[c]
anti-CD45RO	Scattered[b]	Scattered[b]	Most	Most	Most
anti-CD2	Scattered[b]	Scattered[b]	Most	Most	Most
anti-CD3	Scattered[b]	Scattered[b]	Most	Most	Most
anti-CD4	Scattered[b]	Scattered[b]	Most	Most	Most
anti-CD5	Scattered[b]	Scattered[b]	Most	Most	Most
anti-CD7	Scattered[b]	Scattered[b]	Most	Most	Most
anti- CD8	-	-	Scattered	Rare	Rare
anti-CD25	Scattered[b]	-	Scattered	Scattered	Scattered
anti-CD71	Most	Most	Scattered	Scattered	Scattered
anti-CD1a	-	-	-	Scattered[a]	Scattered[a]
anti-c-kit	-	-	Scattered[d]	Rare[d]	Rare[d]

[a]Interdigitating cells and occasional B cells

[b]T cells

[c]B cells

[d]Mast cells

variant. While some of the CD45RA-positive cells may have been B cells, the majority must have been T cells. IEL did not express CD25 or CD71 in any of these epithelia (not shown). Furthermore, IEL in the epithelium of classical villi, LFV and ILF did not express either c-kit or CD1a (not shown).

6.3 DISCUSSION

This histological and immunohistological study of the mucosa of the human small intestine was undertaken to search for novel lymphoid structures similar to those described as "crypto-patches" in mice (Kanamori *et al.,* 1996) and "lymphocyte filled villi" in both rats (Mayrhofer & Brooks, 1995) and mice (Chapters 3-5, this thesis). In these latter species, structures of this sort are solitary and they differ from PP by containing a majority of lymphocytes that express neither surface immunoglobulin nor the T cell receptor. Because crypto-patches and rodent LFV contain few or no B cells, a small number of T cells, a majority population of lymphocytes that expresses same surface antigens expressed by immature T cells and they are present in athymic (nude) mice and rats, it has been suggested that they may be specialized sites that support primary T cell differentiation. The studies described herein have been directed, therefore, towards recognized solitary lymphoid tissues in the human small bowel mucosa and to the identification of any other solitary lymphoid aggregations that might have been overlooked in the past.

The two solitary lymphoid structures that have been described in human small intestine are ILF and SLA (Morson & Dawson, 1979). Neither has been investigated thoroughly with respect to structure, lymphocyte composition or function. In this study, serial histological sections have revealed that SLA are in all cases submucosal extensions from an overlying ILF. Separate description of SLA is therefore, both redundant and misleading. SLA are not separated anatomically from immunological events in the mucosa, as they have access to lumenal antigens via the overlying follicle with its specialized epithelium. The term ILF is sufficient to describe the complete structure, which includes the submucosal as well as the mucosal component. The typical ILF is similar to the follicular units that compose PP. The presence of HEV in the submucosal extension and of GC in the mucosal follicles suggests that functionally, ILF are secondary

lymphoid tissues. The distribution of ILF was similar to PP in that they were more frequent in ileum (1 per 28 villi) than in jejunum (1 per 269 villi). However, as there was only one sample of ileum in the study, there should be caution that ILF could be over-represented as this specimen also contained a PP.

Variants of the typical ILF have also been observed. These are either confined completely to the mucosa or they may erode the superficial fibers of the muscularis mucosa. In most cases, the follicles in these mucosal variants did not contain GC, suggesting that they are relatively inactive under normal circumstances. However, GC were observed in these variants in the tissue that was obtained from a blind loop (Case 2), suggesting that they can be activated under circumstances of microbial colonization of the small intestine. The mucosal varients contain HEV and like typical ILF, are presumably sites of lymphocyte recirculation.

The immunohistochemical findings support the conclusion that typical ILF and their mucosal variants are secondary lymphoid tissues. In both cases, they contain a follicle that consists of B lymphocytes which were identified by expression of CD19, CD20 and CD45RA. The GC in typical ILF (and in the mucosal variants in the mucosa from the blind loop) contain centroblasts and centrocytes that express CD19, MHC class II and the CD45RA splice variant. Irrespective of the anatomical location of the ILF in the small intestine, those that have GC resemble more closely the follicles in jejunal PP, where centrocytes and centroblasts also express the CD45RA isoform but express the CD45RO isoform only weakly (see below).

The subepithelial tissue overlying the follicles in ILF contains mainly $CD45RO^+$ T lymphocytes, interspersed with dendritic cells that express MHC class II molecules. This area resembles the dome region of follicles in PP. Furthermore, the increased frequency of both total IEL and $CD4^+$ IEL in the epithelium overlying ILF is

similar to that described in other FAE (Rowinski *et al.,* 1984; Bjerke *et al.,* 1988; Brandtzaeg & Bjerke, 1990). A difference, however, was the lower frequency of cells expressing the CD45RA splice variant in the FAE of ILF compared with the FAE of PP. There is no obvious reason for this difference, which is observed both in the jejunum and the ileum. It is not accounted for by differences in the ratio of $CD4^+$ to $CD8^+$ T cells in either part of the intestine. A possibility that requires further investigation is that the recruitment of lymphocytes into ILF via HEV is biased strongly towards memory $CD4^+$ T cells which recruitment into PP is more equally balanced between $CD45RA^+$ and $CD45RO^+$ cells. The basal region of variant mucosal ILF consists mainly of $CD45RO^+$ T lymphocytes with interspersed MHC class II-positive interdigitating cells. This area was larger in typical ILF, which extend into the muscularis mucosa. Only small numbers of $CD45RA^+$ cells were present in the corona and at the bases of ILF. Monoclonal antibodies which detect immature T cell populations in the thymus (anti-CD1a, anti-CD25, anti-c-kit) labelled few or no lymphocytes in ILF.

Taken together with The morphological findings, the immunohistochemical evidence supports the view that ILF are secondary lymphoid organs with close similarities to PP (especially to PP in the jejunum). Similar structures containing follicles of B lymphocytes are common in the mouse small intestine. The numbers of macroscopic ILF in the small intestine of Balb/c mice has been estimated to be approximately 45 (Poskit *et al.,* 1984) but our own observations suggest that the number of microscopic ILF would be much larger (Moghaddami & Mayrhofer, unpublished).

It is interesting to speculate that ILF may represent a reserve of mucosal lymphoid tissue that can be activated under conditions of increased mucosal antigenic drive. In particular, the mucosal variants of ILF appear to be relatively quiescent and unobtrusive under normal circumstances. The appearance of activation, with GC formation, in the ILF from a blind loop suggests that microbial colonization of the gut

lumen may induce hypertrophy of these tissues. It is noteworthy that ILF are reported to be more frequent in duodenitis (Whitehead *et al.,* 1975) and infectious hepatitis (Astaldi *et al.,* 1969), while nodular lymphoid hyperplasia in the small intestine has been reported in association with hypogammaglobulinema (Ajdukiewicz *et al.,* 1972) and with carcinoma of the caecum (Whitehead, 1990). These conditions may all be associated with colonization of the small intestine by bacteria and other microorganisms and the lymphoid hyperplasia may reflect a patho-physiological response by this scattered reserve of organized mucosal lymphoid tissue to antigens from this flora. A similar process might bring to macroscopic prominence clusters of rudimentary follicles and explain the puzzling observation by Cornes (1965a) that the number of PP in human intestine increases during childhood.

Differential expression of the CD45RO splice variant by GC cells in jejunal and ileal PP does not appear to have been described previously. Acute activation of B cells *in vitro* results in variable and only minor upregulation of CD45RO, while even B cells in GC of human tonsil and lymph node express the CD45RA splice variant exclusively (Zola *et al.,* 1990). On the other hand, some normal plasma cells express CD45RO (Zola *et al.,* 1990) and transition from the CD45RA to the CD45RO splice variant has been described in the maturation of human myeloma cells, culminating in the loss of all splice variants from end-stage plasma cells (Pilarski & Jensen, 1992). Pentilla *et al.* (1995) have observed a subset of circulating antibody secreting cells (plasmablasts) that expresses both CD45RA and CD45RO splice variants in human volunteers immunized orally with a live attenuated typhoid vaccine. This observation suggests that some recent PP emigrants express the CD45RO splice variant. Our observations suggest that expression of CD45RO by B cells in the GC of ileal PP may reflect chronic antigenic stimulation (possibly by enteric microflora) and more advanced differentiation of the cells towards plasmablasts than is the case in GC of jejunal PP. Furthermore, ileal PP might be

the origin of the CD45RO-positive subset of antibody secreting cells in the circulation. Germinal center cells in PP and ILF from the blind loop of jejunum (case 2) did not express this marker. Further studies are required to determine whether the expression of CD45RA by GC in these jejunal structures reflects that nature of antigenic stimulation or whether terminal stages of B cell development in these structures is different intrinsically.

The third solitary lymphoid aggregation described in this study has been designated a "lymphocyte-filled villus" because it resembles superficially the LFV that we have observed in the rodent small intestine. LFV in the human small intestine were confined to the jejunum, where they had dimensions similar to classical villi and occurred at a frequency of approximately 1 per 230 villi. The morphological features that distinguish LFV from classical villi are the presence of tightly-packed lymphocytes which fill most of the lamina propria and a higher concentration of IEL in the overlying epithelium. The IEL in the epithelium of LFV are enriched for T lymphocytes that express CD4 and often they are found in clusters. These findings suggest that the epithelium of LFV is similar to the FAE overlying PP and ILF and that as in PP, there may be M cells which envelope clusters of lymphoid cells. However, a difference from the FAE of both PP and ILF is the complete absence of IEL that express the CD45RA splice variant from the epithelium overlying LFV. There are also important structural differences between LFV and ILF. In particular the former lack HEV and do not have obvious lymphoid follicles.

The immunohistochemical studies indicate that the LFV in humans are heterogeneous with respect to cellular composition. In all cases (15 LFV in total), the majority of lymphocytes in the lamina propria were T cells (positive for CD3, CD5 and CD7) which expressed the CD45RO splice-variant (memory phenotype). The subepithelial region of the LFV contained large, irregular cells that expressed MHC class II antigens and these cells also ramified between the lymphocytes in the central lamina

propria. These dendritic cells, some of which expressed CD1a, are similar to those observed in the domes of PP follicles and ILF.

The lymphocytes in LFV did not express CD1a or ckit and only rare cells expressed CD25. Although a subpopulation of lymphocytes in human thymus expresses CD45RO (Pilarski *et al.,* 1989), the absence of other markers that are expressed early in the differentiation of T lymphocytes suggests strongly that the cells expressing CD45RO in LFV are memory cells and that LFV in adult humans are not the functional homologues of LFV in mice and rats.

A further distinction between LFV in humans and in laboratory rodents is the presence in the human structures of a variable number of B lymphocytes. Of five LFV sectioned serially from a segment of normal jejunum, only one contained a few scattered CD19-positive cells and the remaining four LFV sectioned from this specimen contained either no B lymphocytes or rare stained cells. Ten LFV were sectioned serially in tissue obtained from a blind loop of jejunum. Of these, one contained a small follicle of CD19-positive cells near the base (without GC), four contained a small cluster of cells expressing CD19 or CD20 and the remaining five contained scattered CD19-positive cells.

Together, the histological and immunohistological findings suggest that LFV are anatomical entities that are distinct from classical villi. In all cases, LFV lie adjacent to mucosal villi which do not have either increased numbers of IEL in the overlying epithelium or infiltration of the lamina propria with mononuclear cells. Large MHC class II-positive cells, which in adjacent villi were fewer in number and located mainly in the tips of the villi, in LFV were scattered throughout the villus. Furthermore, as mentioned above, the ratio of CD4-positive to CD8-positive IEL was similar in LFV and in the FAE of either PP or ILF and the clustering of the IEL is suggestive that M cells are present.

While It could be argued that these characteristics of LFV are secondary to inflammation localised to a single villus, it seems more likely that these structures are laid down developmentally and that they are distinct both structurally and functionally from classical villi.

The lymphocyte composition of LFV in the normal mucosa suggests that the physiological functions of LFV in adult humans are related principally to the presentation of antigens to T lymphocytes of the memory phenotype. The antigens involved could be transported through a specialised epithelium resembling the FAE of PP and processed by the many DC in the LFV. The fate and effector functions of the small numbers of T lymphocytes that express CD25 in LFV is unknown. However, it appears that B lymphocytes can be recruited into LFV. This may occur under conditions of increased antigenic drive, because B cell clusters and rudimentary follicles were observed in some LFV from a blind loop. It seems possible, therefore, that the LFV with a B cell complement are part of a continuum (at least under pathological circumstances) which merges through mucosal variants of ILF with typical ILF. At least one of the functions of CD4-positive T lymphocytes in such LFV could be to provide help to B lymphocytes.

HEV have not been identified in association with LFV and it is not possible, therefore, to comment on access of the recirculating lymphocyte pool to these structures. Nevertheless, we have found no evidence that LFV in humans are primary lymphoid organs. It appears likely that, together with PP and ILF, they are diffuse components of the gut-associated secondary lymphoid tissues. It remains to be seen whether each component has a specialised function (Heatley *et al.,* 1981; Hamilton *et al.,* 1981; Serizawa *et al.,* 1993) or whether with appropriate antigenic stimulation all can take on the characteristics of the ILF observed in the blind loop, with the development of follicles and germinal centers. However, an important caveat to these conclusions is that only material from adults have been examined. It is conceivable that LFV could have a

primary lymphoid function during development and early childhood, while taking on a secondary function later in life. The same structures might then play last to a novel subset of lymphocytes and further studies are required to determine whether they have distinctive phenotypic characteristics and specialized functions.

CHAPTER 7

CONCLUSION

7.1 SUMMARY AND CONCLUSION

The epithelium is not the only possible site of extrathymic T cell differentiation in the small intestine. Detailed histochemical studies by Mayrhofer and Brooks (1995) in the rat small intestine described novel structures which have been designated as lymphocyte-filled villi. These novel structures have been suggested to be additional sites of primary extrathymic T cell differentiation. Similar structures have been identified herein in mouse, hamster and human small intestine, thus confirming the hypothesis that lymphoid aggregations similar to LFV in the rat small intestine are also present in other species. Furthermore, LFV have been shown to be distinct from Peyer's patches in rats, mice and hamsters. A more detailed study is required in hamsters. In rats and mice, the lymphocytes in LFV express unique surface antigen phenotypes and there is strong circumstantial evidence that these structures are sites of primary T cell differentiation. However, unlike the thymus, exogenous (lumenal) antigens may play a role in repertoire expansion/selection in these structures. Studies on LFV in adult humans indicate that they are functionally different from the structures observed in mice and rats.

7.1.1 LFV in Mice

LFV in mice are distributed throughout the small intestine, where they are limited to the mucosa. The presence of LFV in LTα, LTβ, TNFα and TNF/LT gene knockout mice indicates that neither TNFα nor LT are required for their organogenesis. This finding, together with the distribution of LFV at all points on the circumference of the small intestine, are clear differentiating points from PP and isolated lymphoid follicles. The presence of LFV in nude mice showed that they are thymus-independent, while their presence in mice with the *scid* mutation, or in mice in which the RAG-1 gene has been inactivated, indicates that the majority of lymphocytes in these structures are at a

stage of differentiation that has not required re-arrangement of genes encoding antigen-specific receptors.

The main population of lymphocytes in LFV have the phenotype Thy-1$^+$, CD3$^-$, α/βTCR$^-$, γ/δTCR$^-$ CD4$^-$, CD8$^-$, B220$^-$, sIg$^-$. Although lymphocytes in LFV have a non-T, non B phenotype, they do not express NK1.1 and are not thought to be NK cells. Most of the lymphocytes at the bases of LFV expressed the IL-2Rα and the antigens TSA-1/Sca-2, HSA and Pgp-1, giving them a phenotype that is similar to the phenotype of immature T cells. In addition, some of the basal lymphocytes express CD4 in addition to TSA-1/Sca-2 and CD25. The lack of TCR or CD3 expression by this subset implies that it is not composed of mature CD4$^+$ T cells. Moreover, in contrast to CD4$^+$ mature T cells, they did not bear the TSA-2 (MTS-32) molecule. Most of the CD4$^+$ cells in LFV did not express CD8 and only rare cells were double positive CD4$^+$CD8$^+$ cells. As in the thymus, the CD4$^+$ cells in LFV may be early progenitors of T cells.

Together, the data support the hypothesis that lymphocytes in LFV have phenotypes that are different from either IEL, the major populations in the PPs or the lymphocytes in the lamina propria of adjacent villi. The immature phenotype of the major population of lymphocytes in LFV in normal mice as well as in the mutant mice indicates that LFV may be primary sites for T cell generation. In support of this view, a significant proportion of lymphocytes were in cell cycle, particularly in the center and at the base of LFV. Furthermore, the lymphocytes in LFV were sensitive to hydrocortisone, indicating that at least some of them share with immature thymocytes sensitivity to glucocorticoid steroid hormones. However, the product of the RAG-1 gene has not been detected in LFV lymphocytes and nearly all of the cells in LFV appear to complete their normal development without expressing detectable levels of re-arranged TCR gene products.

Most of lymphocytes in the subepithelial areas of LFV had the phenotype MTS-37$^+$CD25$^-$. The MTS 37$^+$ sub-population of lymphocytes was absent in the LFV from nude mice as well in LFV from the scid mice and RAG-1 gene knockout mice. This suggests that expression of the MTS 37 antigen is regulated by classical thymus-derived T cells rather than by events linked directly with the activation of TCR gene re-arrangement. The population of MTS-37$^+$CD25$^-$ lymphocytes is probably at a later stage of differentiation than the MTS-37$^-$CD25$^+$ lymphocytes in the centers of LFV. The former subset could correlate with the labelled cells in the subepithelial areas several hours after commencing injections of ^{3}HTdr. The labelled cells beneath the epithelium at this time could be the progeny of dividing cells at the base of villus that have migrated towards the subepithelial areas. This possibility requires investigation by pulse-chase experiments and the use of immunohistochemistry in combination with autoradiography. The transition from MTS 37$^-$ CD25$^+$ to the MTS 37$^+$ CD25$^-$ phenotype could be linked to events leading to re-arrangement of the genes encoding the TCR, because this progression does not appear to occur in scid mice or RAG-1 gene knockout mice. Further studies are needed to exclude the possibility that the RAG-1 gene becomes active during the residence of some LFV lymphocytes.

Overwhelming evidence suggests that a subset of murine intestinal intraepithelial lymphocytes matures extrathymically. Yet, many aspects of that process remain unknown. Whether the development of extrathymic T cells in the intestine takes place within the intestinal epithelium or elsewhere in not clear. A possible site external to the epithelial compartment of the intestine is the LFV. While electron microscopy studies have shown that the lymphocytes in crypto-patches may migrate into the overlying villus epithelium (Saito *et al.,* 1998), it is difficult to imagine how local tissue migration could distribute cells to the entire epithelial layer of the small intestine. However, the same authors have shown that adoptive transfer of lymphocytes from LFV of nude mice into

scid recipients leads to reconstitution of T cells in the IEL population of the host. This suggests that haematogenous seeding of the gut epithelium could occur from LFV under normal circumstances.

The large and irregular cells in LFV that express CD11c and MHC class II molecules are believed to be dendritic cells. They were present in the subepithelial regions and also between the lymphocytes. They were observed also between the epithelial cells overlying LFV but never in the epithelium overlying classical villi. It is possible that as in PP, the epithelium of LFV is specialized for antigen absorption and that lumenal antigens influence lymphocyte development within LFV. Most of the CD11c$^+$, MHC-II$^+$ cells did not stain with the macrophage marker F4/80. The non-lymphoid cells in LFV had phenotypic similarities with those in the thymus but they also exhibited some differences. The dendritic cells in LFV, as in the thymus (Vremec *et al.*, 1992; Ardavin & Shortman, 1992), expressed the leukocyte common antigen CD45, Thy-1, Sca-2, TSA-1, HSA, and Pgp-1. Moreover, the dendritic cells in the subepithelial regions of LFV appear to express CD25. In contrast, DC in mouse and human thymus express CD8 and CD4 molecules (Vremec *et al.*, 1992; Winkel *et al.*, 1994), while neither of these molecules was detected on DC in LFV. In LFV, mAbs MTS 20, MTS 24, MTS 33 and MTS 37 stained large and irregular non-lymphoid cells that were located mainly in sub-epithelial areas. These cells did not co-express CD11c antigen. They may be immature DC that have not expressed CD11c, as suggested by Kelsall & Strober (1996) in the case of similar cells in PP. However, in the thymus, mAbs MTS 33 and MTS 37 recognise subsets of thymic epithelial cells in addition to thymocytes (Godfrey *et al.*, 1990), while mAbs MTS 9, MTS 10, MTS 20, MTS 24 and MTS 44 also recognize different sub-populations of thymic epithelial cells (Kampinga *et al.*, 1989; Godfrey *et al.*, 1990). Further studies are required to exclude the possibility that the CD11c$^-$

subepithelial cells could have epithelial origin. However, no cells in LFV stained with mAbs MTS 9, MTS 10 or MTS 44.

The presence of dendritic cells beneath the epithelium raises the question as to what role these accessory cells play. The CD11c positive cells may be involved in presentation of antigens for initiating immune responses to lumenal antigens, in sustaining lymphocyte-mediated suppression of immune responses to foreign antigens and induction of oral tolerance, or possibly in negative selection during T cell differentiation.

Due to the small size of these structures, their diffuse distribution and the lack of appropriate markers which clearly distinguish between the $CD3^{-}CD4^{-}CD8^{-}$ triple negative cells in LFV and the subpopulation of triple negative IEL, studies on LFV rely on in *situ* detection of tissue antigens, gene transcripts and cell division. The important questions of cell lineage and the differentiation potential of the lymphocytes in LFV awaits studies utilising adoptive transfer and in vitro culture of defined cell populations.

7.1.2 LFV in Humans

The structure of solitary lymphoid tissues in the mucosa of the human small intestine was examined to test the hypothesis that structures similar to LFV in rats and mice occur also in human small intestine. The hypothesis was tested by a histological and immunohistological examination of resection specimens of normal human small intestine collected at operation from six individuals.

The distribution of isolated lymphoid follicles (ILF) and submucosal lymphoid aggregations (SLA), their structures and the surface antigen phenotypes of the lymphocytes within them have been compared with PP. The results of histological examination showed that these two previously described lymphoid aggregations are

components of a single structure. The complete structure contains a B cell follicle and a submucosal area containing mainly T lymphocytes. Variants of the typical ILF have also been observed. These are either confined completely to the mucosa or they may erode the superficial fibers of the muscularis mucosa. Typical ILF and the mucosal variants both contained HEVs and are presumably sites of lymphocyte recirculation. The morphological findings and immunohistochemical evidence suggests that ILFs are similar to PPs. It is interesting to speculate that ILF may represent a reserve of mucosal lymphoid tissue that can be activated under conditions of increased mucosal antigenic drive. In particular, the mucosal variants of ILF appear to be relatively quiescent and unobtrusive under normal circumstances. The appearance of activation, with GC formation, in the ILF from a blind loop suggests that microbial colonization of the gut lumen may induce hypertrophy of these tissues.

A third structure, designated a lymphocyte-filled villus because of morphological similarities with LFV in rodents, has been identified and compared with the other more organized solitary lymphoid tissues. LFV in the human small intestine were confined to the jejunum, where they had dimensions similar to classical villi. The epithelium overlying the lamina propria of these novel isolated lymphoid structures resembles the follicle-associated epithelium of PP morphologically, although there were differences between LFV and PP in the composition of lymphocytes within this compartment. As in rodents, LFV in normal human intestine did not contain organized follicles and HEV were never observed. The immunohistochemical studies indicate that the LFV in humans are heterogenous with respect to cellular composition. They comprise MHC class II-positive dendritic cells, a majority of memory T cells and a variable B cell component. Immature lymphocytes that expressed either c-kit or CD1a were not observed. LFV in humans differ from those in laboratory rodents by the presence in the human structures of mainly memory T cells and also variable numbers of B lymphocytes.

These results suggest that human LFV are not sites of extrathymic T cell differentiation. Together, the histological and immunohistological findings suggest that LFV are distinct anatomical entities. The lymphocyte composition of LFV in the normal mucosa suggests that the physiological functions of LFV in adult humans are related principally to the presentation of antigens to T lymphocytes of the memory phenotype. The antigens involved could be transported through a specialised epithelium and processed by the many DC in the LFV. The origin of the T cells in LFV is unknown, but the absence of HEV in these structures suggests that they are not sites of lymphocyte recirculation. As discussed below, it is possible that they may contain a specialized population of lymphocytes. It appears that B lymphocytes can be recruited into LFV under some conditions. Increased antigenic drive may be a factor, because B cell clusters and rudimentary follicles were found in some LFV from a blind loop. It seems possible, therefore, that those LFV with a B cell complement are part of a continuum (at least under pathological circumstances) that merges through mucosal variants of ILF with typical ILF. In the absence of evidence that LFV in adult humans are primary lymphoid organs, it appears likely that, together with PPs and ILFs, they are components of the gut-associated secondary lymphoid tissues. However, the analysis presented in this study dealt only with adult human tissues. Therefore, it is possible that in fetal and neonatal human intestinal mucosa LFV could have a different function. It is conceivable that LFV could have a primary lymphoid function during development and early childhood. In later life, they could take on a secondary function, perhaps involving a specialized subset of extrathymically-derived T cells produced by the same structures during early development. Further studies are required to determine whether lymphocytes in LFV have distinctive phenotypic characteristics and specialized functions. Another possibility is that extrathymic T cell development is species specific and that the LFV in human have a different function, in spite of the morphological similarities with LFV in rodents.

7.2 CONCLUSION AND FUTURE DIRECTIONS

Taken together, the results of this study support the hypothesis that structures similar to LFV in the rat small intestine are also present in mice. These structures are possibly sites of extrathymic T cell differentiation. There are difficulties associated with the isolation of lymphocytes from LFV, primarily due to the small size of these structures, their diffuse distribution and the lack of appropriate markers which clearly distinguish between the $CD3^-CD4^-CD8^-$ triple negative cells in LFV and the subpopulation of triple negative IEL. The important questions of cell lineage and the differentiation potential of the lymphocytes in LFV awaits studies utilising adoptive transfer and in vitro culture of defined cell populations, with the caveat that the triple negative populations discussed above can be isolated independently or that they can be distinguished by phenotypic markers.

LFV have been shown in specific pathogen free rats (Mayrhofer & Brooks, 1995), indicating that the generation of lymphocytes within them occurs independently of infective agents. However, the effects on LFV of exposure to antigen or infection has not been studied. It would be interesting to study LFV in germ-free mice and to examine changes that occur after administration of antigen, commensal bacteria or pathogenic micro-organisms.

Together, analysis the phenotypes of lymphocytes in LFV in rats and mice indicates that these organs in both species are may be sites of extrathymic T cell development. However, the cellular contents of these structures in the two species are remarkably different. LFV in the rat contain a subset of TCRαβ $CD4^+$ cells. Proliferating cells in the rat LFV are TCR^- and located in the base of the villi, suggesting that perhaps such cells could be precursors of the TCR^+ cells. In contrast in mice, the cells in LFV

appear to complete their normal development without expressing detectable levels of re-arranged TCR gene products. This is an important difference and it poses the interesting dilemma that if LFV in mice are sites of extra-thymic T cell differentiation, then cells are exported prior to rearrangement of TCR genes or they exit from LFV immediately after this process has commenced.

In contrast, human LFV apparently contain only mature T cells. The absence of immature T cell markers such as CD1a and c-kit in human LFV suggests that LFV in adult humans are not the functional homologous of LFV in mice and rats. As mentioned before, the analysis of human intestine in this study is limited to adult human tissues. Therefore, it is possible that T cell differentiation occurs in human LFV during early development. Studies on LFV in foetal and neonatal human intestinal mucosa are essential. Furthermore, study of these structures in the patients with DiGeorge syndrome (with congenital lack of thymus) would help to elucidate the relationship between LFV and the thymus in humans. However, it is also possible that LFV as sites of extrathymic T cell development is species specific and that the LFV in human serve a different function.

REFERENCES

Abo T, 1993. Extrathymic pathways of T-cell differentiation: a primitive and fundamental immune system. Microbiol Immunol; 37: 247-258.

Abo T, Ohteki T, Seki S, Koyamada N, Yoshikai Y, Masuda T, Rikiishi H, Kumagai K, 1991. The appearance of T cells bearing self-reactive T cell receptor in the livers of mice injected with bacteria. J Exp Med; 174: 417-424.

Adkins B, Mueller C, Okada CY, Reichert RA, Weissman IL, Spangrude GJ, 1987. Early events in T-cell maturation. Ann Rev Immunol; 5: 325-365.

Aggarwal BB, Eessalu TE, Hass PE, 1985. Characterization of receptors for human tumour necrosis factor and their regulation by γ-interferon. Nature; 318: 665-667.

Aihara Y, Bühring HJ, Aihara M, Klein J, 1986. An attempt to produce "pre-T" cell hybridomas and to identify their antigens. Eur J Immunol; 16: 1391-1399.

Ajdukiewicz AB, Youngs GR, Bouchier IAD, 1972. Nodular lymphoid hyperplasia with hypogammaglobulinaemia. Gut; 13: 589-595.

Alimzhanov MB, Kuprash DV, Kosco-Vilbois MH, Luz A, Turetskaya RL, Tarakhovsky A, Rajewsky K, Nedospasov SA, Pfeffer K, 1997. Abnormal development of secondary lymphoid tissues in lymphotoxin beta-deficient mice. Proc Natl Acad Sci USA; 94: 9302-9307.

Amiot F, Boussadia O, Cases S, Fitting C, Lebastard M, Cavaillon JM, Milon G, Dautry F, 1997. Mice heterozygous for a deletion of the tumor necrosis factor-alpha and lymphotoxin-alpha genes: biological importance of a nonlinear response of tumor necrosis factor-alpha to gene dosage. Eur J Immunol; 27: 1035-1042.

Anderson G, Owen JJ, Moore NC, Jenkinson EJ, 1994. Thymic epithelial cells provide unique signals for positive selection of $CD4^+CD8^+$ thymocytes *in vitro*. J Exp Med; 179; 2027-2031.

Anderson G, Moore NC, Owen JJ, Jenkinson EJ, 1996. Cellular interactions in thymocyte development. Annu Rev Immunol; 14: 73-99.

Anderson G, Jenkinson E, 1997. Piecing together the thymic puzzle. Immunology today; 18: 363-364.

Anderson G, Anderson KL, Tchilian EZ, Owen JJT Jenkinson EJ, 1997. Fibroblast dependency during early thymocyte development maps to the $CD25^+$ $CD44^+$ stage and involves interactions with fibroblast matrix molecules. Eur J Immunol; 27: 1200-1206.

Andreu-Sánchez JL, Moreno de Alborán I, Marcos MAR, Sánchez-Movilla A, Martínez-A C, Kroemer G, 1991. Interleukin 2 abrogates the nonresponsive state of T cells expressing a forbidden T cell receptor repertoire and induces autoimmune disease in neonatally thymectomized mice. J Exp Med; 173: 1323-1329.

Androlewicz MJ, Browning JL, Ware CF, 1992. Lymphotoxin is expressed as a heteromeric complex with a distinct 33-kDa glycoprotein on the surface of an activated human T cell hybridoma. J Biol Chem; 267: 2542-2547.

Antica M, Wu L, Shortman K, Scollay R, 1994. Thymic stem cells in mouse bone marrow. Blood; 84: 111-117.

Antonioli DA, Madara JL, 1992. Functional anatomy of the gastrointestinal tract. In: Ming SC, Goldman H, eds. Pathology of the gastrointestinal tract. Philadelphia: Saunders: 14-35.

Arai K, Iiai T, Nakayama M, Hasegawa K, Sato K, Ohtsuka K, Watanabe H, Hanyu T, Takahashi HE, Abo T, 1995. Adhesion molecules on intermediate TCR cells. I. Unique expression of adhesion molecules, $CD44^+$ L-selectin$^-$ on intermediate TCR cells in the liver and the modulation of their adhesion by hyaluronic acid. Immunology; 84: 64-71.

Ardavin C, Shortman K, 1992. Cell surface marker analysis of mouse thymic dendritic cells. Eur J Immunol; 22: 859-862.

Ardavin C, Wu L, Li CL, Shortman K, 1993. Thymic dendritic cells and T cells develop simultaneously in the thymus from a common precursor population. Nature; 362: 761-763.

Arnaud-Battandier F, Bundy BM, O'Neill M, Bienenstock J, Nelson DL, 1978. Cytotoxic activities of gut mucosal lymphoid cells in guinea pigs. J Immunol; 121:1059-65.

Ashman LK, Buhring HJ, Aylett GW, Broudy VC, Muller C, 1994. Epitope mapping and functional studies with three monoclonal antibodies to the c-kit receptor tyrosine kinase, YB5.B8, 17F11, and SR-1. J Cell Physiol; 158: 545-554.

Astaldi G, Airo R, Conrad ME, Penna R, Ceretto F, 1969. Lymphatic follicles and immunologic cell reaction in human jejunal mucosa obtained by peroral biopsy in infectious hepatitis. Advan Exp Med Biol; 5: 473-482.

Bancroft JD, 1982. Enzyme histochemistry in: Bancroft JD, Stevens A eds. Theory and Practice of Histological Techniques. Second Edition. Edinburgh London Melbourne and New York: Churchill Livingstone: 379-405.

Bandeira A, Mota-Santos T, Itohara S, Degermann S, Heusser C, Tonegawa S, Coutinho A, 1990. localization of γ/δ T cells to the intestinal epithelium is independent of normal microbial colonization. J Exp Med; 172: 239-244.

Bandeira A, Itohara S, Bonneville M, Burlen-Defranoux O, Mota-Santos T, Coutinho A, Tonegawa S, 1991. Extrathymic origin of intestinal intraepithelial lymphocytes bearing T-cell antigen receptor γδ. Proc Natl Acad Sci USA; 88: 43-47.

Banks TA, Rouse BT, Kerley MK, Blair PJ, Godfrey VL, Kuklin NA, Bouley DM, Thomas J, Kanangat S, Mucenski ML, 1995. Lymphotoxin-α-dificient mice. Effects on secondary lymphoid organ development and humoral immune responsiveness. J Immunol; 155: 1685-1693.

Barclay AN, Mayrhofer G, 1981. Bone marrow origin of Ia-positive cells in the medulla of rat thymus. J Exp Med; 153: 1666-1671.

Barclay AN, Mason DW, 1982. Induction of Ia antigen in rat epidermal cells and gut epithelium by immunological stimuli. J Exp Med; 156: 1665-1676.

Baxter AG, Kinder SJ, Hmmond KJL, Scollay R, Godfrey DI, 1997. Association between $\alpha\beta TCR^{+}CD4^{-}CD8^{-}$ T-cell deficiency and IDDM in NOD/Lt mice. Diabetes; 46: 572-582.

Bell EB, Sparshott SM, Drayson MT, Ford WL, 1987. The stable and permanent expansion of functional T lymphocytes in athymic nude rats after a single injection of mature T cells. J Immunol; 139: 1379-1384.

Ben-Yehuda A, Szabo P, Dyall R, Weksler ME, 1994. Bone marrow declines as a site of B-cell precursor differentiation with age: relationship to thymus involution. Proc. Natl Acad Sci USA; 91: 11988-11992.

Beutler B, van Huffel C, 1994. Unraveling function in the TNF ligand and receptor families. Science; 264: 667-668.

Biedermann KA, Sun J, Giaccia AJ, Tosto LM, Brown JM, 1991. *scid* mutation in mice confers hypersensitivity to ionizing radiation and a deficiency in DNA double-strand break repair. Proc Natl Acad Sci; 88: 1394-1397.

Bjerke K, Brandtzaeg P, 1983. Immunological characteristics of the dome area of human Peyer's patches: localization of epithelial SC, IgA, HLA-DR determinants, T cells and macrophages. Scand J Immunol; 18: 71 (abstract).

Bjerke K, Brandtzaeg P, 1988. Lack of relation between expression of HLA-DR and secretory component (SC) in follicle-associated epithelium of human Peyer's patches. Clin Exp Immunol; 71: 502-507.

Bjerke K, Brandtzaeg P, Fausa O., 1988. T cell distribution is different in follicle-associated epithelium of human Peyer's patches and villous epithelium. Clin Exp Immunol, 74: 270-275.

Bland P, 1988. MHC class II expression by the gut epithelium. Immunology Today; 9: 174-178.

Bland PW, Warren LG, 1986. Antigen presentation by epithelial cells of the rat small intestine. 1. Kinetics, antigen specificity and blocking by anti-Ia antisera. Immunology; 58: 1-7.

Blumberg RS, Yockey CE, Gross GG, Ebert EC, Balk SP, 1993. Human intestinsal intraepithelial lymphocytes are derived from a limited number of T cell clones that utilize multiple Vβ T cell receptor genes. J Immunol; 150: 5144-5153.

Boehm T, Gonzalez-Sarmiento R, Kennedy M, Rabbitts TH, 1991. A simple technique for generating probes for RNA *in situ* hybridization: an adjunct to genome mapping exemplified by the RAG-1/RAG-2 gene cluster. Proc Natl Acad Sci; 88: 3927-3931.

Bogue MA, Zhu C, Aguilar-Cordova E, Donehower LA, Roth DB, 1996. P53 is required for both radiation-induced differentiation and rescue of V(D)J rearrangement in scid mouse thymocytes. Genes Dev; 10: 553-565.

Boll G, Reimann J, 1995. Lamina propria T cell subsets in the small and large intestine of euthymic and athymic mice. Scand J Immunol; 42: 191-201.

Boll G, Rudolphi A, Spies S, Reimann J, 1995. Regional specialization of intraepithelial T cells in the murine small and large intestine. Scand J Immunol; 41: 103-113.

Bonneville M, Janeway CA, Ito K, Haser W, Ishida I, Nakanishi N, Tonegawa S, 1988. Intestinal intraepithelial lymphocytes are a dintinct set of γδ T cells. Nature; 336: 479-481.

Bosma GC, Custer RP, Bosma MJ, 1983. A severe combined immunodeficiency mutation in the mouse. Nature; 301: 527-530.

Bowen MB, Butch AW, Parvin CA, Levine A, Nahm MH, 1991. Germinal center T cells are distinct helper-inducer T cells. Hum Immunol; 31: 67-75.

Boyd R, 1998. Decision making in thymopoiesis. Australian Society for Immunology 28th Annual Conference; Symposium 16-2.

Boyd RL, Hugo P, 1991. Towards an integrated view of thymopoiesis. Immunology Today; 12: 71-79.

Boyd RL, Tucek CL, Godfrey DI, Izon DJ, Wilson TJ, Davidson NJ, Bean AGD, Ladyman HM, Ritter MA, Hugo P, 1993. The thymic microenvironment. Immunology Today; 14: 445-459.

Boyer PD, Diamond RA, Rothenberg EV, 1989. Changes in inducibility of IL-2 receptor α-chain and T cell receptor expression during thymocyte differentiation in the mouse. J Immunol; 142: 4121-4130.

Brandtzaeg P, 1996. Intraepithelial lymphocytes. Annals New York Academy of Sciences; 778: 12-23.

Brandtzaeg P, Bjerke K, 1990. Immunomorphological characteristics of human Peyer's patches. Digestion; 46 (suppl 2): 262-273.

Brockhaus M; Schoenfeld HJ, Schlaeger EJ, Hunziker W, Lesslauer W, Loetscher H, 1990. Identification of two types of tumor necrosis factor receptors on human cell lines by monoclonal antibodies. Proc Natl Acad Sci USA; 87: 3127-3131.

Browning JL, Ngam-ek A, Lawton P, DeMarinis J, Tizard R, Pingchang Chow E, Hession C, O'Brine-Greco B, Foley SF, Ware CF, 1993. Lymphotoxin β, a novel member of the TNF family that forms a heteromeric complex with lymphotoxin on the cell surface. Cell; 72: 847-856.

Browning JL, Dougas I, Ngam-ek A, Bourdon PR, Ehrenfels BN, Miatkowski K, Zafari M, Yampaglia AM, Lawton P, Meier W, Benjamin CP, Hession C, 1995. Characterization of surface lymphotoxin forms. Use of specific monoclonal antibodies and soluble receptors. J Immunol; 154: 33-46.

Browning JL, Sizing ID, Lawton P, Bourdon PR, Rennert PD, Majeau GR, Ambrose CM, Hession C, Miatkowski K, Griffiths DA, Ngam-ek A, Meier W, Benjamin CD, Hochman PS, 1997. Characterization of lymphotoxin-alpha beta complexes on the surface of mouse lymphocytes. J Immunol; 159: 3288-98.

Budd RC, Cerottini JC, Horvath C, Bron C, Pedrazzini T, Howe RC, MacDonald HR, 1987. Distinction of virgin and memory T lymphocytes. Stable acquisition of the Pgp-1 glycoprotein concomitant with antigenic stimulation. J Immunol; 138: 3120-3129.

Butcher EC, Rouse RV, Coffman RL, Nottenburg CN, Hardy RR, Weissman IL, 1982. Surface phenotype of Peyer's patch germinal center cells: implications for the role of germinal centers in B cell differentiation. J Immunol; 129: 2698-2707.

Camerini V, Panwala C, Kronenberg M, 1993. Regional specialization of the mucosal immune system. Intraepithelial lymphocytes of the large intestine have a different phenotype and function than those of the small intestine. J Immunol; 151: 1765-1776.

Cantrell DA, Smith KA, 1983. Transient expression of interleukin 2 receptors. Consequences for T cell growth. J Exp Med; 158: 1895-1911.

Cao X, Shores EW, Hu-Li J, Anver MR, Kelsall BL, Russell SM, Drago J, Noguchi M, Grinberg A, Bloom ET, Paul WE, Katz SI, Love PE, Leonard WJ, 1995. Defective lymphoid development in mice lacking expression of the common cytokine receptor γ chain. Immunity; 2: 223-238.

Carding SR, Kyes S, Jenkinson EJ, Kingston R, Bottomly K, Owen JJT, Hayday AC, 1990. Developmentally regulated fetal thymic and extrathymic T-cell receptor γδ gene expression. Genes Dev; 4: 1304-1315.

Carroll AM, Bosma MJ, 1991. T-lymphocyte development in scid mice is arrested shortly after the initiation of T-cell receptor δ gene recombination. Genes & Dev; 5: 1357-1366.

Ceredig R, Lowenthal JW, Nabholz M, MacDonald HR, 1985. Expression of interleukin-2 receptors as a differentiation marker on intrathymic stem cells. Nature; 314: 98-100.

Cerf-Bensussan N, Schneeberger EE, Bhan AK, 1983. Immunohistologic and immunoelectron microscopic characterization of the mucosal lymphocytes of human small intestine by the use of monoclonal antibodies. J Immunol; 130: 2615-2622.

Cerf-Bensussan N, Guy-Grand D, Griscelli C, 1985. Intraepithelial lymphocytes of human gut: isolation, characterization and study of natural killer activity. Gut; 26: 81-88.

Chen WF, Scollay R, Shortman K, Skinner M, Marbrook J, 1984. T-cell development in the absence of a thymus: the number, the phenotype, and the functional capacity of T lymphocytes in nude mice. Am J Anat; 170: 339-347.

Chen Y, Inobe J, Marks R, Gonnella P, Kuchroo VK, Weiner HL, 1995. Peripheral deletion of antigen-reactive T cells in oral tolerance. Nature; 376: 177-180.

Classon BJ, Coverdale L, 1994. Mouse stem cell antigen Sca-2 is a member of the Ly-6 family of cell surface proteins. Proc Natl Acad Sci USA; 91: 5296-5300.

Cobbold SP, Jayasuriya A, Nash A, Prospero TD, Waldmann H, 1984. Therapy with monoclonal antibodies by elimination of T-cell subsets in vivo. Nature; 312: 548-551.

Coffman RL, Weissman IL, 1981a. A monoclonal antibody that recognizes B cells and B cell precursors in mice. J Exp Med; 153: 269-279.

Coffman RL, Weissman IL, 1981b. B220: a B cell-specific member of the T200 glycoprotein family. Nature; 289: 681-683.

Coico RF, Bhogal BS, Thorbecke GJ, 1983. Relationship of germinl centers in lymphoid tissue to immunologic memory. J Immunol; 131: 2254-2257.

Conlon PJ, Morrissey PJ, Nordan RP, Grabstein KH, Prickett KS, Reed SG, Goodwin R, Cosman D, Namen AE, 1989. Murine thymocytes proliferate in direct response to interleukin-7. Blood; 74: 1368-1373.

Cornes JS., 1965a. Number, size, and distribution of Peyer's patches in the human small intestine. Gut; 6: 225-229.

Cornes JS., 1965b. The effect of age on Peyer's patches. Gut, 6: 230-233.

Crabbé PA, Nash DR, Bazin H, Eyssen H, Heremans JF, 1970. Immunohistochemical observations on lymphoid tissues from conventional and germ-free mice. Lab Invest; 22: 448-457.

Craig SW, Cebra JJ, 1971. Peyer's patches, an enriched source of precursors for IgA-producing immunocytes in the rabbit. J Exp Med; 134: 188-200.

Crispe IN, Bevan MJ, 1987. Expression and functional significance of the J11d marker on mouse thymocytes. J Immunol; 138: 2013-2018.

Crispe IN, Moore MW, Husmann LA, Smith L, Bevan MJ, Shimonkevitz RP, 1987. Differentiation potential of subsets of $CD4^- 8^-$ thymocytes. Nature; 329: 336-339.

Crispe IN, Huang L, 1994. Neonatal, moribund and undead T cells: the role of the liver in T cell development. Semin Immunol; 6: 39-41.

Crispe IN, Mehal WZ. Strange brew, 1996. T cells in the liver. Immunology Today; 17: 522-525.

Critchfield JM, Racke MK, Zuniga-Pflucker JC, Cannella B, Raine CS, Goverman J, Lenardo MJ, 1994. T cell deletion in high antigen dose therapy of autoimmune encephalomyelitis. Science; 263: 1139-1143.

Croitoru K, Stead RH, Bienenstock J, Fulop G, Harnish DG, Shultz LD, Jeffery PK, Ernst PB, 1990. Presence of intestinal intraepithelial lymphocytes in mice with severe combined immunodeficiency disease. Eur J Immunol; 20: 645-651.

Croitoru K, Ernst PB, 1993. Intraepithelial lymphocyte lineage and function. The interactions between the intestinal epithelium and the intraepithelial lymphocyte. In

Kiyono H, McGhee JR, eds. Mucosal Immunology: Intraepithelial Lymphocytes. New York: Raven Press: 79-88.

Croitoru K, Bienenstock J, 1994. Characteristics and functions of mucosa-associated lymphoid tissue. In: Ogra PL, Lamm ME, McGhee JR, Mestecky J, Strober W, Bienenstock J, eds. Handbook of Mucosal Immunology. San Diego: Academic Press, Inc: 141-149.

Crompton T, Moore M, MacDonald HR, Malissen B, 1994. Double-negative thymocyte subsets in CD3ζ chain-deficient mice: absence of $HSA^{+}CD44^{-}CD25^{-}$ cells. Eur J Immunol; 24: 1903-1907.

Crowe PD, VanArsdale TL, Walter BN, Ware CF, Hession C, Ehrenfels B, Browning JL, Din WS, Goodwin RG, Smith CA, 1994. A lymphotoxin-β-specific receptor. Science; 264: 707-710.

Cuff CF, Cebra CK, Rubin DH, Cebra JJ, 1993. Developmental relationship between cytotoxic α/β T cell receptor-positive intraepithelial lymphocytes and Peyer's patch lymphocytes. Eur J Immunol; 23: 1333-1339.

Cummins AG, Steele TW, LaBrooy JT, Shearman DJC, 1988a. Maturation of the rat small intestine at weaning: changes in epithelial cell kinetics, bacterial flora, and mucosal immune activity. Gut; 29: 1672-1679.

Cummins AG, Munro GH, Miller HRP, Ferguson A, 1988b. Association of maturation of the small intestine at weaning with mucosal mast cell activation in the rat. Immunol Cell Biol; 66: 417-422.

Danska JS, Pflumio P, Williams CJ, Huner O, Dick JE, Guidos CJ, 1994. Rescue of T cell-specific V(D)J recombination in SCID mice by DNA damaging agents. Science; 266: 450-455.

De Geus B, Van den Enden M, Coolen C, Nagelkerken L, Van der Heijden P, Rozing J, 1990. Phenotype of intraepithelial lymphocytes in euthymic and athymic mice:

implications for differentiation of cells bearing a CD3-associated γδ T cell receptor. Eur J Immunol; 20: 291-298.

De Maagd RA, Mackenzie WA, Schuurman HJ, Ritter MA, Price KM, Broekhuizen R, Kater L, 1985. The human thymus microenvironment: heterogeneity detected by monoconal anti-epithelial cell antibodies. Immunology; 54: 745-754.

De Maria R, Fais S, Silvestri M, Frati L, Pallone F, Santoni A, Testi R, 1993. Continuous *in vivo* activation and transient hyporesponsiveness to TCR/CD3 triggering of human gut lamina propria lymphocytes. Eur J Immunol; 23: 3104-3108.

De Togni P, Goellner J, Ruddle NH, Streeter PR, Fick A, Mariathasan S, Smith SC, Carlson R, Shornick LP, Strauss-Schoenberger J, Russell JH, Karr R, Chaplin DD, 1994. Abnormal development of peripheral lymphoid organs in mice deficient in lymphotoxin. Science; 264: 703-710.

Deusch K, Pfeffer K, Reich K, Gstettenbauer M, Daum S, Lüling F, Classen M, 1991. Phenotypic and functional characterization of human TCR $\gamma\delta^+$ intestinal intraepithelial lymphocytes. Curr Top Microbiol Immunol; 173: 279-283.

Dialynas DP, Quan ZS, Wall KA, Pierres A, Quintans J, Loken MR, Pierres M, Fitch FW, 1983. Characterization of the murine T cell surface molecule, designated L3T4, identified by monoclonal antibody GK.1.5: similarity of L3T4 to the human leu-3/T4 molecule. J Immunol; 131: 2445-2451.

DiSanto JP, Muller W, Guy-Grand D, Fischer A, Rajewsky K, 1995. Lymphoid development in mice with a targeted deletion of the interleukin 2 receptor γ chain. Proc Natl Acad Sci USA; 92: 377-381.

Dunkley ML, Husband AJ, 1987. Distribution and functional characteristics of antigen-specific helper T cells arising after Peyer's patch immunization. Immunology; 61:475-482.

Dunn-Walters DK, Spencer J, 1997. Origins of human ileal lamina propria plasma cells. Immunol Cell Biol; 75: A 36 (abstract).

Emoto M, Emoto Y, Kaufmann SHE, 1996. Development of CD8α/β^+ TCR$\alpha\beta$ intestinal intraepithelial lymphocytes in athymic nu/nu mice and participation in regional immune responses. Immunology; 88: 531-536.

Erickson SL, de Sauvage FJ, Kikly K, Carver-Moore K, Pitts-Meek S, Gillett N, Sheehan KCF, Schreiber RD, Goeddel DV, Moore MW, 1994. Decreased sensitivity to tumour-necrosis factor but normal T-cell development in TNF receptor-2-deficient mice. Nature; 372: 560-563.

Ermak TH, Owen RL, 1986. Differential distribution of lymphocytes and accessory cells in mouse Peyer's patches. Anat Rec; 215: 144-152.

Ernst PB, Befus AD, Bienenstock J, 1985. Leukocytes in the intestinal epithelium: an unusual immunological compartment. Immunology Today; 6: 50-55.

Eugster HP, Muller M, Karrer U, Car BD, Schnyder B, Eng VM, Woerly G, Le Hir M, di Padova F, Aguet M, Zinkernagel R, Bluethmann H, Ryffel B, 1996. Multiple immune abnormalities in tumor necrosis factor and lymphotoxin-α double-deficient mice. Int Immunol; 8: 23-36.

Fangmann J, Schwinzer R, Wonigeit K, 1991. Unusual phenotype of intestinal intraepithelial lymphocytes in the rat: predominance of T cell receptor α/β^+/CD2$^-$ cells and high expression of the RT6 alloantigen. Eur J Immunol; 21: 753-760.

Farstad IN, Halstensen TS, Fausa O, Brandtzaeg P, 1993. Do human Peyer's patches contribute to the intestinal intraepithelial γ/δ T-cell population? Scand J Immunol; 38: 451-458.

Farstad IN, Halstensen TS, Fausa O, Brandtzaeg P, 1994. Heterogeneity of M-cell-associated B and T cells in human Peyer's patches. Immunology; 83: 457-464.

Farstad IN, Halstensen TS, Kvale D, Fausa O, Brandtzaeg P, 1997. Topographic distribution of homing receptors on B and T cells in human gut-associated lymphoid tissue. Am J pathol; 150: 187-199.

Ferguson A, Murray D, 1971. Quantitation of intaepithelial lymphocytes in human jejunum. Gut; 12: 988-994.

Ferguson A, Parrott DMV, 1972. The effect of antigen deprivation on thymus-dependent and thymus-independent lymphocytes in the small intestine of the mouse. Clin Exp Immunol; 12: 477-488.

Ferro LM, Zola H, 1990. Modulation of expression of the antigen identified by FMC-7 upon human B-lymphocyte activation: evidence for differences between activation in vivo and in vitro. Immunology; 69: 373-378.

Festing MFW, May D, Connors TA, Lovell D, Sparrow S, 1978. An athymic nude mutation in the rat. Nature; 274: 365-366.

Fowlkes BJ, Edison L, Mathieson BJ, Chused TM, 1985. Early T lymphocytes. Differentiation *in vivo* of adult intrathymic precursor cells. J Exp Med; 162: 802-822.

Fowlkes BJ, Pardoll DM, 1989. Molecular and cellular events of T cell development. Adv Immunol; 44: 207-264.

Fulop GM, Phillips RA, 1990. The *scid* mutation in mice causes a general defect in DNA repair. Nature; 347: 479-482.

Fujihashi K, Kawabata S, Hiroi T, Yamamoto M, McGhee JR, Nishikawa SI Kiyono H, 1996. Interleukin 2 (IL-2) and interleukin 7 (IL-7) reciprocally induce IL-7 and IL-2 receptors on γδ T-cell receptor-positive intraepithelial lymphocytes. Proc Natl Acad Sci; 93: 3613-3618.

Fujimura Y, Kihara T, Ohtani K, Kamoi R, Kato T, Kozuka K, Miyashima N, Uchida J, 1990. Distribution of microfold cells (M cells) in human follicle-associated epithelium. Gastroenterology Japonica; 25: 130.

Gause WC, Mountz JD, Steinberg AD, 1988. Characterization and differentiation of $CD4^-$, $CD8^-$ thymocytes sorted with the Ly-24 marker. J Immunol; 140: 1-7.

Gek-Kee S, Rajaserkar R, Dessing M, Augustin A, 1994. Homing and *in situ* differentiation of resident pulmonary lymphocytes. Int Immunol; 6: 1287-1295.

Giese T, Davidson WF, 1995. In $CD8^+$ T cell-deficient lpr/lpr mice, $CD4^+B220^+$ and $CD4^+B220^-$ T cells replace $B220^+$ double-negative T cells as the predominant populations in enlarged lymph nodes. J Immunol; 154: 4986-4995.

Godfrey DI, Izon DJ, Tucek CL, Wilson TJ, Boyd RL, 1990. The phenotypic heterogeneity of mouse thymic stromal cells. Immunology, 70: 66-74.

Godfrey DI, Masciantonio M, Tucek CL, Malin MA, Boyd RL, Hugo P, 1992. Thymic shared antigen-1. A novel thymocyte marker discriminating immature from mature thymocyte subsets. J Immunol; 148: 2006-2011.

Godfrey DI, Zlotnik A, 1993. Control points in early T-cell development. Immunology Today; 14: 547-553.

Godfrey DI, Kennedy J, Mombaerts P, Tonegawa S, Zlotnik A, 1994. Onset of TCR-β gene rearrangement and role of TCR-β expression during $CD3^-CD4^-CD8^-$ thymocyte differentiation. Immunology; 152: 4783-4792.

Godfrey DI, Kinder SJ, Silvera P, Baxter AG 1997. Flow cytometric study of T cell development in NOD mice reveals a defeciency in αβ TCR^+ $CD4^-$ $CD8^-$ thymocytes. J Autoimmunity; 10: 279-285.

Good RA, Finstad J, 1967. The phylogenetic development of immune responses and the germinal center system. In. Cottier, Odartchenko, Schindler and Congdon, eds. Germinal centers in immune responses. Springer, Berlin: 4-27.

Goodman T, Lefrancois L, 1988. Expression of the γ–δ T-cell receptor on intestinal $CD8^+$ intraepithelial lymphocytes. Nature; 333: 855-858.

Goodman T, Lefrancois L, 1989. Intraepithelial lymphocytes. Anatomical site, not T cell receptor form, dictates phenotype and function. J Exp Med; 170: 1569-1581.

Grabstein KH, Waldschmidt TJ, Finkelman FD, Hess BW, Alpert AR, Boiani NE, Namen AE, Morrissey PJ, 1993. Inhibition of murine B and T lymphopoiesis *in vivo* by an anti-interleukin 7 monoclonal antibody. J Exp Med; 178: 257-264.

Griebel PJ, Davis WC, Reynolds JD, 1991. Negative signaling by surface IgM on B cells isolated from ileal Peyer's patch follicles of sheep. Eur J Immunol; 21: 2281-2284.

Groettrup M, von Boehmer H, 1993. T cell receproр β chain dimers on immature thymocytes from normal mice. Eur J Immunol; 23: 1393-1396.

Gruss HJ, Dower SK, 1995. Tumor necrosis factor ligand superfamily: involvement in the pathology of malignant lymphomas. Blood; 85: 3378- 3404.

Guidos CJ, Williams CJ, Wu GE, Paige CJ, Danska JS, 1995. Development of $CD4^+$ $CD8^+$ thymocytes in RAG-deficient mice through a T-cell receptor β chain-independent pathway. J Exp Med; 181: 1187-1195.

Guy-Grand D, Griscelli C, Vassalli P, 1978. The mouse gut T lymphocyte, a novel type of T cell. Nature, origin, and traffic in mice in normal and graft-versus-host conditions. J Exp Med; 148: 1661-1677.

Guy-Grand D, Cerf-Bensussan N, Malissen B, Malassis-Seris M, Briottet C, Vassalli P, 1991. Two gut intraepithelial $CD8^+$ lymphocyte populations with different T-cell receptors: a role for the gut epithelium in T-cell differentiation. J Exp Med; 173: 471-481.

Guy-Grand D, Vanden Broecke C, Briottet C, Malassis-Seris M, Selz F, Vassalli P, 1992. Different expression of the recombination activity gene RAG-1 in various populations of thymocytes, peripheral T cells and gut thymus-independent intraepithelial lymphocytes suggests two pathways of T cell receptor rearrangment. Eur J Immunol; 22: 505-510.

Guy-Grand D, Vassalli P, 1993. Gut intraepithelial T lymphocytes. Curr Opin Immunol; 5: 247-252.

Guy-Grand D, Rocha B, Vassalli P, 1993. Origin and development of gut intraepithelial lymphocytes. In Kiyono H, McGhee JR, eds. Mucosal Immunology: Intraepithelial Lymphocytes. New York: Raven Press: 21-31.

Guy-Grand D, Rocha B, Mintz P, Malassis-Seris M, Selz F, Malissen B, Vassalli P, 1994. Different use of T cell receptor transducing modules in two populations of gut intraepithelial lymphocytes are related to distinct pathways of T cell differentiation. J Exp Med; 180: 673-679.

Halstensen TS, Scott H, Brandtzaeg P, 1990. Human $CD8^+$ intraepithelial T lymphocytes are mainly $CD45RA^-$ RB^+ and show increased co-expression of CD45RO in celiac disease. Eur J Immunol; 20: 1825-1830.

Halstensen TS, Brandtzaeg P, 1993. Activated T lymphocytes in the celiac lesion: non-proliferative activation (CD25) of $CD4^+$ α/β cells in the lamina propria but proliferation (Ki-67) of α/β and γ/δ cells in the epithelium. Eur J Immunol; 23: 505-510.

Halstensen TS, Scott H, Fausa O, Brandtzaeg P, 1993. Gluten stimulation of coeliac mucosa *in vitro* induces activation (CD25) of lamina propria $CD4^+$ T cells and macrophages but no crypt-cell hyperplasia. Scand J Immunol; 38: 581-590.

Hamilton SR, Keren DF, Yardley JH, Brown G, 1981. No impairment of local intestinal immune response to Keyhole limpet haemocyanin in the absence of Peyer's patches. Immunology; 42: 431-435.

Harriman GR, Hörnqvist E, Lycke NY, 1992. Antigen-specific and polyclonal $CD4^+$ lamina propria T-cell lines: phenotypic and functional characterization. Immunology; 75: 66-73.

Havran WL, Allison JP, 1988. Developmentally ordered appearance of thymocytes expressing different T-cell antigen receptors. Nature; 335: 443-445.

He HT, Naquet P, Caillol D, Pierres M, 1991. Thy-1 supports adhesion of mouse thymocytes to thymic epithelial cells throutgh a Ca^{2+}-independent mechanism. J Exp Med; 173: 515-518.

Heatley RV, Stark JM, Horsewood P, Bandouvas E, Cole F, Bienenstock J, 1981. The effects of surgical removal of Peyer's patches in the rat on systemic antibody responses to intestinal antigen. Immunology; 44: 543-548.

Held W, Mueller C, MacDonald HR, 1990. Expression of T cell receptor genes in the thymus: localization of transcripts *in situ* and comparison of mature and immature subsets. Eur J Immunol; 20: 2133-2136.

Hemler ME, Brenner MB, McLean JM, Strominger JL, 1984. Antigenic stimulation regulates the level of expression of interleukin 2 receptor on human T cells. Proc. Natl. Acad Sci USA; 81: 2172-2175.

Hendrickson EA, Qin XQ, Bump EA, Schatz DG, 1991. Oettinger M, Weaver DT. A link between double-strand break-related repair and V(D)J recombination: The *scid* mutation. Proc Natl Acad Sci; 88: 4061-4065.

Herzenberg LA, Kantor AB, Herzenberg LA, 1992. Layered evolution in the immune system. A model for the ontogeny and development of multiple lymphocyte lineages. Ann N Y Acad Sci; 651: 1-9.

Hough MR, Takei F, Humphries RK, Kay R, 1994. Defective development of thymocytes overexpressing the costimulatory molecule, heat-stable antigen. J Exp Med; 179: 177-184.

Hsu SM, Raine L, Fanger H, 1981. Use of avidin-biotin-peroxidase complex (ABC) in immunoperoxidase techniques: a comparison between ABC and unlabelled antibody (PAP) procedures. J Histochem Cytochem; 29: 577-580.

Huang L, Crispe IN, 1992. Distinctive selection mechanisms govern the T cell receptor repertoire of peripheral $CD4^-$ $CD8^-$ $\alpha\beta$ T cells. J Exp Med; 176: 699-706.

Huang L, Sye K, Crispe IN, 1994. Proliferation and apoptosis of $B220^+$ $CD4^-$ $CD8^-$ TCR $\alpha\beta^{intermediate}$ T cells in the liver of normal adult mice: implication for lpr pathogenesis. Int Immunol; 6: 533-540.

Hueber AO, Pierres M, He HT, 1992. Sulfated glycans directly interact with mouse Thy-1 and negatively regulate Thy-1-mediated adhesion of thymocytes to thymic epithelial cells. J Immunol; 148: 3692-3699.

Hugo P, Waanders GA, Scollay R, Shortman K, Boyd RL, 1990. Ontogeny of a novel $CD4^+$ $CD8^-$ $CD3^-$ thymocyte subpopulation: a comparison with $CD4^-$ $CD8^+$ $CD3^-$ thymocytes. Int Immunol; 2: 209-218.

Hume DA, Robinson AP, MacPherson GG, Gordon S, 1983. The mononuclear phagocyte system of the mouse defined by immunohistochemical localization of antigen F4/80. Relationship between macrophages, Langerhans cells, reticular cells, and dendritic cells in lymphoid and hematopoietic organs. J Exp Med; 158: 1522-1536.

Hume DA, Perry VH, Gordon S, 1984. The mononuclear phagocyte system of the mouse defined by immunohistochemical localisation of antigen F4/80 macrophages associated with epithelia. Anat Rec; 210: 503-512.

Husband AJ, Gowans JL, 1978. The origin and antigen-dependent distribution of IgA-containing cells in the intestine. J Exp Med; 148: 1146-1160.

Hyman R, Lesley J, Schulte R, Trotter J, 1986. Progenitor cells in the thymus: most thymus-homing progenitor cells in the adult mouse thymus bear Pgp-1 glycoprotein but not interleukin-2 receptor on their cell surface. Cell Immunol; 101:320-327.

Iiai T, Watanabe H, Seki S, Sugiura K, Hirokawa K, Utsuyama M, Takahashi-Iwanaga H, Iwanaga T, Ohteki T, Abo T, 1992. Ontogeny and development of extrathymic T cells in mouse liver. Immunology; 77: 556-563.

James SP, Zeitz M, 1994: Human gastrointestinal mucosal T cells. In: Ogra PL, Lamm ME, McGhee JR, Mestecky J, Strober W, Bienenstock J, eds. Handbook of Mucosal Immunology. San Diego: Academic Press, Inc: 275-85.

Jarry A, Cerf-Bensussan N, Brousse N, Selz F, Guy-Grand D, 1990. Subsets of $CD3^+$ (T cell receptor α/β or γ/δ) and $CD3^-$ lymphocytes isolated from normal human gut epithelium display phenotypical features different from their counterparts in peripheral blood. Eur J Immunol; 20: 1097-1103.

Jenkinson EJ, Kingston R, Owen JJT, 1987. Importance of IL-2 receptors in intra-thymic generation of cells expressing T-cell receptors. Nature; 329: 160-162.

Joel DD, Hess MW, Cottier H, 1971. Thymic origin of lymphocytes in developing Peyer's patches ofnewborn mice. Nature New Biology; 231: 24-25.

Kagnoff MF, 1987. Immunology of the digestive system. In: Johnson LR, Christensen J, Jackson MJ, Jacobson ED, Walsh JH, eds. Physiology of the Gastrointestinal tract. 2nd ed. New York. Raven Press: 1699-1728.

Kampinga J, Berges S, Boyd RL, Brekelmans P, Colic M, Van Ewijk W, Kendall MD, Ladyman H, Nieuwenhuis P, Ritter MA, Schuurman HJ, Tournefier A, 1989. Thymic epithelial antibodies: Immunohistological analysis and introduction of nomenclature. Thymus; 13:165-173.

Kanamori Y, Ishimaru K, Nanno M, Maki K, Ikuta K, Nariucki H, 1996: Identification of novel lymphoid tissues in murine intestinal mucosa where clusters of c-Kit^+ IL7-R^+ Thy^+ lympho-hemopoietic progenitors develop. J Exp Med; 184: 1449-1459.

Kappler JW, Skidmore B, White J, Marrack P, 1981. Antigen-inducible, H-2-restricted, interleukin-2-producing T cell hybridomas, lack of independent antigen and H-2 recognition. J Exp Med; 153: 1198-1214.

Kappler JW, Roehm N, Marrack P, 1987. T cell tolerance by clonal elimination in the thymus. Cell; 49: 273-280.

Kelly KA, Scollay R, 1990. Analysis of recent thymic emigrants with subset- and maturity-related markers. Int Immunol; 2: 419-425.

Kelsall BL, Strober W, 1996. Distinct populations of dendritic cells are present in the subepihelial dome and T cell regions of the murine Peyer's patch. J Exp Med; 183: 237-247.

Kenai H, Matsuzaki G, Nakamura T, Yoshikai Y, Nomoto K, 1993. Thymus-derived cytokine(s) including interleukin-7 induce increase of T cell receptor α/β^+ $CD4^-CD8^-$ T cells which are extrathymically differentiated in athymic nude mice. Eur J Immunol; 23: 1818-1825.

Kenai H, Matsuzaki G, Lin T, Yoshida H, Nomoto K, 1995. Precursor cells to CD3-intermediate ($CD3^{int}$) liver mononuclear cells in the adult liver: further evidence for the extrathymic development of $CD3^{int}$ liver mononuclear cells. Eur J Immunol; 25: 3365-3369.

Keren DF, 1992. Structure and function of the immunologic system of the gastrointestinal tract. In: Ming SC, Goldman H, eds. Pathology of the gastrointestinal tract. Philadelphia: Saunders: 69-80.

Keren DF, Holt PS, Collins HH, Gemski P, Formal SB, 1978. The role of Peyer's patches in the local immune response of rabbit ileum to live bacteria. J Immunol; 120: 1892-1896.

Kimura M, Hanawa H, Watanabe H, Ogawa M, Abo T, 1995. Synchronous expansion of intermediate TCR cells in the liver and uterus during pregnancy. Cell Immunol; 162: 16-25.

Kishimoto H, Surh CD, Sprent J, 1995. Upregulation of surface markers on dying thymocytes. J Exp Med; 181: 649-655.

Kisielow P, Teh HS, Blüthmann H, von Boehmer H, 1988. Positive selection of antigen-specific T cells in thymus by restricting MHC molecules. Nature; 335 : 730-733.

Kiyono H, Cooper MD, Kearney JF, Mosteller LM, Michalek SM, Koopman WJ, McGhee JR, 1984. Isotype specificity of helper T cell clones. Peyer's patch Th cells preferentially collaborate with mature IgA B cells for IgA responses. J Exp Med; 159: 798-811.

Klaus GG, Humphrey JH, Kunkl A, Dongworth DW, 1980. The follicular dendritic cell: Its role in antigen presentation in the generation of immunological memory. Immunolog Rev; 53: 3-28.

Knapp W, Dörken B, Gilks WR, Rieber EP, Schmidt RE, Stein H, von dem Borne AEGK, 1989. Leucocyte typing IV. White cell differentiation antigens. Oxford: Oxford University Press.

Kondo M, Takeshita T, Higuchi M, Nakamura M, Sudo T, Nishikawa SI, Sugamura K, 1994. Functional participation of the IL-2 receptor γ chain in IL-7 receptor complexes. Science; 263; 1453-1454.

Koni PA, Sacca R, Lawton P, Browning JL, Ruddle NH, Flavell RA, 1997. Distinct roles in lymphoid organogenesis for lymphotoxins alpha and beta revealed in lymphotoxin beta-deficient mice. Immunity; 6: 491-500.

Koo GC, Dumont FJ, Tutt M, Hackett J, Kumar V, 1986. The NK-1.1(-) mouse: a model to study differentiation of murine NK cells. J Immunol; 137: 3742-3747.

Korner H, Cook M, Riminton DS, Lemckert FA, Hoek RM, Ledermann B, Kontgen F, St Groth BF, Sedgwick JD, 1997. Distinct roles for lymphotoxin-α and tumor necrosis factor in organogenesis and spatial organization of lymphoid tissue. Eur J Immunol; 27: 2600-2609.

Kosco MH, Tew JG, Szakal AK, 1986. Antigen phenotyping of isolated and in *situ* rodent follicular dendritic cells (FDC) with emphasis on the ultrastructural demonstration of Ia antigens. Anatomical Record; 215: 201-213.

Kosugi A, Saitoh SI, Narumiya S, Miyake K, Hamaoka T, 1994. Activation-induced expression of thymic shared antigen-1 on T lymphocytes and its inhibitory role for TCR-mediated IL-2 production. Int Immunol; 6: 1967-1976.

Kraehenbuhl JP, Neutra MR, 1992. Molecular and cellular basis of immune protection of mucosal surfaces. Physiol Rev; 72: 853-879.

Kroczek RA, Gunter KC, Seligmann B, Shevach EM, 1986. Induction of T cell activation by monoclonal anti-Thy-1 antibodies. J Immunol; 136: 4379-4384.

Kronenberg M, Siu G, Hood LE, Shastri N, 1986. The molecular genetics of the T-cell antigen receptor and T-cell antigen recognition. Ann Rev Immunol; 4: 529-591

Kubo RT, Born W, Kappler JW, Marrack P, Pigeon M, 1989. Characterization of a monoclonal antibody which detects all murine α/β T cell receptors. J Immunol; 142: 2736-2742.

Kundig TM, Schorle H, Bachmann MF, Hengartner H, Zinkernagel RM, Horak I, 1993. Immune responses in interleukin-2-deficient mice. Science; 262: 1059-1061.

Kung JT, 1988. Impaired clonal expansion in athymic nude $CD8^{+}CD4^{-}$ T cells. J Immunol; 140: 3727-3735.

Kusumi A, Abo T, Masuda T, Sugiura K, Seki S, Ohteki T, Okuyama R, Kumagai K, 1992. Lymphotoxin activates hepatic T cells and simultaneously induces profound thymic atrophy. Immunology; 77: 177-184.

Latthe M, Terry L, MacDonald TT, 1994: High frequency of CD8αα homodimer-bearing T cells in human fetal intestine. Eur J Immunol; 24: 1703-1705.

Lawetzky A; Hunig T, 1988. Analysis of CD3 and antigen receptor expression on T cell subpopulations of aged athymic mice. Eur J Immunol; 18: 409-416.

Ledbetter JA, Herzenberg LA, 1979. Xenogeneic monoclonal antibodies to mouse lymphoid differentiation antigens. Immunol Rev; 47: 63-90.

Lefrancois L, 1987. Carbohydrate differentiation antigens of murine T cells: expression on intestinal lymphocytes and intestinal epithelium. J Immunol; 138: 3375-3384.

Lefrancois L, 1991. Phenotypic complexity of intraepithelial lymphocytes of the small intestine. J Immunol; 147: 1746-1751.

Lefrancois L, Olson S, 1994. A novel pathway of thymus-directed T lymphocyte maturation. J Immunol; 153: 987-995.

Lefrancois L, Puddington L, 1995. Extrathymic intestinal T-cell development: virtual reality? Immunology Today; 16: 16-21.

Lefrancois L, Puddington L, 1996. The role of the thymus in intestinal intraepithelial T-cell development. Ann N Y Acad Sci; 778: 36-46.

Le Hir M, Bluethmann H, Kosco-Vilbois MH, Muller M, di Padova F, Moore M, Ryffel B, Eugster HP, 1996. Differentiation of follicular dendritic cells and full antibody responses require tumor necrosis factor receptor-1 signalling. J Exp Med; 183: 2367-2372.

Lenardo MJ, 1991. Interleukin-2 programs mouse αβ T lymphocytes for apoptosis. Nature; 353: 858-861.

Leo O, Foo M, Sachs DH, Samelson LE, Bluestone JA, 1987. Identification of a monoclonal antibody specific for a murine T3 polypeptide. Proc Natl Acad Sci USA; 84: 1374-1378.

Lewis S, Gellert M, 1989. The mechanism of antigen receptor gene assembly. Cell; 59: 585-588.

Lewis M, Tartaglia LA, Lee A, Bennett GL, Rice GC, Wong GHW, Chen EY, Goeddel DV, 1991. Cloning and expression of cDNAs for two distinct murine tumor necrosis factor receptors demonstrate one receptor is species specific. Proc Natl Acad Sci USA; 88: 2830-2834.

Lieber MR, Hesse JE, Lewis S, Bosma GC, Rosenberg N, Mizuuchi K, Bosma MJ, Gellert M, 1988. The defect in murine severe combined immune deficiency: joining of signal sequences but not coding segments in V(D)J recombination. Cell; 55: 7-16.

Lin T, Matsuzaki G, Kenai H, Nakamura T, Nomoto K, 1993. Thymus influences the development of extrathymically derived intestinal intraepithelial lymphocytes. Eur J Immunol; 23: 1968-1974.

Lin T, Matsuzaki G, Yoshida H, Kobayashi N, Kenai H, Omoto K, Nomoto K, 1994a. $CD3^{-}CD8^{+}$ intestinal intraepithelial lymphocytes (IEL) and the extrathymic development of IEL. Eur J Immunol; 24: 1080-1087.

Lin T, Matsuzaki G, Kenai H, Nomoto K, 1994b. Progenies of fetal thymocytes are the major source of $CD4^{-}CD8^{+}$ $\alpha\alpha$ intestinal intraepithelial lymphocytes early in ontogeny. Eur J Immunol; 24: 1785-1791.

Lin WC, Desiderio S, 1995. V(D)J recombination and the cell cycle. Immunology Today; 16: 279-289.

Loetscher H, Pan YCE, Lahm HW, Gentz R, Brockhaus M, Tabuchi H, Lesslauer W, 1990. Molecular cloning and expression of the human 55 kd tumor necrosis factor receptor. Cell; 61: 351-359.

Lojda Z, Gossrau R, Schiebler TH, 1979. Enzyme Histochemistry. Berlin Heidelberg New York: Springer-Verlag.

Lundqvist C, Baranov V, Hammarström S, Athlin L, Hammarström ML, 1995. Intra-epithelial lymphocytes. Evidence for regional specialization and extrathymic T cell maturation in the human gut epithelium. Int Immunol; 7: 1473-1487.

Luqman M, Johnson P, Trowbridge I, Bottomly K, 1991. Differential expression of the alternatively spliced exons of murine CD45 in T_h1 and T_h2 cell clones. Eur J Immunol; 21: 17-22.

Lynch S, Kelleher D, McManus R, O'Farrelly C, 1995. RAG-1 and RAG-2 expression in human intestinal epithelium: evidence of extrathymic T cell differentiation. Eur J Immunol; 25: 1143-1147.

Lyscom N, Brueton MJ, 1982. Intraepithelial, lamina propria and Peyer's patch lymphocytes of the rat small intestine: isolation and characterization in terms of immunoglobulin markers and receptors for monoclonal antibodies. Immunology; 45: 775-783.

MacDonald HR, Lees RK, Sordat B, Zaech P, Maryanski JL, Bron C, 1981. Age-associated increase in expression of the T cell surface markers Thy-1, Lyt-1, and Lyt-2 in congenitally athymic (nu/nu) mice: analysis by flow microfluorometry. J Immunol; 126: 865-870.

MacDonald HR, Blanc C, Lees RK, Sordat B, 1986. Abnormal distribution of T cell subsets in athymic mice. J Immunol; 136: 4337-4339.

MacDonald HR, Lees RK, Bron C, Sordat B, Miescher G, 1987. T cell antigen receptor expression in athymic (nu/nu) mice. J Exp Med; 166: 195-209.

MacDonald HR, Budd RC, Howe RC, 1988. A $CD3^-$ subset of $CD4^-8^+$ thymocytes: a rapidly cycling intermediate in the generation of $CD4^+8^+$ cells. Eur J Immunol; 18: 519-523.

MacDonald TT, Spencer J, 1994a. Ontogeny of the gut-associated lymphoid system in man. Acta Peadiatr Suppl; 83: 3-5.

MacDonald TT, Spencer J, 1994b. Gut-associated lymphoid tissue. In: Ogra PL, Lamm ME, McGhee JR, Mestecky J, Strober W, Bienenstock J, eds. Handbook of Mucosal Immunology. San Diego: Academic Press, Inc: 415-424.

Machado CS, Rodrigues MA, Maffei HV, 1994. Gut intraepithelial lymphocyte counts in neonates, infants and children. Acta Paediatr; 83: 1264-1267.

Mackay F, Majeau GR, Lawton P, Hochman PS, Browning JL, 1997. Lymphotoxin but not tumor necrosis factor functions to maintain splenic architecture and humoral responsiveness in adult mice. Eur J Immunol; 27: 2033-2042.

MacNeil I, Kennedy J, Godfrey DI, Jenkins NA, Masciantonio M, Mineo C, Gilbert DJ, Copeland NG, Boyd RL, Zlotnik A, 1993. Isolation of a cDNA encoding thymic shared antigen-1. J Immunol; 151: 6913-6923.

Madrigal L, Byrne B, McManus R, Lynch S, Kelleher D, O'Donoghue DP, Feighery C, O'Farrelly C, 1997. Human small intestinal epithelial cells produce two different interleukin-7 (IL-7) mRNA transcripts and secrete IL-7 protein. Immunol Cell Biol; 75: A48.

Makino Y, Yamagata N, Sasho T, Adachi Y, Kanno R, Koseki H, Kanno M, Taniguchi M, 1993. Extrathymic development of Vα14-positive T cells. J Exp Med; 177: 1399-1408.

Malin M, Gill J, Sutherland J, Rodewald HR, Gershwin M, Boyd R, 1998. Ontogenesis of the thymic microenvironment- is there a primordial epithelium precursor? Australian Society for Immunology 28th Annual Conference Melbourne Australia; Poster 3-11 (abstract).

Malynn BA, Blackwell TK, Fulop GM, Rathbun GA, Furley AJW, Ferrier P, Heinke LB, phillips RA, Yancopoulos GD, Alt FW, 1988. The scid defect affects the final step of the immunoglobulin VDJ recombinase mechanism. cell; 54: 453-460.

Marsh MN, 1975a. Studies of intestinal lymphoid tissue. Aspects of proliferation and migration of epithelial lymphocytes in the small intestine of mice. Gut; 16: 674-682.

Marsh MN, 1975b. Studies of intestinal lymphoid tissue. Electron microscopic evidence of 'blast transformation' in epithelial lymphocytes of mouse small intestinal mucosa. Gut; 16: 665-674.

Mason DW, Dallman M, Barclay AN, 1981. Graft-versus-host disease induces expression of Ia antigen in rat epidermal cells and gut epithelium. Nature; 293: 150-151.

Masuda T, Ohteki T, Abo T, Seki S, Nose M, Nagura H, Kumagai K, 1991. Expansion of the population of double negative $CD4^-8^-$ Tαβ-cells in the liver is a common feature of autoimmune mice. J Immunol; 147: 2907-2912.

Mathieson BJ, Sharrow SO, Rosenberg Y, Hämmerling U, 1981. Lyt 1^+ 23^- cells appear in the thymus before Lyt 123^+ cells. Nature; 289: 179-181.

Matsumoto M, Fu YX, Molina H, Chaplin DD, 1997. Lymphotoxin-alpha-deficient and TNF receptor-I-deficient mice define developmental and functional characteristics of germinal centers. Immunol Rev; 156: 137-144.

Mayer L, Shlien R, 1987. Evidence for function of Ia molecules on gut epithelial cells in man. J Exp Med; 166: 1471-1483.

Mayer L, Yio XY, Campbell N, 1997. Classical and non-classical MHC determinants in the gut: regulation of mucosal immune responses. Immunol Cell Biol; 75: A3 (abstract).

Mayrhofer G, 1984. Physiology of the intestinal immune system. In: Newby TJ, Stokes CR, eds. Local immune responses of the gut. Boca Raton: CRC Press: 1-96.

Mayrhofer G, 1994. Epithelial disposition of antigen. In: Goldie R, ed. The handbook of immunopharmacology. Londom,: Academic Press: 19-69.

Mayrhofer G, 1997: Peyer's patch organogenesis-cytokines rule, OK? Gut; 41: 707-709.

Mayrhofer G, Bazin H, Gowans JL, 1976. Nature of cells binding anti-IgE in rats immunized with Nippostrongylus brasiliensis: IgE synthesis in regional nodes and concentration in mucosal mast cells. Eur J Immunol; 6: 537-545.

Mayrhofer G, Pugh CW, Barclay AN, 1983. The distribution, ontogeny and origin in the rat of Ia-positive cells with dendritic morphology and of Ia antigen in epithelia, with special reference to the intestine. Eur J Immunol; 13: 112-122.

Mayrhofer G, Schon-Hegrad MA, 1983. Ia antigens in rat kidney, with special reference to their expression in tubular epithelium. J Exp Med; 157: 2097-2109.

Mayrhofer G, Whately RJ, 1983. Granular intraepithelial lymphocytes of the rat small intestine. Isolation, presence in T lymphocyte-deficient rats and bone marrow origin. Int Arch Allergy Appl Immunol; 71: 317-327.

Mayrhofer G, Pitts R, 1986. A comparison of some properties of mast cells and other granulated cells. In Befus AD, Bienenstock J, Denburg JA, eds. Mast cells differentiation and heterogeneity. New York: Raven Press: 141-157.

Mayrhofer G, Gadd SJ, Spargo LDJ, Ashman LK, 1987. Specificity of a mouse monoclonal antibody raised against acute myeloid leukaemia cells for mast cells in human mucosal and connective tissues. Immunol Cell Biol; 65: 241-250.

Mayrhofer G, Spargo LDJ, 1989. Subcellular distribution of class II major histocompatibility antigens in enterocytes of the human and rat small intestine. Immunol Cell Biol; 67: 251-260.

Mayrhofer M, Brooks A, 1995: Lymphopoiesis in lymphocyte-filled villi in the small intestine of the rat: Clin Immunol Immunopathol; 76: S55.

McPhee D, Pye J, Shortman k. The differentiation of T-lymphocytes, 1979. Evidence for intrathymic death of most thymocytes. Thymus; 1: 151-162.

Meader RD, Landers DF, 1967. Electron and light microscopic observations on relationships between lymphocytes and intestinal epithelium. Am J Anat; 121: 763-774.

Mega J, Bruce MG, Beagley KW, McGhee JR, Taguchi T, Pitts AM, McGhee ML, Bucy RP, Eldridge JH, Mestecky J, *et al.,* 1991. Regulation of mucosal responses by $CD4^+$ T lymphocytes: effects of anti-L3T treatment on the gastrointestinal immune system. Int Immunol; 3: 793-805.

Metlay JP, Witmer-Pack MD, Agger R, Crowley MT, Lawless D, Steinman RM, 1990. The distinct leukocyte integrins of mouse spleen dendritic cells as identified with new hamster monoclonal antibodies. J Exp Med; 171: 1753-1771.

Miller BA, Antognetti G, Springer TA, 1985. Identification of cell surface antigens present on murine hematopoietic stem cells. J Immunol; 134: 3286-3290.

Mombaerts P, Iacomini J, Johnson RS, Herrup K, Tonegawa S, Papaioannou VE, 1992. RAG-1-dificient mice have no mature B and T lymphocytes. Cell; 68: 869-877.

Moolenbeek C, Ruitenberg EJ, 1981. The 'Swiss roll': a simple technique for histological studies of the rodent intestine. Laboratory Animals; 15: 57-59.

Moore M, Owen JJT, 1967. Experimental studies on the development of the thymus. J Exp Med; 126: 715-726.

Morson BC, Dawson IMP, 1979. Gastrointestinal Pathology. 2nd ed., Oxford: Blackwell Scientific Publications: 211-233.

Mosley RL, Styre D, Klein JR, 1990. Differentiation and functional maturation of bone marrow-derived intestinal epithelial T cells expressing membrane T cell receptor in athymic radiation chimeras. J Immunol; 145: 1369-1375.

Mosley RL, Whetsell M, Klein JR, 1991. Proliferative properties of murine intestinal intraepithelial lymphocytes (IEL): IEL expressing TCR αβ or TCR γδ are largely unresponsive to proliferative signals mediated via conventional stimulation of the CD3-TCR complex. Int Immunol; 3: 563-569.

Mosley RL, Klein JR, 1992. Peripheral engraftment of fetal intestine into athymic mice sponsors T cell development: direct evidence for thymopoietic function of murine small intestine. J Exp Med; 176: 1365-1373.

Muegge K, Vila MP, Durum SK, 1993. Interleukin-7: A cofactor for V(D)J rearrangement of the T cell receptor β gene. Science; 261: 93-95.

Muller M, Eugster HP, Le Hir M, Shakhov A, Di-Padova F, Maurer C, Quesniaux VF, Ryffel B, 1996. Correction or transfer of immumodeficiency due to TNF-LT alpha deletion by bone marrow transplantation. Mol Med; 2: 247-255.

Murosaki S, Yoshikai Y, Ishida A, Nakamura T, Matsuzaki G, Takimoto H, Yuuki H, Nomoto K, 1991. Failure of T cell receptor V beta negative selection in murine intestinal intra-epithelial lymphocytes. Int Immunol; 3: 1005-1013.

Murphy WJ, Durum SK, Anver MR, Ferris DK, McVicar DW, O'Shea JJ, Ruscetti SK, Smith MR, Young HA, Longo DL, 1994. Induction of T cell differentiation and lymphomagenesis in the thymus of mice with severe combined immunodeficiency (SCID). J Immunol; 153: 1004-1014.

Nagura H, Sumi Y, 1987. Immunocytochemical studies of the vascular endothelial cells in human Peyer's patches and solitary lymphoid follicles. Adv Exp Med Biol; 216: 279-286.

Neumann B, Luz A, Pfeffer K, Holzmann B, 1996. Defective Peyer's patch organogenesis in mice lacking the 55-kD receptor for tumor necrosis factor. J Exp Med; 184: 259-264.

Nikolic-Zugic J, 1991. Phenotypic and functional stages in the intrathymic development of αβ T cells. Immunology Today; 12: 65-70.

Nikolic Zugic J, Moore MW, 1989. T cell receptor expression on immature thymocytes with *in vivo* and *in vitro* precursor potential. Eur J Immunol; 19: 1957-1960.

Noda S, Kosugi A, Saitoh SI, Narumiya S, Hamaoka T, 1996. Protection from anti-TCR/CD3-induced apoptosis in immature thymocytes by a signal through thymic shared antigen-1/stem cell antigen-2. J Exp Med; 183: 2355-2360.

Noguchi M, Nakamura Y, Russell SM, Ziegler SF, Tsang M, Cao X, Leonard WJ, 1993. Interleukin-2 receptor γ chain: A functional component of the interleukin-7 receptor. Science; 262: 1877-1880.

Oettinger MA, Schatz DG, Gorka C, Baltimore D, 1990. Rag-1 and Rag-2, adjacent genes that synergistically activate V(D)J recombination. Science; 248: 1517-1523.

Ohteki T, Seki S, Abo T, Kumagai K, 1990. Liver is a possible site for the proliferation of abnormal $CD3^+$ 4^- 8^- double-negative lymphocytes in autoimmune MRL-lpr/lpr mice. J Exp Med; 172: 7-12.

Ohteki T, Abo T, Seki S, Kobata T, Yagita H, Okumura K, Kumagai K, 1991. Predominant appearance of γδ T lymphocytes in the liver of mice after birth. Eur J Immunol; 21: 1733-1740.

Ohteki T, Okuyama R, Seki S, Abo T, Sugiura K, Kusumi A, Ohmori T, Watanabe H, Kumagai K, 1992. Age-dependent increase of extrathymic T cells in the liver and their appearance in the periphery of older mice. J Immunol; 149: 1562-1570.

Ohtsuka K, Iiai T, Watanabe H, Tanaka T, Miyasaka M, Sato K, Asakura H, Abo T, 1994. Similarities and differences between extrathymic T cells residing in mouse liver and intestine. Cell Immunol; 153: 52-66.

Okuyama R, Abo T, Seki S, Ohteki T, Sugiura K, Kusumi A, Kumagai K, 1992. Estrogen administration activates extrathymic T cell differentiation in the liver. J Exp Med; 175: 661-669.

Orlic D, Lev R, 1977. An electron microscopic study of intraepithelial lymphocytes in human fetal small intestine. Lab Invest; 37: 554-561.

Owen RL, 1977. Sequential uptake of horseradish peroxidase by lymphoid follicle epithelium of Peyer's patches in the normal unobstructed mouse intestine: an ultrastructural study. Gastroenterology; 72: 440-451.

Owen RL, Jones AL, 1974. Epithelial cell specialization within human Peyer's patches: an ultrastructural study of intestinal lymphoid follicles. Gastroenterology; 66: 189-203.

Owen RL, Apple RT, Bhalla DK, 1986. Morphometric and cytochemical analysis of lysosomes in rat Peyer's patch follicle epithelium: their reduction in volume fraction and

acid phosphatase content in M cells compared to adjacent enterocytes. Anat Rec; 216: 521-527.

Palacios R, von Boehmer H, 1986. Requirements for growth of immature thymocytes from fetal and adult mice *in vitro*. Eur J Immunol; 16: 12-19.

Palacios R, Kiefer M, Brockhaus M, Karjalainen K, Dembic Z, Kisielow P, von Boehmer H, 1987. Molecular, cellular, and functional properties of bone marrow T lymphocyte progenitor clones. J Exp Med; 166: 12-32.

Palmer DB, Hayday A, Owen MJ, 1993. Is TCR β expression an essential event in early thymocyte development? Immunology Today; 14: 460-462.

Pardoll DM, Fowlkes BJ, Lew AM, Maloy WL, Weston MA, Bluestone JA, Schwartz RH, Coligan JE, Kruisbeek AM, 1988. Thymus-dependent and thymus-independent developmental pathways for peripheral T cell receptor-γδ-bearing lymphocytes. J Immunol; 140: 4091-4096.

Pasparakis M, Alexopoulou L, Episkopou V, Kollias G, 1996. Immune and inflammatory responses in TNFα-deficient mice: a critical requirement for TNFα in the formation of Primary B cell follicles, follicular dendritic cell networks and germinal centers, and in the maturation of the humoral immune response. J Exp Med; 184: 1397-1411.

Pasparakis M, Alexopoulou L, Grell M, Pfizenmaier K, Bluethmann H, Kollias G, 1997. Peyer's patch organogenesis is intact yet formation of B lymphocyte follicles is defective in peripheral lymphoid organs of mice deficient for tumor necrosis factor and its 55-kDa receptor. Proc Natl Acad Sci USA; 94: 6319-6323.

Pavli P, Woodhams CE, Doe WF, Hume DA, 1990. Isolation and characterization of antigen-presenting dendritic cells from the mouse intestinal lamina propria. Immunology, 70: 40-47.

Pearse M, Wu L, Egerton M, Wilson A, Shortman K, Scollay R, 1989. A murine early thymocyte developmental sequence is marked by transient expression of the interleukin 2 receptor. Proc Natl Acad Sci; 86: 1614-1618.

Pentilla IA, Gibson CE, Leong AS-Y, Zola H, Labrooy JT, 1995. Cell surface determinants on typhoid-specific B cells isolated from peripheral blood after oral Ty21a typhoid vaccination in humans. Immunol Cell Biol; 73: 198-204.

Perera DR, Weinstein WM, Rubin CE, 1975. Small intestinal biopsy. Human Pathology; 6: 157-217.

Peschon JJ, Morrissey PJ, Grabstein KH, Ramsdell FJ, Maraskovsky E, Gliniak BC, Park LS, Ziegler SF, Williams DE, Ware CB, Meyer JD, Davison BL, 1994. Early lymphocyte expansion is severely impaired in interleukin 7 receptor-deficient mice. J Exp Med; 180: 1955-1960.

Petrie HT, Hugo P, Scollay R, Shortman K, 1990. Lineage relationships and developmental kinetics of immature thymocytes: CD3, CD4, and CD8 acquisition *in vivo* and *in vitro*. J Exp Med; 172: 1583-1588.

Petruch UR, Horny HP, Kaiserling E, 1992. Frequent expression of haemopoietic and non-haemopoietic antigens by neoplastic plasma cells: an immunohistochemical study using formalin-fixed, paraffin-embedded tissue. Histopathology; 20: 35-40.

Pierce NF, Gowans JL, 1975. Cellular kinetics of the intestinal immune response to cholera toxoid in rats. J Exp Med; 142: 1550-1563.

Pilarski LM, Gillitzer R, Zola H, Shortman K, Scollay R, 1989. Definition of the thymic generative lineage by selective expression of high molecular weight isoforms of CD45 (T200). Eur J Immunol; 19: 589-597.

Pilarski LM, Jensen GS, 1992. Monoclonal circulating B cells in multiple myeloma. A continuously differentiating, possibly invasive, population as defined by expression of CD45 isoforms and adhesion molecules. Hematol Clin Nth Am; 6: 297-322.

Poskitt DC, Duffey K, Barnett J, Kimpton WG, Muller HK, 1984. The gut-associated lymphoid system of two species of Australian marsupial mice, Antechinus swainsonii and Antechinus stuartii. Distribution, frequency and structure of Peyer's patches and lymphoid follicles in the small and large intestine. Aust J Exp Biol Med Sci; 62: 81-88.

Poussier P, Edouard P, Lee C, Binnie M, Julius M, 1992. Thymus-independent development and negative selection of T cells expressing T cell receptor α/β in the intestinal epithelium: evidence for distinct circulation patterns of gut- and thymus-derived T lymphocytes. J Exp Med; 176: 187-199.

poussier P, Julius M, 1994. Thymus independent T cell development and selection in the intestinal epithelium. Annu Rev Immunol; 12: 521-553.

Preffer FI, Kim CW, Fischer KH, Sabga EM, Kradin RL, Colvin RB, 1989. Identification of pre-T cells in human peripheral blood. Extrathymic differentiation of $CD7^+CD3^-$ cells into $CD3^+$ γ/δ^+ or α/β^+ T cells. J Exp Med; 170: 177-190.

Price AB, 1985. Small intestinal biopsy In: Booth CC, Neale G, eds. Disorders of the small intestine. Oxford: Blackwell Scientific Publications: 12-21.

Ramirez F, McKnight AJ, Silva A, Mason D, 1992. Glucocorticoids induce the expression of $CD8\alpha$ chains on concanavalin A-activated rat $CD4^+$ T cells: induction is inhibited by rat recombinant interleukin 4. J Exp Med; 176: 1551-1559.

Randle ES, Waanders GA, Masciantonio M, Godfrey DI, Boyd RL, 1993. A lymphostromal molecule, thymic shared Ag-1, regulates early thymocyte development in fetal thymus organ culture. J Immunol; 151: 6027-6035.

Raulet DH, 1985. Expression and function of interleukin-2 receptors on immature thymocytes. Nature; 314: 101-103.

Reimann J, Rudolphi A, 1995. Co-expression of $CD8\alpha$ in $CD4^+$ T cell receptor $\alpha\beta^+$ T cells migrating into the murine small intestine epithelial layer. Eur J Immunol; 25: 1580-1588.

Rennert PD, Browning JL, Mebius R, Mackay F, Hochman PS, 1996. Surface lymphotoxin α/β complex is required for the development of peripheral lymphoid organs. J Exp Med; 184: 1999-2006.

Reynolds JD, Morris B, 1983. The evolution and involution of Peyer's patches in fetal and postnatal sheep. Eur J Immunol; 13: 627-635.

Reynolds JD, Morris B, 1984. The effect of antigen on the development of Peyer's patches in sheep. Eur J Immunol; 14: 1-6.

Reynolds JD, Kennedy L, Peppard J, Pabst R., 1991. Ileal Peyer's patch emigrants are predominantly B cells and travel to all lymphoid tissues in sheep. Eur J Immunol; 21: 283-289.

Ritter MA, Boyd RL, 1993. Development in the thymus: it takes two to tango. Immunology Today; 14: 462-469.

Robijn RJ, Bloemendal H, Jainandunsing S, Wiegman LJJM, Vanberge-Henegouwen GP, Logtenberg T, Koningsberger JC, 1993. Phenotypic and molecular characterization of human monoclonal TCRγ/δ T-cell lines from jejunum and colon of healthy individuals. Scan J Immunol; 38: 247-253.

Rocha B, 1990. Characterization of Vβ-bearing cells in athymic (nu/nu) mice suggests an extrathymic pathway for T cell differentiation. Eur J Immunol; 20: 919-925.

Rocha B, Vassalli P, Guy-Grand D, 1991. The Vβ repertoire of mouse gut homodimeric α $CD8^+$ intraepithelial T cell receptor α/β^+ lymphocytes reveals a major extrathymic pathway of T cell differentiation. J Exp Med; 173: 483-486.

Rocha B, von Boehmer H, Guy-Grand D, 1992a. Selection of intraepithelial lymphocytes with CD8 α/α co-receptors by self-antigen in the murine gut. Proc Natl Acad Sci USA; 89: 5336-5340.

Rocha B, Vassalli P, Guy-Grand D, 1992b. The extrathymic T-cell development pathway. Immunology Today; 13: 449-458.

Rocha B, Vassalli P, Guy-Grand D, 1994. Thymic and extrathymic origins of gut intraepithelial lymphocyte populations in mice. J Exp Med; 180: 681-686.

Rocha B, Guy-Grand D, Vassalli P, 1995. Extrathymic T cell differentiation. Curr Opin Immunol; 7: 235-242.

Rosner AJ, Keren DF, 1984. Demonstration of M cells in the specialized follicle-associated epithelium overlying isolated lymphoid follicles in the gut. J Leuk Biol; 35: 397-404.

Rothenberg EV, 1992. The development of functionally responsive T cells. Adv Immunol; 51: 85-214.

Rothenberg EV, Chen D, Diamond RA, 1993. Functional and phenotypic analysis of thymocytes in SCID mice. J Immunol; 151: 3530-3546.

Rouse RV, Reichert RA, Gallatin WM, Weissman IL, Butcher EC, 1984. localization of lymphocyte subpopulations in peripheral lymphoid organs: directed lymphocyte migration and segregation into specific microenvironments. Am J Anat; 170: 391-405.

Rowinski J, Lamprecht J, Sicinski P, 1984. Non-random distribution of intraepithelial lymphoid cells in follicle-associated epithelium of Peyer's patches in mice. J Anat; 139: 21-32.

Rudzick O, Bienenstock J, 1974. Isolation and characteristics of gut mucosal lymphocytes. Lab Invest; 30: 260-266.

Ruedl C, Rieser C, Böck G, Wick G, Wolf H, 1996. Phenotypic and functional characterization of CD11c^{+} dendritic cell population in mouse Peyer's patches. Eur J Immunol; 26: 1801-1806.

Ruedl C, Hubele S, 1997. Maturation of Peyer's patch dendritic cells *in vitro* upon stimulation via cytokines or CD40 triggering. Eur J Immunol; 27:1325-1330.

Sato Y, Tsukada K, Iiai T, Ohmori K, Yoshida K, Muto T, Watanabe H, Matsumoto Y, Abo T, 1993. Activation of extrathymic T cells in the liver during liver regeneration following partial hepatectomy. Immunology; 78: 86-91.

Saito H, Kanamori Y, Takemori T, Nariuchi H, Kubota E, Takahashi-Iwanaga H, Iwanaga T, Ishikawa H, 1998. Generation of intestinal T cells from progenitors residing in gut cryptopatches. Science; 280: 275-278.

Saitoh SI, Kosugi A, Noda S, Yamamoto N, Ogata M, Minami Y, Miyake K, Hamaoka T, 1995. Modulation of TCR-mediated signaling pathway by thymic shared antigen-1 (TSA-1)/ stem cell antigen-2 (Sca-2). J Immunol; 155: 5574-5581.

Samaridis J, Casorati G, Traunecker A, Iglesias A, Gutierrez JC, Muller L, Palacios R, 1991. Development of lymphocytes in interleukin 7-transgenic mice. J Immunol; 21: 453-460.

Schall TJ, Lewis M, Koller KJ, Lee A, Rice GC, Wong GHW, Gatanaga T, Granger GA, Lentz R, Raab H, Kohr WJ, Goeddel DV, 1990. Molecular cloning and expression of a receptor for human tumor necrosis factor. Cell; 61: 361-370.

Schatz DG, Oettinger MA, Baltimore D, 1989. The V(D)J recombinaton activating gene, RAG-1. Cell; 59: 1035-1048.

Schorle H, Holtschke T, Hunig T, Schimpl A, Horak I, 1991. Development and function of T cells in mice rendered interleukin-2 deficient by gene targeting. Nature; 352: 621-624.

Schuler W, Weiler IJ, Schuler A, Phillips RA, Rosenberg N, Mak TW, Kearney JF, Perry RP, Bosma MJ, 1986. Rearrangement of antigen receptor genes is defective in mice with severe combined immune deficiency. Cell; 46: 963-972.

Schuler W, Schuler A, Lennon GG, Bosma GC, Bosma MJ, 1988. Transcription of unrearranged antigen receptor genes in scid mice. EMBO J; 7: 2019-2024.

Scollay RG, Butcher EC, Weissman IL, 1980. Thymus cell migration. Quantitative aspects of cellular traffic from the thymus to the periphery in mice. Eur J Immunol; 10: 210- 218.

Scollay R, Bartlett P, Shortman K, 1984. T cell development in the adult murine thymus: changes in the expression of the surface antigens LY2, L3T4 and B2A2 during development from early precursor cells to emigrants. Immunological Reviews; 82: 79-103.

Scollay R, Shortman K, 1984. Contribution of thymus lymphocytes to the peripheral lymphoid tissues and the effect of antigen on the rate of cell exit from the thymus. Am J Anat; 170: 331-338.

Scollay R, Wilson A, D'Amico A, Kelly K, Egerton M, Pearse M, Wu L, Shortman K, 1988. Developmental status and reconstitution potential of subpopulations of murine thymocytes. Immunol Rev; 104: 81-120.

Scollay R, Godfrey DI, 1995. Thymic emigration: conveyor belts or lucky dips? Immunology Today; 16: 268-274.

Scott H, Solheim BG, Brandtzaeg P, Thorsby E, 1980. HLA-DR like antigens in the epithelium of the small intestine. Scand J Immunol; 12: 77-82.

Seki S, Abo T, Masuda T, Ohteki T, Kanno A, Takeda K, Rikiishi H, Nagura H, Kumagai K, 1990. Identification of activated T cell receptor γδ lymphocytes in the liver of tumor-bearing hosts. J Clin Invest; 86: 409-415.

Seki S, Abo T, Sugiura K, Ohteki T, Kobata T, Yagita H, Okumura K, Rikiishi H, Masuda T, Kumagai K, 1991a. Reciprocal T cell responses in the liver and thymus of mice injected with syngeneic tumor cells. Cell Immunol; 137: 46-60.

Seki S, Abo T, Ohteki T, Sugiura K, Kumagai K, 1991b. Unusual αβ-T cells expanded in autoimmune lpr mice are probably a counterpart of normal T cells in the liver. J Immunol; 147: 1214-1221.

Selby WS, Janossy G, Jewell DP, 1981. Immunohistological characterization of intraepithelial lymphocytes of the human gastrointestinal tract. Gut; 22: 169-176.

Selby WS, Poulter LW, Hobbs S, Jewell DP, Janossy G, 1983. Heterogeneity of HLA-DR-positive histiocytes in human intestinal lamina propria: a combined histochemical and immunohistological analysis. J. Clin. Pathol.; 36: 379-384.

Serizawa H, Miura S, Tashiro H, Imaeda H, Shiozaki H, Tanaka S, Yoshioka M, Ohara M, Hibi T, Yamashita A, Tsuchiya M, 1993. Significant changes in intestinal lymphatic system and immune response elicited by Peyer's patch excision in adult rats. J Gastroenterol Hepatol; 8: 63-69.

Shimonkevitz RP, Husmann LA, Bevan MJ, Crispe IN, 1987. Transient expression of IL-2 receptor precedes the differentiation of immature thymocytes. Nature; 329: 157-159.

Shinkai Y, Rathbun G, Lam KP, Oltz EM, Stewart V, Mendelsohn M, Charron J, Datta M, Young F, Stall AM, Alt FW, 1992. RAG-2 deficient mice lack mature lymphocytes owing to inability to initiate V(D)J rearrangement. Cell; 68: 855-867.

Shores EW, Sharrow SO, Uppenkamp I, Singer A, 1990. T cell receptor-negative thymocytes from SCID mice can be induced to enter the CD4/CD8 differentiation pathway. Eur J Immunol; 20: 69-77.

Shorter RG, Tomasi TB, 1982. Immune mechanisms in the small intestine: Part 1. In: Chadwick VS, Phillips SF, eds. Gastroenterology 2. London: Butterworth Scientific: 73-79.

Shortman K, Wilson A, Egerton M, Pearse M, Scollay R, 1988. Immature $CD4^-$ $CD8^+$ murine thymocytes. Cell Immunol; 113: 462-479.

Siebrecht MS, Hsia E, Spychalski C, Nagler-Anderson C, 1993. Stimulation of murine intestinal intraepithelial lymphocytes by the bacterial superantigen staphylococcal enterotoxin B. Int Immunol; 5: 717-724.

Smith MW, Peacock MA, 1980. "M" cell distribution in follicle-associated epithelium of mouse Peyer's patch. Am J Anat; 159: 167-175.

Smith SH, Brown MH, Rowe D, Callard RE, Beverley PC, 1986. Functional subsets of human helper-inducer cells defined by a new monoclonal antibody UCHL-1. Immunology; 58: 63-70.

Smith CA, Farrah T, Goodwin RG, 1994. The TNF receptor superfamily of cellular and viral proteins: activation, costimulation, and death. Cell; 76: 959-962.

Sotzik F, Rosenberg Y, Boyd AW, Honeyman M, Metcalf D, Scollay R, Wu L, Shortman K, 1994. Assessment of CD4 expression by early T precursor cells and by dendritic cells in the human thymus. J Immunol; 152: 3370-3377.

Spangrude GJ, Heimfeld S, Weissman IL, 1988a. Purification and characterization of mouse hematopoietic stem cells. Science; 241: 58-62.

Spangrude GJ, Aihara Y, Weissman IL, Klein J, 1988b. The stem cell antigens Sca-1 and Sca-2 subdivide thymic and peripheral T lymphocytes into unique subsets. J Immunol; 141: 3697-3707.

Spangrude GJ, Klein J, Heimfeld S, Aihara Y, Weissman IL, 1989. Two monoclonal antibodies identify thymic-repopulating cells in mouse bone marrow. J Immunol; 142: 425-430.

Spencer J, Finn T, Isaacson PG, 1986a: Human Peyer's patches: an immunohistochemical study. Gut; 27: 405-410.

Spencer J, Finn T, Isaacson PG, 1986b. Expression of HLA-DR antigens on epithelium associated with lymphoid tissue in the human gastrointestinal tract. Gut; 27: 153-157.

Spencer J, MacDonald TT, Fin T, Isaacson PG, 1986c. The development of gut associated lymphoid tissue in the terminal ileum of fetal human intestine. Clin Exp Immunol; 64: 536-543.

Spencer J, Dogan A, Dunn-Walters D, 1997. Ontogeny of human mucosal immunity and the origin of mucosal effector cells. Immunol Cell Biol; 75: A27 (abstract).

Sprent J, Lo D, Gao EK, Ron Y, 1988. T cell selection in the thymus. Immunol Rev; 101: 173-190.

Springer T, Galfre' G, Secher DS, Milstein C, 1978. Monoclonal xenogeneic antibodies to murine cell surface antigens: identification of novel leukocyte differentiation antigens. Eur J Immunol; 8: 539-551.

Springer T, Galfré G, Secher DS, Milstein C, 1979. Mac-1: a macrophage differentiation antigen identified by monoclonal antibody. Eur J Immunol; 9: 301-306.

Stickney DG, Wang J, Hamad M, Klein JR, 1994. Heat stable antigen may be an early marker of extrathymic murine intestinal intraepithelial lymphocytes. Blood; 84: 3034-3039.

Sudo T, Nishikawa S, Ohno N, Akiyama N, Tamakoshi M, Yoshida H, Nishikawa SI, 1993. Expression and function of the interleukin 7 receptor in murine lymphocytes. Proc Natl Acad Sci; 90: 9125-9129.

Suzuki H, Kundig TM, Furlonger C, Wakeham A, Timms E, Matsuyama T, Schmits R, Simard JJL, Ohashi PS, Griesser H, Taniguchi T, Paige CJ, Mak TW, 1995. Deregulated T cell activation and autoimmunity in mice lacking interkeukin-2 receptor β. Science; 268: 1472-1476.

Sydora BC, Mixter PF, Holcombe HR, Eghtesady P, Williams K, Amaral MC, Nel A, Kronenberg M, 1993. Intestinal intraepithelial lymphocytes are activated and cytolytic but do bot proliferate as well as other T cells in response to mitogenic signals. J Immunol; 150: 2179-2191.

Takahama Y, Hasegawa T, Itohara S, Ball EL, Sheard MA, Hashimoto Y, 1994. Entry of $CD4^-CD8^-$ immature thymocytes into the CD4/CD8 developmental pathway is controlled by tyrosine kinase signals that can be provided through TCR components. Int Immunol; 6: 1505-1514.

Takei F, Secher DS, Milstein C, Springer T, 1981. Use of a monoclonal antibody specifically non-reactive with T cells to delineate lymphocyte subpopulations. Immunology; 42: 371-378.

Takimoto H, Nakamura T, Takeuchi M, Sumi Y, Tanaka T, Nomoto K, Yoshikai Y, 1992. Age-associated increase in number of $CD4^+CD8^+$ intestinal intraepithelial lymphocytes in rats. Eur J Immunol; 22: 159-164.

Taniguchi M, Makino Y, Cui J, Masuda K, Kawano T, Sato H, Kondo E, Koseki H, 1996. $V\alpha14^+$ NK T cells: A novel lymphoid cell lineage with regulatory function. J Allergy Clin Immunol; 98: S263-269.

Taplin ME, Frantz ME, Canning C, Ritz J, Blumberg RS, Balk SP, 1996. Evidence against T-cell development in the adult human intestinal mucosa based upon lack of terminal deoxynucleotidyltransferase expression. Immunology; 87: 402-407.

Tentori L, Pardoll DM, Zuniga JC, Hu-Li J, Paul WE, Bluestone JA, Kruisbeek AM, 1988a. Proliferation and production of IL-2 and B cell stimulatory factor 1/IL-4 in early fetal thymocytes by activation through Thy-1 and CD3. J Immunol; 140: 1089-1094.

Tentori L, Longo DL, Zuñiga-Pflucker JC, Wing C, Kruisbeek AM, 1988b. Essential role of the interleukin 2-interleukin 2 receptor pathway in thymocyte maturation *in vivo*. J Exp Med; 168: 1741-1747.

Thomas FT, Marchman W, Carobbi A, Araneda D, Pryor W, Thomas J, 1991. Immunobiology of the xenograft response: xenograft rejection in immunodeficient animals. Transplant Proc; 23: 208-209.

Thompson CB, 1995. New insights into V(D)J recombination and its role in the evolution of the immune system. Immunity; 3: 531-539.

Toribio ML, De La Hera A, Marcos MAR, Marquez C, Martinez-A C, 1989. Activation of the interleukin 2 pathway precedes CD3-T cell receptor expression in thymic development. Differential growth requirements of early and mature intrathymic subpopulations. Eur J Immunol; 19: 9-15.

Trowbridge IS, Lesley J, Schulte R, Hyman R, Trotter J, 1982. Biochemical characterization and cellular distribution of a polymorphic, murine cell-surface glycoprotein expressed on lymphoid tissues. Immunogenetics; 15: 299-312.

Tseng J, 1982. Expression of immunoglobulin isotypes by lymphoid cells of mouse intestinal lamina propria. Cell Immunol, 73: 324-336.

Tsuchida M, Iiai T, Watanabe H, Abo T, 1992. Relative resistance of intermediate TCR cells to anti-CD3 mAb in mice *in vivo* and their partial functional characterization. Cell Immunol; 145: 78-90.

Tucek CL, Boyd RL, 1990. Surface expression of CD4 and Thy-1 on mouse thymic stromal cells. Int Immunol; 2: 593-601.

Tucek CL, Godfrey DI, Boyd RL, 1992. Five novel antigens illustrate shared phenotype between mouse thymic stromal cells, thymocytes, and peripheral lymphocytes. Int Immunol; 4 :1021-1030.

Turka LA, Schatz DG, Oettinger MA, Chun JJM, Gorka C, Lee K, McCormack WT, Thompson CB, 1991. Thymocyte expression of RAG-1 and RAG-2: termination by T cell receptor cross-linking. Science; 253: 778-781.

Ullrich R, Schieferdecker HL, Ziegler K, Riecken EO, Zeitz M, 1990. γδ T cells in the human intestine express surface markers of activation and are preferentially located in the epithelium. Cell Immunol; 128: 619-627.

Umesaki Y, Setoyama H, Matsumoto S, Okada Y, 1993. Expansion of αβ T-cell receptor-bearing intestinal intraepithelial lymphocytes after microbial colonization in germ-free mice and its independence from thymus. Immunology; 79: 32-37.

Vaessen LMB, Broekhuizen R, Rozing J, Vos JG, Schuurman HJ, 1986. T-cell development during aging in congenitally athymic (nude) rats. Scand J Immunol; 24: 223-235.

Vassalli P, 1992. The pathophysiology of tumor necrosis factors. Annu Rev Immunol; 10: 411-452.

Vicari A, Abehsira-Amar O, Papiernik M, Boyd RL, Tucek CL, 1994. MTS-32 monoclonal antibody defines $CD4^{+}8^{-}$ thymocyte subsets that differ in their maturation level, lymphokine secretion, and selection patterns. J Immunol; 152: 2207-2213.

Vicari AP, Zlotnik A, 1996. Mouse $NK1.1^{+}$ T cells: a new family of T cells. Immunology Today; 17: 71-76.

Viney JL, MacDonald TT, Kilshaw PJ, 1989. T-cell receptor expression in intestinal intra-epithelial lymphocyte subpopulations of normal and athymic mice. Immunology; 66: 583-587.

Vissinga CS, Fatur-Saunders DJ, Takei F, 1992. Dual role of IL-7 in the growth and differentiation of immature thymocytes. Exp Hematol; 20: 998-1003.

von Boehmer H, 1992. Thymic selection: a matter of life and death. Immunology Today; 13: 454-458.

von Boehmer H, Crisanti A, Kisielow P, Haas W, 1985. Absence of growth by most receptor-expressing fetal thymocytes in the presence of interleukin-2. Nature; 314: 539-540.

Vos JG, Kreeftenberg JG, Kruijt BC, Kruizinga W, Steerenberg P, 1980. The athymic nude rat. II. Immunological characteristics. Clin Immunol Immunopathol; 15: 229-237.

Vremec D, Zorbas M, Scollay R, Saunders DJ, Ardavin CF, Wu L, Shortman K, 1992. The surface phenotype of dendritic cells purified from mouse thymus and spleen: Investigation of the CD8 expression by a subpopulation of dendritic cells. J Exp Med; 176: 47-58.

Watanabe H, Iiai T, Kimura M, Ohtsuka K, Tanaka T, Miyasaka M, Tsuchida M, Hanawa H, Abo T, 1993. Characterization of intermediate TCR cells in the liver of mice with respect to their unique IL-2R expression. Cell Immunol; 149: 331-342.

Watson JD, Morrissey PJ, Namen AE, Conlon PJ, Widmer MB, 1989. Effect of IL-7 on the growth of fetal thymocytes in culture. J Immunol; 143: 1215-1222.

Weissman IL, 1973. Thymus cell maturation. Studies on the origin of cortisone-resistant thymic lymphocytes. J Exp Med; 137: 504-510.

Westermann J, Nagahori Y, Walter S, Heerwagen C, Miyasaka M, Pabst R, 1994. B and T lymphocyte subsets enter peripheral lymph nodes and Peyer's patches without preference *in vivo*: no correlation occurs between their localization in different types of high endothelial venules and the expression of CD44, VLA-4, LFA-1, ICAM-1, CD2, or L-selectin. Eur J Immunol; 24: 2312-2316.

Whitehead R, Roca M, Meikle DD, Skinner J, Truelove SC, 1975. The histological classification of duodenitis in fibreoptic biopsy specimens. Digestion; 13: 129-136.

Whitehead R, 1990. Mucosal biopsy of the gastrointestinal tract. 4th ed. Philadelphia: Saunders: 161-170.

Wilders MM, Sminia T, Plesch BEC, Drexhage HA, Weltevreden EF, Meuwissen SGM, 1983. Large mononuclear Ia-positive veiled cells in Peyer's patches. II. Localization in rat Peyer's patches. Immunology; 48: 461-467.

Wiler R, Leber R, Moore BB, VanDyk LF, Perryman LE, Meek K, 1995. Equine severe combined immunodeficiency: a defect in V(D)J recombination and DNA-dependent protein kinase activity. Proc Natl Acad Sci; 92: 11485-11489.

Wilkinson RW, Anderson G, Owen JJ Jenkinson EJ, 1995. Positive selection of thymocytes involves sustained interactions with the thymic microenviroment. J Immunol; 155: 5234-5240.

Willerford DM, Chen J, Ferry JA, Davidson L, Ma A, Alt FW, 1995. Interleukin-2 receptor α chain regulates the size and content of the peripheral lymphoid compartment. Immunity; 3: 521-530.

Wilson A, D'Amico A, Ewing T, Scollay R, Shortman K, 1988. Subpopulations of early thymocytes. A cross-correlation flow cytometric analysis of adult mouse Ly-2$^-$ L3T4$^-$ (CD8$^-$ CD4$^-$) thymocytes using eight different surface markers. J Immunol; 140: 1461-1469.

Wilson AD, Bland PW, Stokes CR, 1990. Expression and distribution of Ia antigen in the murine small intestine. Influences of environment and cholera toxin. Int Arch Allergy Appl Immunol; 91: 348-353.

Wilson A, Corthésy P, Reichenbach P, MacDonald HR, Nabholz M, 1994a. Interleukins (IL)-1 and IL-2 control IL-2 receptor α and β expression in immature thymocytes. Eur J Immunol; 24: 1729-1735.

Wilson A, Held W, MacDonald HR, 1994b. Two waves of recombinase gene expression in developing thymocytes. J Exp Med; 179: 1355-1360.

Wineman JP, Gilmore GL, Gritzmacher C, Torbett BE, Müller-Sieburg CE, 1992. CD4 is expressed on murine pluripotent hematopoietic stem cells. Blood; 80: 1717-1724.

Winkel K, Sotzik F, Vremec D, Cameron PU, Shortman K, 1994. CD4 and CD8 expression by human and mouse thymic dendritic cells. Immunol Lett; 40: 93-99.

Witmer MD, Steinman RM, 1984. The anatomy of peripheral lymphoid organs with emphasis on accessory cells: light-microscopic immunocytechemical studies of mouse spleen, lymph node, and Peyer's patch. Am J Anat; 170: 465-481.

Wolf JL, Rubin DH, Finberg R, Kauffman RS, Sharpe AH, Trier JS, Fields BN, 1981. Intestinal M cells: a pathway for entry of reovirus into the host. Science; 212: 471-472.

Wu L, Scollay R, Egerton M, Pearse M, Spangrude GJ, Shortman K, 1991a. CD4 expressed on earliest T-lineage precursor cells in the adult murine thymus. Nature; 349: 71-74.

Wu L, Antica M, Johnson GR, Scollay R, Shortman K, 1991b. Developmental potential of the earliest precursor cells from the adult mouse thymus. J Exp Med; 174: 1617-1627.

Wu L, Li CL, Shortman K, 1996. Thymic dendritic cell precursors: Relationship to the T lymphocyte lineage and phenotype of the dindritic cell progeny. J Exp Med; 184: 903-911.

Yang-Snyder JA, Rethenberg EV, 1993. Developmental and anatomical patterns of IL-2 gene expression *in vivo* in the murine thymus. Dev Immunol; 3: 85-102.

Yoshikai Y, Reis MD, Mak TW, 1986. Athymic mice express a high level of functional γ-chain but greatly reduced levels of α- and β-chain T-cell receptor messages. Nature; 324: 482-485.

Zeitz M, Schieferdecker HL, Ullrich R, Jahn HU, James SP, Riecken EO, 1991. phenotype and function of lamina propria T lymphocytes. Immunol Res; 10: 199-206.

Zola H, Barclay S, Furness V, Macardle PJ, Neoh SH, Bradley J, 1988. B lymphocyte/ carcinoma antigen (BLCa): Functional study in B cells. Immunol Cell Biol; 66: 199-208.

Zola H, Melo JV, Zowtyi HN, Nikoloutsopoulos A, Skinner J, 1990. The leukocyte-common antigen (CD45) complex and B-lymphocyte activation. Human Immunology; 27: 368-377.

Zola H, Macardle PJ, Flego L, Webster J, 1991a. The expression of sub-population markers on B cells: a re-evaluation using high-sensitivity fluorescence flow cytometry. Disease Markers; 9: 103-118.

Zola H, Macardle PJ, Bradford T, Weedon H, Yasui H, Kurosawa Y, 1991b. Preparation and characterization of a chimeric CD19 monoclonal antibody. Immunol Cell Biol; 69: 411-422.

Zúñiga-pflücker JC, Schwartz HL, Lenardo MJ, 1993. Gene transcription in differentiaing immature T cell receptor^{neg} thymocytes resembles antigen-activated mature T cells. J Exp Med; 178: 1139-1149.

Zuniga-Pflucker JC, Jiang D, Schwartzberg PL, Lenardo MJ, 1994. Sublethal γ-radiation induces differentiation of $CD4^-$ /$CD8^-$ into $CD4^+$/$CD8^+$ thymocytes without T cell receptor β rearrangement in recombinase activation gene 2-/- mice. J Exp Med; 180: 1517-1521.

ERRATA & ADDENDA

I- ERRATA

1. P.29, line 16: " it also expressed..." **should read** " it is also expressed..."
2. P.43, line 2: "presonal" **should read** "personal"
3. P.52, para. 3, line 2: "...they appear not undergo..." **should read** "...they appear not to undergo..."
4. P.55, para. 1, line 13: "...are site of..." **should read** "...are sites of..."
5. P.80, para. 3, line 4: "intrathytmic" **should read** "intrathymic"
6. P.80, para. 3, line 6: "...more detailed phenotype was..." **should read** "...more detailed phenotypic analysis was..."
7. P. 89, para. 2, line 10: "...due to use different..." **should read** "...due to use of different..."
8. P.102, para. 1, line 5: "fist" **should read** "first"
9. P.103, para. 1, line 5: "C56Bl/6" **should read** "C57Bl/6"
10. P.108, para. 2, line 3: "These mice that have..." **should read** "These mice have..."
11. P.113, para. 2, line 1: "...in in *situ*..." **should read** "...in *situ*..."
12. P.115, para. 1, line 4: "...labelled cells with thymidine..." **should read** "...cells labelled with thymidine..."
13. P.131, para. 2, line 7: "varients" **should read** "variants"
14. P.132, para. 2, line 6: "Poskit" **should read** "Poskitt"
15. P. 134, para. 1, line 4: "..reflects that nature.." **should read** "...reflects the nature..."
16. P. 137, line 2: "..play last.." **should read** "...play host..."
17. P. 140, line 1: "...most of lymphocytes..." **should read** "...most lymphocytes..."
18. P. 145, para. 3, line 1: "Together, analysis the phenotypes..."...**should read** "Together, analysis of the phenotypes..."

19. P. 145, para. 3, line 2: "...are may be..." **should read** "...may be..."

20. P. 146, para. 2, line 3: "...functional homologous..." **should read** "...functional homologues..."

II- ADDENDA

Table 3.1. Macroscopic examination of Peyer's patches (PP) and mesenteric lymph nodes (MLN) were undertaken on 1 mouse of TNF$\alpha^{-/-}$, 3 mice of each LT$\alpha^{-/-}$ and LT$\beta^{-/-}$ and 2 mice of TNF/LT$^{-/-}$ genotype. Examination of intraepithelial lymphocytes (IEL) and lymphocyte filled villi (LFV) were conducted on serial sections from Swiss rolls of each genotype.

Table 5.1. Cortisone treated mice (n=43). This is the number of LFV examined in random sections from Swiss rolls in 2 treated mice.
cortisone untreated control (n=28). This is the number of LFV examined in random sections from Swiss rolls in one control mouse.

09PH
M6959
c.2

GASTROENTEROLOGY 1998;115:1414–1425

UNIVERSITY OF ADELAIDE LIBRARY 14/9/99

Lymphocyte-Filled Villi: Comparison With Other Lymphoid Aggregations in the Mucosa of the Human Small Intestine

MAHIN MOGHADDAMI,* ADRIAN CUMMINS,† and GRAHAM MAYRHOFER*

*Department of Microbiology and Immunology, University of Adelaide, Adelaide; and †Gastroenterology Unit, The Queen Elizabeth Hospital, Woodville, South Australia, Australia

See editorial on page 1588.

Background & Aims: Solitary lymphoid structures that may be sites of primary extrathymic T-cell differentiation have been described recently in murine (cryptopatches) and rat (lymphocyte-filled villi) small intestine. This study tests the hypothesis that similar structures occur in human small intestine. *Methods:* Normal small intestine was obtained during surgery. Fixed tissue was examined histologically, and frozen sections were examined by an indirect immunoperoxidase technique using a panel of mouse monoclonal antibodies. *Results:* A new isolated lymphoid structure, with epithelium resembling follicle-associated epithelium of Peyer's patches, is described as a lymphocyte-filled villus. These structures contain major histocompatibility complex (MHC) class II–positive dendritic cells, a majority of memory T cells, a variable B-cell component, and no evidence of immature lymphocytes that express either c-*kit* or CD1a. Two previously described lymphoid aggregations (isolated lymphoid follicles and submucosal lymphoid aggregations) are components of a single structure. The complete structure contains a B-cell follicle, T cells with mainly memory (CD45RO-positive) phenotype, high endothelial venules, and no detectable population of immature lymphocytes. *Conclusions:* A new solitary lymphoid structure is described in the human small intestine. Neither these structures nor isolated lymphoid follicles appear to be similar to solitary primary lymphoid structures in rodent intestine.

The gut is a major site of initial contact between foreign antigenic materials and immunologically competent cells. The gut-associated lymphoid tissues are thought to function as secondary lymphoid organs,[1] although recent evidence[2,3] suggests that the epithelium of the human[4–6] and mouse[7,8] small intestine may be a site of primary extrathymic T-cell differentiation. The organized gut-associated lymphoid tissues in the small intestine consist principally of Peyer's patches (PPs) and the mesenteric lymph nodes.[1] PPs are aggregations of lymphoid follicles that generally have an antimesenteric distribution, although in humans they are situated occasionally at random around the circumference of the gut wall.[9] The number and size of PPs increases for at least the first 10 years of life and reaches a maximum at puberty.[9] The number of follicles in each patch varies from as few as five to several hundreds but decreases with age beyond puberty.[10] The most obvious component of the PPs[11–16] is the follicle, consisting of a germinal center and the surrounding corona of B cells. Overlying the follicle is the dome region, consisting mainly of T cells and the specialized follicle-associated epithelium (FAE). The FAE contains specialized microfold (M) cells[15,17,18] that have been shown in mice to transport macromolecules and infectious agents from the gut lumen into the PPs.[19,20] The interfollicular regions contain T cells, interdigitating cells, and high endothelial venules (HEVs). PPs are important sites of lymphocyte recirculation.[1]

Other forms of lymphoid aggregations that have been described in the wall of the human small intestine are isolated lymphoid follicles (ILFs), which lie within the mucosa, and submucosal lymphocyte aggregations (SLAs), which lie within the muscularis mucosa.[21] These are observed commonly on histological examination, but they are not visible macroscopically.[22–24] The number of these lymphoid aggregations increases in the more distal parts of the small intestine.[23] Both ILFs and SLAs are accepted as normal components of the small intestinal mucosa,[24] and they are assumed to represent solitary PP follicles.[25] The presence of microfold or membranous (M) cells in the FAE overlying similar structures in guinea pigs[26] supports this view.

Abbreviations used in this paper: FAE, follicle-associated epithelium; HEV, high endothelial venule; IEL, intraepithelial lymphocyte; ILF, isolated lymphoid follicle; LFV, lymphocyte-filled villi; MAb, monoclonal antibody; MHC class II, class II molecule encoded in the human major histocompatibility complex; PP, Peyer's patch; SLA, submucosal lymphoid aggregate.

© 1998 by the American Gastroenterological Association
0016-5085/98/$3.00

However, Kanamori et al.[27] described recently the presence of novel lymphoid structures (cryptopatches) in the mucosa of the mouse small intestine. The differentiation markers expressed by the lymphoid cells in cryptopatches (e.g., c-*kit* and interleukin 7 receptor) suggest that these structures may have a primary generative function. This concept is supported by the presence of cryptopatches in both severe combined immunodeficient and recombinase activating gene 1 knockout mice. The cryptopatch occupies the lamina propria in the crypt region of the mucosa, and it was estimated that the small intestine contains approximately 1500 of these structures. We have observed similar structures in rat,[28] mouse, and Syrian hamster (Moghaddami and Mayrhofer, unpublished data, June 1995) small intestine. In both rats and mice, the structures that we observe appear more numerous than cryptopatches (approximately 1 per 100 villi), and the packed lymphocytes occupy most of the lamina propria of the villus and extend to the muscularis mucosa. We have named these structures lymphocyte-filled villi (LFV). In both species, LFV contain some mature (mainly CD4-positive) T cells, but the majority population expresses neither surface immunoglobulin, CD3, nor the T-cell receptor (α/β or γ/δ), and many express CD25. LFV are sites of significant cell division, but they are excluded from the recirculation of thoracic duct lymphocytes. However, the epithelium overlying LFV has similarities to FAE in that it contains large numbers of intraepithelial lymphocytes (IELs) and large MHC class II–positive dendritic cells,[29] and it transports horseradish peroxidase from the gut lumen. It is our hypothesis that LFV are extrathymic sites of primary T-cell differentiation, where lumenal antigens may play a role in repertoire expansion and/or selection. Neither Kanamori et al.[27] nor ourselves have shown the transcriptional or translational activities of RAGs or rearrangement of T-cell receptor genes in either cryptopatches or LFV.

The presence of novel lymphoid aggregations in the small intestines of laboratory animals has prompted us to reexamine the structure and function of solitary lymphoid tissues in the mucosa of the human small intestine. Resection specimens of apparently normal human small intestine have been examined histologically and by immunohistochemistry. The distribution of ILFs and SLAs and the surface antigen phenotypes of the lymphocytes within them have been compared with PPs. A third structure, also designated a lymphocyte-filled villus because of morphological similarities with LFV in rodents, has been identified and compared with the other more organized solitary lymphoid tissues.

Materials and Methods

Small Bowel Specimens

Segments of small intestine were obtained at surgery from 6 adult patients at sites of intended anastomosis (details in Table 1). Informed consent was obtained under guidelines of the Human Ethics Committee of The Queen Elizabeth Hospital. In 3 patients (surgical treatment of obesity), there was no intra-abdominal pathology. However, in 1 (patient 2), the specimen was obtained from a blind loop during revision of a therapeutic gastroileal bypass. In the other 3 patients (resections of cecal or colonic carcinoma or treatment of chronic pancreatitis), segments of small intestine distant from the disease were obtained during anastomotic procedures. The segments were chilled on ice and transported to the laboratory within 30–60 minutes of resection. Each specimen was opened longitudinally along the attachment of the mesentery. This provided tissue that included the undisturbed antimesenteric portion of the circumference of the intestine. In some cases, parts of the surgical specimen were opened longitudinally opposite to the mesenteric attachment (antimesenteric). These segments provided mucosa that included the undisturbed mesenteric portion of the circumference. The mucosa was dissected free from the muscularis in the tissue plane of the submucosa using fine scissors. Strips of mucosa were cut in the longitudinal axis of the intestine, fixed in 10% neutral formalin, and processed for embedding in paraffin wax. In some cases, longer strips were prepared as "Swiss rolls" before fixation. Other strips of tissue were embedded in OCT medium (Tissue-Tek; Ames Division, Miles Laboratories, Elkhart, IN), frozen by cooling in an isopentane bath chilled with liquid nitrogen,[30] and stored at −70°C.

Immunologic and Immunohistochemical Reagents

The sources and the specificities of the monoclonal antibodies (MAbs) used in this study are shown in Table 2. A mouse antigiardia MAb (1B5, immunoglobulin [Ig] G1) was used as an irrelevant negative control (Mayrhofer, unpublished data). The horseradish peroxidase conjugate of F(ab′)2 sheep anti-mouse Ig (immunopurified and absorbed with

Table 1. Details of Tissue Donors Used

Source (case no.)	Pathological status of specimen	Age (*yr*)	Sex	Diagnosis
Jejunum (3)	Normal	37	M	Obesity[a]
Jejunum (5)	Normal	27	F	Obesity[a]
Jejunum (4)	Normal	66	M	Chronic pancreatitis[b]
Jejunum (2)	Blind loop	36	M	Obesity[c]
Ileum (1)	Normal	26	F	Carcinoma, cecum[d]
Ileum (6)	Normal	78	M	Carcinoma, colon[d]

[a]Creation of gastric bypass.
[b]Pancreatico-jejunostomy.
[c]Reversal of gastric bypass.
[d]Right hemicolectomy.

Table 2. MAbs Used

Cluster of differentiation	MAb	Source	Main specificity	Study
CD1a	OKT6	ATCC	Cortical thymocytes, Langerhans' cells	—
CD2	OKT11	ATCC	Thymocytes, T cells, NK cells	—
CD3	OKT3	ATCC	Thymocytes, T cells	—
CD4	OKT4	ATCC	Thymocyte and T-cell subsets, monocytes, macrophages	—
CD5	WM-13	Dr. McArdle[a]	Thymocytes, T cells, subset B cells	Zola et al.[31]
CD7	HB2	Dr. McArdle[a]	Hematopoetic stem cells, thymocytes, T cells	Knapp et al.[32]
CD8	OKT8	ATCC	Thymocyte and T-cell subsets	—
CD19	FMC63	Dr. McArdle[a]	B cells	Zola et al.[33]
CD20	L26	Dako	B cells	Petruch et al.[34]
CD25	7G7-B6	Dr. McArdle[a]	Subset cortical thymocytes, activated T cells, B cells, monocytes	Knapp et al.[32]
CD45RA	FMC-7	Dr. McArdle[a]	Naive T cells, B cells, monocytes	Ferro et al.[35]
CD45RO	UCHL-1	Dr. McArdle[a]	Memory T cells, B-cell subset, monocytes, macrophages	Smith et al.[36]
CD71	OKT9	ATCC	All proliferating cells	—
CD117 (c-kit)	YB5-B8	Dr. Ashman[b]	Hematopoietic progenitors, subset of thymocytes	Ashman et al.[37]
MHC class II	FMC52	Dr. McArdle[a]	Dendritic cells, monocytes, macrophages, B cells	Zola et al.[38]

ATCC, American Type Culture Collection; MHC, major histocompatibility complex; NK, natural killer.
[a]Provided by Dr. P. McArdle, Flinders Medical Centre, South Australia.
[b]Provided by Dr. L. Ashman, Hanson Centre for Cancer Research, Institute of Medical and Veterinary Science, South Australia.

human Ig) was obtained from Amersham Life Science (Sydney, New South Wales, Australia). This conjugate (horseradish peroxidase–conjugated sheep anti-mouse Ig) was used at a dilution of 1:20.

Histology and Immunohistochemistry

Sections (5 μm) from paraffin-embedded blocks were dewaxed and stained with H&E. Random sections were examined to identify and to estimate the frequency of specific lymphoid tissues. In some cases, serial sections were collected and stained to allow examination of complete lymphoid aggregations.

For immunohistochemical studies, 5-μm sections were cut from frozen tissue blocks and air-dried at room temperature for at least 1 hour before fixation in either 95% ethanol or acetone at 4°C for 10 minutes. After rehydration in cold phosphate-buffered saline (pH 7.4), the sections were stained by an indirect immunoperoxidase technique, essentially as described elsewhere.[30] Normal human serum (final concentration, 10%) was added to all antibodies. Incubation with primary antibodies (neat culture supernatants) and secondary antibody (horseradish peroxidase–conjugated sheep anti-mouse Ig) was for 1 hour at 4°C in a humidified chamber. Bound conjugate was detected by incubating the section with 0.068% H_2O_2 plus 0.0005 mg/mL diaminobenzidine (Sigma Chemical Co., St. Louis, MO) in 0.05 mol/L tris buffer (pH 7.6) for 10 minutes. The sections were counterstained with Gill's hematoxylin and mounted in DPX neutral mounting medium (Ajax Chemicals, Sydney, Australia).

Combined histochemistry and immunohistochemistry were used to detect mast cells in tissue sections stained with MAb YB5.B8 (anti–c-*kit*), essentially as described previously.[39] Freshly cut frozen sections were fixed immediately in Carnoy's fixative, washed in cold ethanol, and rehydrated in phosphate-buffered saline. Sections were stained with 0.1% alcian blue 8GX (BHD Chemicals Ltd., Poole, England) in 0.7 mol/L HCl for 20 minutes. The sections were rehydrated in phosphate-buffered saline before incubation with antibodies (as described above).

IEL Counts

Counts of total IELs were made on conventional H&E-stained sections of ILFs (5 separate ILFs in the jejunum or the ileum), of LFV (5 separate LFV in the jejunum), and in the FAE of PPs (5 follicles in sections of PPs from jejunum or ileum). The counts were expressed as the number of lymphoid cell nuclei per 100 epithelial cells. In the case of conventional villi, at least 2000 epithelial cells (about 10 villi) were counted.

The relative numbers of IELs stained by individual MAbs in the FAE of PPs and ILFs and in epithelium overlying LFV and adjacent villi were estimated by counts on serial sections using a 40× objective lens. Counts of IELs stained with each MAb were expressed as percentages of the total lymphocyte nuclei in the epithelium.

Statistical Analysis

Results were expressed as mean percent of IELs (or subsets of IELs) in different lymphoid aggregates ± SD. The Student *t* test was used to estimate the significance of differences observed in the frequency of IELs in the epithelium overlying the various lymphoid aggregates and in adjacent villi.

Results

LFV

Approximately 1 per 230 villi in jejunum had a modified structure, with large numbers of lymphocytes packed in the lamina propria. These LFV had a mean diameter (105 μm; equivalent to 21 sections of 5-μm thickness) that was similar to that of classical villi (110

μm; equivalent to 22 sections). LFV did not contain organized follicles (Figure 1), and serial sections showed that they did not extend through the muscularis mucosa at any point. Lymphocytes were most densely packed at the base of LFV and were least dense toward the villus tip and immediately subjacent to the overlying epithelium. HEVs were never observed in these structures. IELs were numerous in LFV and often formed clusters within the epithelium, which also contained fewer goblet cells than epithelium covering adjacent villi. LFV were not detected in the specimens of ileum.

An important feature of cryptopatches[27] and LFV in rodents is that they contain very few B cells. We have, therefore, sectioned LFV serially and stained alternate sections with MAb directed against either CD19 or CD20. Because of the difficulty of identifying the structures in unstained frozen sections, this immunohistochemical study was limited to tissue from a specimen of normal jejunum (case 5) and a specimen from a blind loop of jejunum (case 2). Among the 5 LFV that were examined in the specimen of normal jejunum, no cells were detected that expressed CD19 or CD20 (Figure 2*D*) in 4 villi, and in the fifth villus, occasional CD19-positive lymphocytes were observed in a scattered distribution. B lymphocytes are not, therefore, a prominent component of LFV in normal jejunum, and most LFV do not contain either a cluster or an organized follicle.

In contrast, all LFV examined in sections of mucosa from a blind loop of jejunum contained B cells. The numbers varied from occasional CD19-positive cells in a scattered distribution (Figure 3*A*) (5 LFV) to a small cluster (Figure 3*B*) of CD19- or CD20-positive cells at the base (4 LFV) or a small follicle of stained cells (Figure 3*C*) without a germinal center (one LFV). Although these structures all conformed broadly to the morphological criteria that we have used to define LFV, they appear to be heterogenous with respect to content of B lymphocytes. This may reflect the greater antigenic load expected from an intestinal blind loop. Some of these LFV have similarities to the mucosal variants of ILFs (see below).

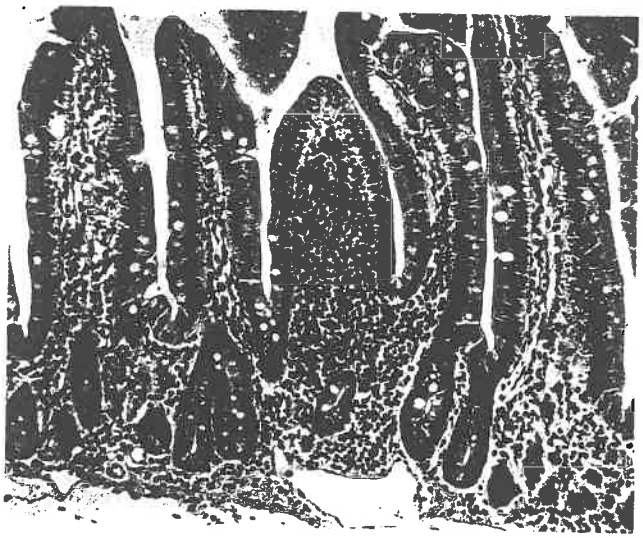

Figure 1. LFV in the jejunal mucosa. The villus is broader than surrounding classical villi, the lamina propria is packed with lymphocytes, and the epithelium contains a greater density of IELs (H&E; original magnification 41×).

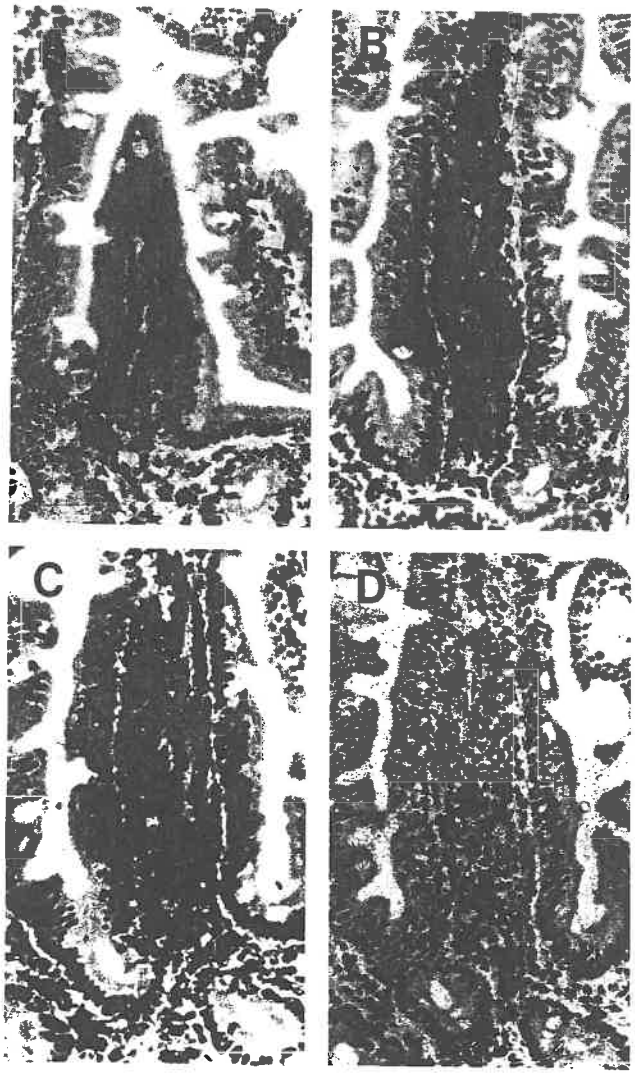

Figure 2. LFV in normal jejunal mucosa. Serial frozen sections were stained with MAbs by the indirect immunoperoxidase technique. (*A*) MAb OKT3 (CD3) showing many T cells in the lamina propria and in the villus epithelium (cf. adjacent villi). (*B*) MAb OKT4 (CD4) showing that most lymphocytes in the lamina propria express CD4, whereas most IELs are unstained. (*C*) MAb UCHL-1 (CD45RO) showing that most T cells in lamina propria and in the villus epithelium are memory cells. (*D*) MAb L26 (CD20) showing that the LFV contains no detectable B cells (original magnification 66×).

The surface antigen phenotypes of other cells in LFV were examined with a panel of MAbs. In the epithelium of LFV, enterocytes in the distal halves of the villi expressed MHC class II molecules (Figure 3*D*). Expression of MHC class II molecules was, therefore, similar in

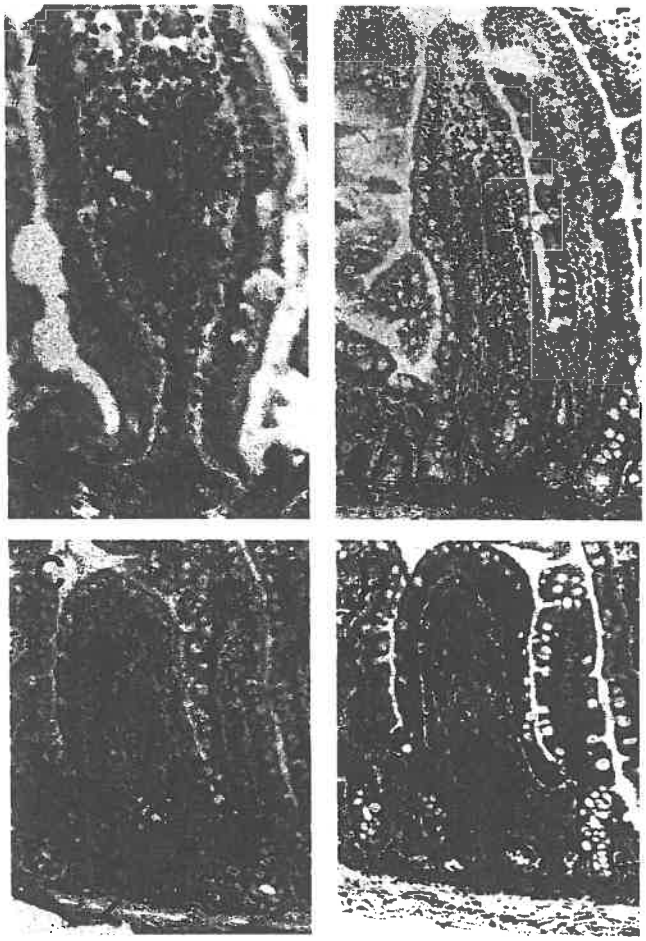

Figure 3. LFV in the mucosa from a jejunal blind loop. (*A–C*) Frozen sections stained with MAb FMC63 (CD19). (*D*) Frozen section from the same structure shown in *C* stained with MAb FMC52 (MHC class II). (*A*) Scattered CD19-positive B cells in the lamina propria (*arrows*). (*B*) A small cluster of B cells at the base of an LFV (*arrow*). (*C*) An LFV with a small B-cell follicle at the base (*arrow*). (*D*) Serial section from *C* showing MHC class II–positive B cells, scattered dendritic cells in the lamina propria, and staining of the overlying epithelium (original magnification: *A*, 66×; and *B–D*, 33×).

LFV and classical villi with respect to distribution, but the level of expression appeared greater in the epithelium of LFV. The phenotypes of IELs in the epithelium of LFV are described below. Within the lamina propria of the LFV, anti–MHC class II stained large cells with irregular morphology (Figure 3*D*). These were located in the subepithelial areas and were scattered also between the lymphocytes in the cores and bases of the villi. They are believed to be dendritic cells.

Most of the lymphocytes in the lamina propria of the LFV expressed CD3 (Figure 2*A*) and staining was similar with MAbs against CD2, CD5, and CD7 (not shown). In those LFV that did not contain B cells, all lymphocytes appeared to be T cells that also expressed the CD45RO splice variant (Figure 2*C*). The majority of the T cells in LFV expressed CD4 (Figure 2*B*), whereas only scattered cells expressed CD8 (not shown). To detect any lymphocytes that resembled immature thymic T cells, LFV were stained with MAbs directed against c-*kit* and CD1a. No cells were detected that expressed CD1a (not shown). Occasional cells that expressed c-*kit* were detected, but dual staining with alcian blue indicated that these were mast cells (not shown). Few, if any, lymphocytes expressed CD25 and only occasional cells expressed CD71. Similar results were obtained irrespective of whether or not LFV had a detectable B-cell component.

PPs

PPs were identified in tissue samples from the ileum (case 1) and jejunum (case 2). The histological and immunohistological appearances (not shown) conformed with published descriptions.[1,11–15] These specimens provided comparisons with the other lymphoid aggregations described in the present study, in particular with respect to IELs associated with the FAE.

ILFs and SLAs

ILFs are structures that resemble LFV most closely. They were therefore examined in detail together with SLAs. ILFs and SLAs were encountered frequently in sections prepared from the 4 specimens of jejunal mucosa and the 2 specimens of ileal mucosa. Counts on sectioned "Swiss rolls" of mucosa indicated a frequency of ILFs of approximately 1 per 269 villi in jejunum and 1 per 28 villi in ileum. ILFs were present in sections of both the mesenteric and antimesenteric portions of the gut circumference. The mean diameter of typical ILFs was considerably larger (250 μm; equivalent to 50 sections of 5-μm thickness) than typical villi (110 μm; equivalent to 22 sections), and they were covered with epithelium that contained frequent IELs and some goblet cells. The lymphoid tissue occupied most of the lamina propria and extended to the muscularis mucosa. In some ILFs, particularly those in the specimen from a blind loop, the central follicle of small lymphocytes contained a germinal center (Figure 4*A*). In only occasional random profiles of ILF did the lymphoid tissue penetrate the superficial layers of the muscularis mucosa.

In most cases, SLAs were located entirely within the muscularis mucosa, and they consisted of loose aggregations of small lymphocytes with no evidence of follicular organization (Figure 4*B*). However, in some instances, SLAs were observed breaching the superficial layers of the muscularis mucosa (Figure 4*C*). When SLAs were sectioned from edge to edge, it was shown in all cases that they were connected to a mucosal lymphoid follicle via a collar-stud-like constriction (Figure 4*D*). SLAs and ILFs are, therefore, parts of a single structure that has both submucosal and mucosal extensions. The mucosal portion

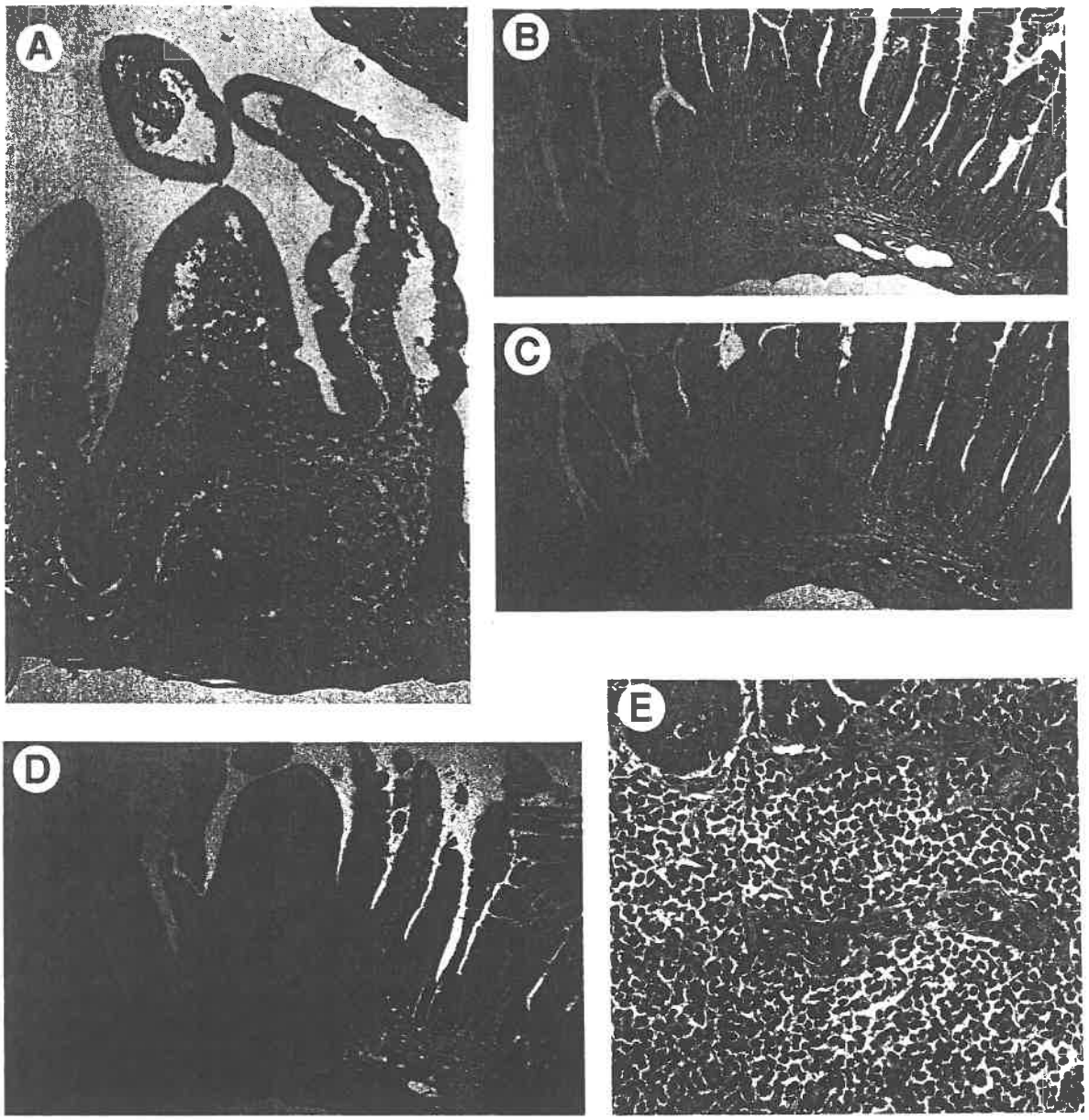

Figure 4. ILFs and SLAs in jejununal mucosa. (*A*) Mucosal variant ILF. The structure contains a small germinal center and, in serial section, did not penetrate the muscularis mucosa. (*B*) A typical SLA lying within the muscularis mucosa. (*C*) In deeper sections through the structure shown in *C*, the muscularis mucosa is reflected, and the lymphoid aggregation extends into the mucosa. (*D*) Serial sections show that the SLA (*C*) is part of the submucosal extension of an ILF containing a germinal center. The submucosal part lies within reflections of the muscularis mucosa. (*E*) Higher-power view of the submucosal part of the ILF shown in *B* and *C*. An HEV is sectioned longitudinally and contains lymphocyte nuclei within the endothelium (H&E; original magnifications, *A*, 41×; *B–D*, 17×; and *E*, 83×).

has morphological similarities to the follicle of a PP. The submucosal part (Figure 4*E*) has vessels resembling HEVs, and it appears to be analogous to the interfollicular areas in PPs.

Sections of ILFs, including the submucosal portions (i.e., the so-called SLAs), were examined immunohistochemically with the panel of MAb. Approximately serial sections are shown in Figure 5. Staining with MAbs against CD19 (Figure 5*A*), CD20 (not shown), and MHC class II (Figure 5*B*) confirmed that the follicles contained mainly B cells. Some B cells were scattered also in the overlying dome region. Many cells in the germinal center expressed the transferrin receptor CD71 (not shown). Germinal center and mantle zone B cells expressed the CD45RA splice variant (Figure 5*C*), whereas the strongly CD45RO-positive cells in the germinal center are believed to be T cells (Figure 5*D*) that also expressed CD4 (Figure 5*F*), CD25 (not shown), and CD3 (not shown). Most lymphocytes in the submucosal portions were stained by MAb directed against T cells. A serial section stained with anti-CD2 is shown in Figure 5*E*, and staining with antibodies against CD3, CD5, and CD7

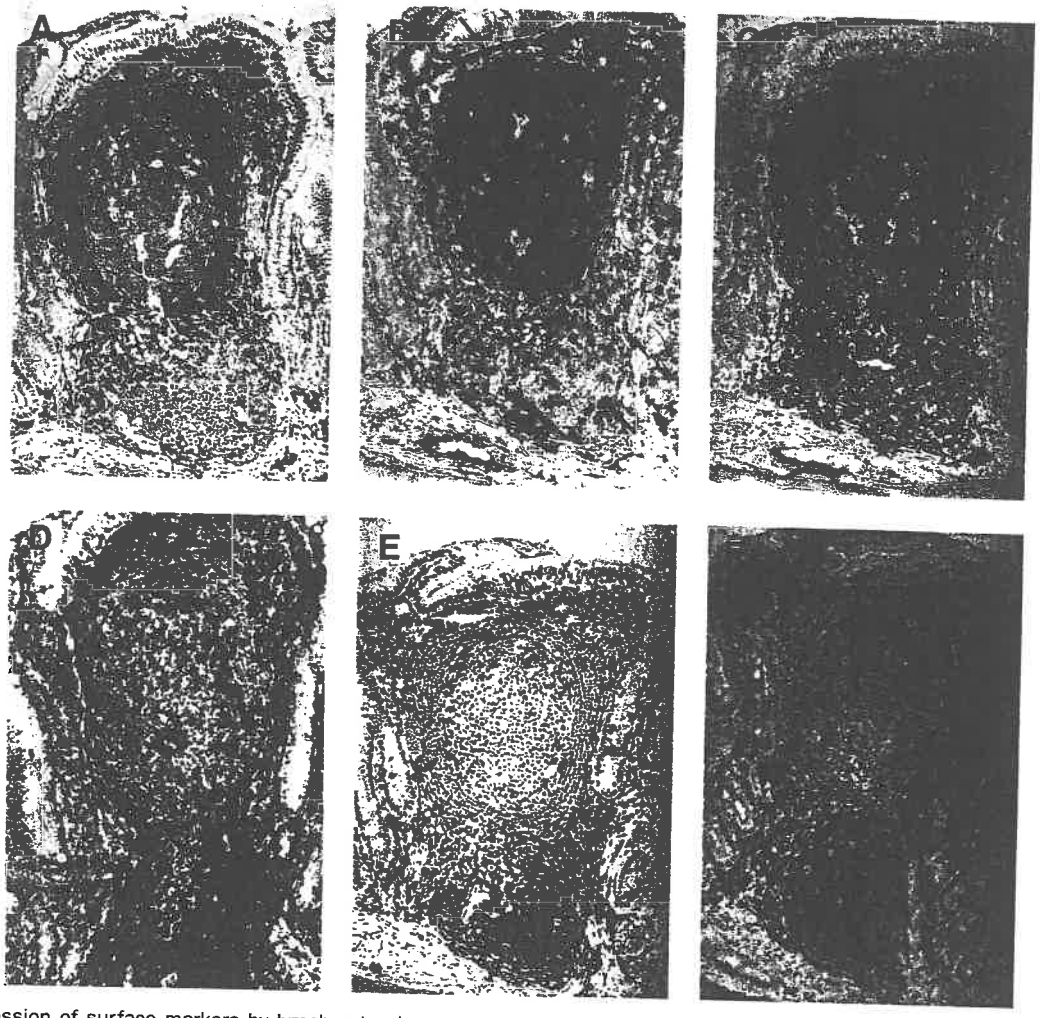

Figure 5. Expression of surface markers by lymphocytes in approximately serial frozen sections from a jejunal ILF detected by the indirect immunoperoxidase technique. Scattered large, densely stained cells are eosinophils containing endogenous peroxidase. (*A*) MAb FMC63 (CD19). B cells in the mantle zone and germinal center of the follicle are stained. Cells in the submucosal extension are mainly unstained. (*B*) MAb FMC52 (MHC class II). B cells in the follicle are stained. Also stained are large dendritic cells in the submucosal extension at the base. (*C*) MAb FMC7 (CD45RA). B cells in the mantle zone and germinal center are stained, as are scattered T cells in the submucosal region. (*D*) MAb UCHL-1 (CD45RO). T cells in the submucosal region are stained, as are scattered T cells in the dome region and in the germinal center. Germinal center B cells are unstained. (*E*) MAb OKT11 (CD2). T cells are stained in the submucosal region and scattered in the dome and germinal center. (*F*) MAb OKT4 (CD4). The distribution of stained cells is similar to the distribution in *E* of T cells expressing CD2 (original magnification 41×).

was similar (not shown). T cells predominated also in the dome beneath the epithelium of the ILFs. The majority of T lymphocytes in both areas expressed the CD45RO splice variant (Figure 5*D*), and scattered cells expressed the activation markers CD25 and CD71 (not shown). Large, irregular cells in both of these T-cell areas expressed MHC class II molecules, and they are believed to be interdigitating dendritic cells (Figure 5*B*). No lymphocytes in ILFs expressed CD1a (not shown), and the small number that expressed c-*kit* in the T-cell areas of ILFs were found to be mast cells (not shown). The results are summarized in Table 3 and a comparison is made with cell populations in LFV.

Typical ILFs are, therefore, different in structure and lymphocyte content than LFV. However, in preparing serial frozen sections of ILFs for immunohistochemical staining, it was observed that there was variability in the degree to which these structures extended into the muscularis mucosa. Some were entirely mucosal (Figure 6*A*), and in others, a few superficial fibers of the muscularis were reflected around the base of the ILF, whereas in typical ILF, the submucosal portion extended deep into the muscularis. Nevertheless, in all cases, the basic structure and distribution of lymphocyte subsets were as described above, although the basal T-cell areas were smaller in the mucosal variants of ILFs and the HEVs were placed laterally, adjacent to the surrounding crypts (Figure 6*B*).

Table 3. Distribution of Lymphocyte Subsets in ILFs and LFV

	Distribution				
	ILFs			LFV	
Antibodies	Germinal center	Mantle zone	Dome and base regions	Normal	Blind loop
Anti-CD19	Most	Most	Scattered	—	Variable
Anti-CD20	Most	Most	Scattered	—	Variable
Anti–MHC-II	Most	Most	Scattered[a]	Scattered[a]	Scattered[a]
Anti-CD45RA	Most	Most	Scattered	—	Variable[b]
Anti-CD45RO	Scattered[c]	Scattered[c]	Most	Most	Most
Anti-CD2	Scattered[c]	Scattered[c]	Most	Most	Most
Anti-CD3	Scattered[c]	Scattered[c]	Most	Most	Most
Anti-CD4	Scattered[c]	Scattered[c]	Most	Most	Most
Anti-CD5	Scattered[c]	Scattered[c]	Most	Most	Most
Anti-CD7	Scattered[c]	Scattered[c]	Most	Most	Most
Anti-CD8	—	—	Scattered	Rare	Rare
Anti-CD25	Scattered[c]	—	Scattered	Scattered	Scattered
Anti-CD71	Most	Most	Scattered	Scattered	Scattered
Anti-CD1a	—	—	—	Scattered[a]	Scattered[a]
Anti–c-*kit*	—	—	Scattered[d]	Rare[d]	Rare[d]

MHC, major histocompatibility complex.
[a]Interdigitating cells and occasional B cells.
[b]B cells.
[c]T cells.
[d]Mast cells.

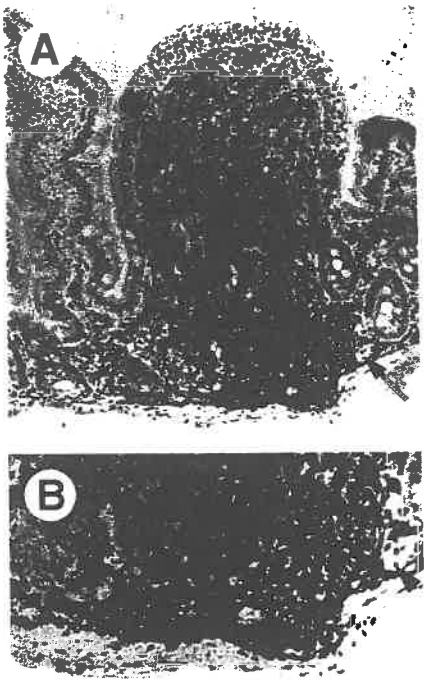

Figure 6. Frozen section from a mucosal variant ILF in the jejunal mucosa. (*A*) Staining with MAb FMC7 (CD45RA) shows a small follicle of B cells containing a germinal center near the base (confirmed in serial section stained to show CD19). This section passes through two HEVs (*arrows*). (*B*) Higher-power view of the base of the follicle showing the HEVs (*arrows*) (original magnifications: *A*, 33×; and *B*, 66×).

IELs in the Epithelium Covering LFV and ILFs

There appeared to be larger numbers of IELs in the epithelium covering LFV and ILFs than in the epithelium of adjacent villi. Furthermore, IELs in the epithelium of ILFs and LFV were distributed at all levels, similar to the distribution of IELs in the FAE overlying PPs. The results of counts (Table 4) indicate that IELs are more frequent in the epithelium of classical villi in the jejunum than in the ileum and that their numbers are significantly greater ($P < 0.005$) in the epithelium overlying ILFs, LFV, and PPs than in the epithelium covering surrounding classical villi.

Most of the IELs in the epithelium overlying LFV and in the FAE of ILFs and PPs were T cells that were stained by MAbs directed against CD3 and CD7 (Table 4). The proportions of T lymphocytes in the epithelium of LFV and in the FAE of jejunal PPs were similar (92%) but significantly lower ($P < 0.005$) than the proportions observed in either classical villi or ILFs from the same region (99% vs. 97%). However, the IELs in the epithelium of LFV differed from those in the FAE of jejunal PPs in expression of the CD45RA splice variant (0% vs. 29%) and from IELs in jejunal ILFs (0% vs. 5%). The IELs in LFV contained a greater proportion of $CD4^+$ T cells (30%) than was found in classical jejunal villi (11%) but a smaller proportion than was found in

Table 4. Numbers and Surface Antigen Markers of IELs in Classical Villi and the Lymphoepithelium Overlying Various Mucosal Lymphoid Structures in the Small Intestine

Tissue	Total IELs[a]	Percentage of labeled IELs[b]						
		CD3+	CD7+	CD4+	CD8+	CD45RO+	CD45RA+	CD19+
Jejunum								
ILFs	42.3 ± 4.7	97.0 ± 2.5	95.9 ± 2.8	37.1 ± 5.4	79.5 ± 10.5	98.3 ± 1.8	4.6 ± 5.6	1.2 ± 1.2
LFV	46.0 ± 4.7	91.7 ± 6.6	94.8 ± 7.9	30.2 ± 10.2	72.8 ± 15.7	95.7 ± 5.3	0	0
PPs	44.9 ± 4.2	92.0 ± 3.3	90.6 ± 1.2	38.6 ± 8.9	66.2 ± 5.9	93.7 ± 0.2	29.4 ± 13.3	12.3 ± 0.3
Classical villi	25.9 ± 4.5	98.6 ± 0.8	93.3 ± 1.5	11.1 ± 4.4	95.4 ± 3.7	98.9 ± 1.3	0.2 ± 0.4	0.6 ± 1.3
Ileum[c]								
ILFs	29.5 ± 4.8	86.5 ± 6.0	89.4 ± 3.2	11.0 ± 11.5	78.4 ± 6.9	83.4 ± 8.3	8.4 ± 4.9	1.1 ± 2.3
PPs	33.6 ± 8.1	68.2 ± 4.8	70.3 ± 5.2	17.8 ± 6.2	62.5 ± 7.9	89.8 ± 4.3	29.5 ± 7.8	11.0 ± 8.1
Classical villi	11.4 ± 2.4	84.0 ± 3.8	88.7 ± 4.1	1.7 ± 2.3	86.9 ± 5.2	87.1 ± 7.1	4.1 ± 2.8	0.7 ± 2.1

[a]Means of total IELs per 100 epithelial cells calculated from 5 ILFs, 5 LFV, and 5 PP follicles or 10 classical villi in H&E-stained sections.
[b]Means of differential counts for each marker calculated from 5 ILFs, 5 LFV, and 5 PP follicles or 10 classical villi in frozen sections.
[c]LFV were not observed in specimens of ileum.

the FAE of either jejunal ILFs (37%) or jejunal PPs (39%).

IELs in LFV were, therefore, distinct in number and composition from those in jejunal classical villi and in the FAE of jejunal ILFs and PPs. These differences were magnified when compared with ileum, where the proportion of T cells was lower in classical villi (84%) and ILFs (87%) and lowest in the FAE of PPs (68%). A further difference between the epithelial compartments of LFV and those of the other structures was the absence of any B cells. However, a common feature of IELs in all of the structures was absence of expression of CD1a, CD25, CD71, and c-*kit*.

Discussion

This histological and immunohistological study of the mucosa of the human small intestine was undertaken to search for novel lymphoid structures similar to those described as cryptopatches in mice[27] and LFV in both rats[28] and mice (M. Moghaddami and G. Mayrhofer, unpublished data, June 1995). In both species, structures of this sort are solitary, and they differ from PPs further by containing a majority of lymphocytes that express neither surface Ig nor the T-cell receptor. Because cryptopatches and rodent LFV contain few or no B cells and a small number of T cells and they are present in athymic (nude) mice and rats, it has been suggested that they may be specialized sites that support primary T-cell differentiation. Our studies have been directed, therefore, toward solitary lymphoid tissues in the human small bowel mucosa.

ILF and SLA are the two solitary lymphoid structures that have been described previously in human small intestine,[21] but neither has been investigated thoroughly with respect to structure, lymphocyte composition, or function. We have shown that SLAs are in all cases submucosal extensions from an overlying ILF. The term ILF is, therefore, sufficient to describe the complete structure. The typical ILF is similar to the follicular units that compose PP. Variants of the typical ILF have also been observed. These are either confined completely to the mucosa, or they may erode the superficial fibers of the muscularis mucosa. In most cases, the follicles in these mucosal variants did not contain a germinal center, suggesting that they are relatively inactive under normal circumstances. However, those observed in the tissue from a blind loop contained a germinal center, suggesting that variant ILF can be activated under circumstances of microbial colonization of the small intestine. Typical ILF and the mucosal variants both contained HEVs and are presumably sites of lymphocyte recirculation.

The immunohistochemical findings support the conclusion that typical ILFs and their mucosal variants are secondary lymphoid tissues. In both cases, they contain a follicle that consists of B lymphocytes. The subepithelial tissue overlying the follicle in ILFs contains mainly CD45RO$^+$ T lymphocytes, interspersed with dendritic cells that express MHC class II molecules. This area resembles the corona region of follicles in PPs, whereas the increased frequency of both total IELs and CD4$^+$ IELs in the overlying epithelium is similar to that described in other FAEs.[14,15,40] The basal region of variant mucosal ILFs consists mainly of CD45RO$^+$ T lymphocytes with interspersed MHC class II–positive interdigitating cells. MAbs that detect immature T-cell populations in the thymus (anti-CD1a, anti-CD25, and anti–c-*kit*) labeled few or no lymphocytes in ILFs.

The morphological findings and the immunohistochemical evidence suggests that ILFs are similar to PPs. It is interesting to speculate that ILFs may represent a reserve of mucosal lymphoid tissue that can be activated under conditions of increased mucosal antigenic drive. In particular, the mucosal variants of ILFs appear to be

relatively quiescent and unobtrusive under normal circumstances. The appearance of activation, with germinal center formation, in the ILFs from a blind loop suggests that microbial colonization of the gut lumen may induce hypertrophy of these tissues. It is noteworthy that ILFs are reported to be more frequent in duodenitis[41] and infectious hepatitis,[42] whereas nodular lymphoid hyperplasia in the small intestine has been reported in association with hypogammaglobulinemia[43] and with carcinoma of the cecum.[23] These conditions may all be associated with colonization of the small intestine by bacteria and other microorganisms, and the lymphoid hyperplasia may reflect a pathophysiological response by this scattered reserve of organized mucosal lymphoid tissue. A similar process might bring to macroscopic prominence clusters of rudimentary follicles and explain the puzzling observation by Cornes[9] that the number of PPs in human intestine increases during childhood.

The third solitary lymphoid aggregation described in this study has been designated an LFV because it resembles superficially the LFV that we have observed in the rodent small intestine. LFV in the human small intestine were confined to the jejunum, where they had dimensions similar to classical villi. The morphological features that distinguish LFV from classical villi are the presence of tightly packed lymphocytes that fill most of the lamina propria and a higher concentration of IELs in the overlying epithelium. The IELs in the epithelium of LFV are enriched for T lymphocytes that express CD4, and often they are found in clusters. These findings suggest that the epithelium of LFV is similar to the FAE overlying PPs and ILFs and that, as in PPs, there may be M cells that envelop clusters of lymphoid cells. However, a difference from the FAE of both PPs and ILFs is the complete absence of IELs that express the CD45RA splice variant from the epithelium overlying LFV. There are also important structural differences between LFV and ILFs. In particular, the former lack HEVs and do not have obvious lymphoid follicles.

The immunohistochemical studies indicate that the LFV in humans are heterogeneous with respect to cellular composition. In all cases (15 LFV in total), the majority of lymphocytes in the lamina propria were T cells that expressed the CD45RO splice variant (memory phenotype). The subepithelial region of the LFV contained large, irregular cells that expressed MHC class II antigens, and these cells also ramified between the lymphocytes in the central lamina propria. These dendritic cells, some of which expressed CD1a, are similar to those observed in the domes of PP follicles and ILFs. The lymphocytes in LFV did not express CD1a or c-*kit,* and only rare cells expressed CD25. Although a subpopulation of lymphocytes in human thymus expresses CD45RO,[44] the absence of other markers that are expressed early in the differentiation of T lymphocytes suggests strongly that the cells expressing CD45RO in LFV are memory cells and that LFV in adult humans are not the functional homologues of LFV in mice and rats.

A further distinction between LFV in humans and in laboratory rodents is the presence in the human structures of a variable number of B lymphocytes. Of 5 LFV sectioned serially from a segment of normal jejunum, only 1 contained a few scattered CD19-positive cells, and the remaining 4 LFV sectioned from this specimen contained either no B lymphocytes or rare stained cells. Ten LFV were sectioned serially in tissue obtained from a blind loop of jejunum. Of these, 1 contained a small follicle of CD19-positive cells near the base (without a germinal center), 4 contained a small cluster of cells expressing CD19 or CD20, and the remaining 5 contained scattered CD19-positive cells.

Together, the histological and immunohistological findings suggest that LFV are distinct anatomic entities. It could be argued that they are reactions to chronic inflammation. However, LFV lie invariably adjacent to mucosal villi that do not have either increased numbers of IELs in the overlying epithelium or infiltration of the lamina propria with mononuclear cells. Large MHC class II–positive cells, which in adjacent villi were fewer in number and located mainly in the tips of the villi, in LFV were scattered throughout the villus. Furthermore, the ratio of CD4-positive to CD8-positive IELs was different in LFV and classical villi, and more similar to the ratio observed in the FAE of PPs and ILFs. Furthermore, the clustering of the IELs in the epithelium of LFV suggests that it is specialized and that it may contain microfold cells. These relatively specific features of LFV suggest that they are not the result of inflammation and that they may be laid down developmentally.

The lymphocyte composition of LFV suggests that their physiological functions in adult humans are related principally to the presentation of antigens to T lymphocytes of the memory phenotype. The antigens involved could be transported through a specialized epithelium and processed by the many dendritic cells in the LFV. The origin of the T cells in LFV is unknown, but the absence of HEVs in these structures suggests that they are not important sites of lymphocyte recirculation. It appears that B lymphocytes can be recruited into LFV under some conditions. Increased antigenic drive may be a factor, because we observed the presence of B-cell clusters and rudimentary follicles in some LFV from a blind loop. It seems possible, therefore, that those LFV with a B-cell complement are part of a continuum (at least under

pathological circumstances) that merges through mucosal variants of ILFs with typical ILFs. In the absence of evidence that LFV in adult humans are primary lymphoid organs, it appears likely that, together with PPs and ILFs, they are components of the gut-associated secondary lymphoid tissues. It remains to be seen whether each component has a specialized function[45–47] or whether with appropriate antigenic stimulation they can all take on the characteristics observed in the ILFs from the blind loop with the development of follicles and germinal centers. If this model is correct, LFV and ILFs could contribute to the pathology of diffuse lymphoid hyperplasia in the gut and to the spread of mucosal lymphomas.

References

1. Keren DF. Structure and function of the immunologic system of the gastrointestinal tract. In: Ming SC, Goldman H, eds. Pathology of the gastrointestinal tract. Philadelphia: Saunders, 1992: 69–80.
2. Lefrancois L, Pudding L. Extrathymic intestinal T-cell development: virtual reality. Immunol Today 1995;16:16–21.
3. Rocha B, Guy-Grand D, Vassalli P. Extrathymic T cell differentiation. Curr Opin Immunol 1995;7:235–242.
4. Lynch S, Kelleher D, McManus R, O'Farrelly C. RAG-1 and RAG-2 expression in human intestinal epithelium: evidence of extrathymic T cell differentiation. Eur J Immunol 1995;25:1143–1147.
5. Latthe M, Terry L, MacDonald TT. High frequency of CD8αα homodimer-bearing T cells in human fetal intestine. Eur J Immunol 1994;24:1703–1705.
6. Lundqvist C, Baranov V, Hammarström S, Athlin L, Hammarström ML. Intra-epithelial lymphocytes. Evidence for regional specialization and extrathymic T cell maturation in the human gut epithelium. Int Immunol 1995;7:1473–1487.
7. Guy-Grand D, Cerf-Bensussan N, Malissen B, Malassis-Seris M, Briottet C, Vassalli P. Two gut intraepithelial CD8+ lymphocyte populations with different T-cell receptors: a role for the gut epithelium in T-cell differentiation. J Exp Med 1991;173:471–481.
8. Guy-Grand D, Vanden Broecke C, Briottet C, Malassis-Seris M, Selz F, Vassalli P. Different expression of the recombination activity gene RAG-1 in various populations of thymocytes, peripheral T cells and gut thymus-independent intraepithelial lymphocytes suggests two pathways of T cell receptor rearrangement. Eur J Immunol 1992;22:505–510.
9. Cornes JS. Number, size, and distribution of Peyer's patches in the human small intestine. Gut 1965;6:225–229.
10. Cornes JS. The effect of age on Peyer's patches. Gut 1965;6:230–233.
11. Spencer J, MacDonald TT, Fin T, Isaacson PG. The development of gut associated lymphoid tissue in the terminal ileum of fetal human intestine. Clin Exp Immunol 1986;64:536–543.
12. Owen RL, Jones AL. Epithelial cell specialization within human Peyer's patches: an ultrastructural study of intestinal lymphoid follicles. Gastroenterology 1974;66:189–203.
13. Spencer J, Finn T, Isaacson PG. Human Peyer's patches: an immunohistochemical study. Gut 1986;27:405–410.
14. Bjerke K, Brandtzaeg P, Fausa O. T cell distribution is different in follicle-associated epithelium of human Peyer's patches and villous epithelium. Clin Exp Immunol 1988;74:270–275.
15. Brandtzaeg P, Bjerke K. Immunomorphological characteristics of human Peyer's patches. Digestion 1990;46(Suppl 2):262–273.
16. Farstad IN, Halstensen TS, Fausa O, Brandtzaeg P. Do human Peyer's patches contribute to the intestinal intraepithelial γ/δ T-cell population? Scand J Immunol 1993;38:451–458.
17. Owen RL, Apple RT, Bhalla DK. Morphometric and cytochemical analysis of lysosomes in rat Peyer's patch follicle epithelium: their reduction in volume fraction and acid phosphatase content in M cells compared to adjacent enterocytes. Anat Rec 1986;216: 521–527.
18. Fujimura Y, Kihara T, Ohtani K, Kamoi R, Kato T, Kozuka K, Miyashima N, Uchida J. Distribution of microfold cells (M cells) in human follicle-associated epithelium. Gastroenterol Jpn 1990;25: 130.
19. Owen RL. Sequential uptake of horseradish peroxidase by lymphoid follicle epithelium of Peyer's patches in the normal unobstructed mouse intestine: an ultrastructural study. Gastroenterology 1977;72:440–451.
20. Wolf JL, Rubin DH, Finberg R, Kauffman RS, Sharpe AH, Trier JS, Fields BN. Intestinal M cells: a pathway for entry of reovirus into the host. Science 1981;212:471–472.
21. Morson BC, Dawson IMP. Gastrointestinal pathology. 2nd ed. Oxford, England: Blackwell Scientific, 1979.
22. Shorter RG, Tomasi TB. Immune mechanisms in the small intestine: part I. In: Chadwick VS, Phillips SF, eds. Gastroenterology 2. London: Butterworth Scientific, 1982:73–79.
23. Whitehead R. Mucosal biopsy of the gastrointestinal tract. 4th ed. Philadelphia: Saunders, 1990.
24. Price AB. Small intestinal biopsy. In: Booth CC, Neale G, eds. Disorders of the small intestine. Oxford, England: Blackwell Scientific, 1985:12–21.
25. Mayrhofer G. Physiology of the intestinal immune system. In: Newby TJ, Stokes CR, eds. Local immune responses of the gut. Boca Raton, FL: CRC, 1984:1–96.
26. Rosner AJ, Keren DF. Demonstration of M cells in the specialized follicle-associated epithelium overlying isolated lymphoid follicles in the gut. J Leukoc Biol 1984;35:397–404.
27. Kanamori Y, Ishimaru K, Nanno M, Maki K, Ikuta K, Nariucki H. Identification of novel lymphoid tissues in murine intestinal mucosa where clusters of c-kit+ IL7-R+ Thy1+ lympho-hemopoietic progenitors develop. J Exp Med 1996;184:1449–1459.
28. Mayrhofer G, Brooks A. Lymphopoiesis in lymphocyte-filled villi in the small intestine of the rat. Clin Immunol Immunopathol 1995;76:S55.
29. Mayrhofer G, Pugh CW, Barclay AN. The distribution, ontogeny and origin in the rat of Ia-positive cells with dendritic morphology and of Ia antigen in epithelia with special reference to the intestine. Eur J Immunol 1983;13:112–122.
30. Mayrhofer G, Spargo LDJ. Subcellular distribution of class II major histocompatibility antigens in enterocytes of the human and rat small intestine. Immunol Cell Biol 1989;67:251–260.
31. Zola H, Macardle PJ, Flego L, Webster J. The expression of sub-population markers on B cells: a re-evaluation using high-sensitivity fluorescence flow cytometry. Dis Markers 1991;9:103–118.
32. Knapp W, Dörken B, Gilks WR, Rieber EP, Schmidt RE, Stein H, von dem Borne AEGK. Leucocyte typing IV. White cell differentiation antigens. Oxford, England: Oxford University, 1989.
33. Zola H, Macardle PJ, Bradford T, Weedon H, Yasui H, Kurosawa Y. Preparation and characterization of a chimeric CD19 monoclonal antibody. Immunol Cell Biol 1991;69:411–422.
34. Petruch UR, Horny HP, Kaiserling E. Frequent expression of haemopoietic and non-haemopoietic antigens by neoplastic plasma cells: an immunohistochemical study using formalin-fixed, paraffin-embedded tissue. Histopathology 1992;20: 35–40.
35. Ferro LM, Zola H. Modulation of expression of the antigen identified by FMC-7 upon human B-lymphocyte activation: evidence for differences between activation in vivo and in vitro. Immunology 1990;69:373–378.

36. Smith SH, Brown MH, Rowe D, Callard RE, Beverley PC. Functional subsets of human helper-inducer cells defined by a new monoclonal antibody UCHL-1. Immunology 1986;58:63–70.
37. Ashman LK, Buhring HJ, Aylett GW, Broudy VC, Muller C. Epitope mapping and functional studies with three monoclonal antibodies to the c-kit receptor tyrosine kinase, YB5.B8, 17F11, and SR-1. J Cell Physiol 1994;158:545–554.
38. Zola H, Barclay S, Furness V, Macardle PJ, Neoh SH, Bradley J. B lymphocyte/carcinoma antigen (BLCa): functional study in B cells. Immunol Cell Biol 1988;66:199–208.
39. Mayrhofer G, Gadd SJ, Spargo LDJ, Ashman LK. Specificity of a mouse monoclonal antibody raised against acute myeloid leukaemia cells for mast cells in human mucosal and connective tissues. Immunol Cell Biol 1987;65:241–250.
40. Rowinski J, Lamprecht J, Sicinski P. Non-random distribution of intraepithelial lymphoid cells in follicle-associated epithelium of Peyer's patches in mice. J Anat 1984;139:21–32.
41. Whitehead R, Roca M, Meikle DD, Skinner J, Truelove SC. The histological classification of duodenitis in fibreoptic biopsy specimens. Digestion 1975;13:129–136.
42. Astaldi G, Airo R, Conrad ME, Penna R, Ceretto F. Lymphatic follicles and immunologic cell reaction in human jejunal mucosa obtained by peroral biopsy in infectious hepatitis. Adv Exp Med Biol 1969;5:473–482.
43. Ajdukiewicz AB, Youngs GR, Bouchier IAD. Nodular lymphoid hyperplasia with hypogammaglobulinaemia. Gut 1972;13:589–595.
44. Pilarski LM, Gillitzer R, Zola H, Shortman K, Scollay R. Definition of the thymic generative lineage by selective expression of high molecular weight isoforms of CD45 (T200). Eur J Immunol 1989;19:589–597.
45. Heatley RV, Stark JM, Horsewood P, Bandouvas E, Cole F, Bienenstock J. The effects of surgical removal of Peyer's patches in the rat on systemic antibody responses to intestinal antigen. Immunology 1981;44:543–548.
46. Hamilton SR, Keren DF, Yardley JH, Brown G. No impairment of local intestinal immune response to keyhold limpet hemocyanin in the absence of Peyer's patches. Immunology 1981;42:431–435.
47. Serizawa H, Miura S, Tashiro H, Imaeda H, Shiozaki H, Tanaka S, Yoshioka M, Ohara M, Hibi T, Yamashita A, Tsuchiya M. Significant changes in intestinal lymphatic system and immune response elicited by Peyer's patch excision in adult rats. J Gastroenterol Hepatol 1993;8:63–69.

Received July 28, 1997. Accepted August 31, 1998.

Address requests for reprints to: Graham Mayrhofer, BM.Bch., D. Phil., Department of Microbiology and Immunology, University of Adelaide, Adelaide, South Australia 5005, Australia. e-mail: gmayrhof@microb.adelaide.edu.au; fax: (61) 8-8303-4362.

Supported by Grant 920088 from the National Health and Medical Research Council of Australia.

09PH
M6959
c.2

UNIVERSITY OF ADELAIDE
14/9/99
LIBRARY

considerably from meal to meal. Unfortunately, we know fairly well how products of digestion are absorbed but little about how specific foods interact with the human gut and their sensory apparatus (conscious and unconscious). Indeed, some patients relate their customary symptoms to certain foods or food mixtures, whereas other patients indicate no clear influence of meal size or composition. Given such paucity of basic information, it is not that surprising that we cannot yet focus on what makes a particular meal provoke symptoms in a particular patient. Nevertheless, it would be truly astonishing if the mechanical aspects of digestion turned out to be the sole or even the primary provoking factor in every dyspeptic patient, to the exclusion of other meal characteristics.

One thing appears certain: the search for medical solutions to dyspepsia must continue because society demands it. Because we do not know the right path, all approaches are legitimate as long as they are founded on solid scientific and ethical principles, whether the research involves symptom analysis, physiological studies, or empiric therapeutic trials. Studies that attempt to integrate symptom data and physiological data, as exemplified by Tack et al., are particularly appealing because, notwithstanding the caveats and limitations outlined above, this type of study at least conjoins two key elements of the problem: patient's complaints and altered physiology. Perhaps continuing efforts along this path will eventually yield both the scientific answer and the practical solution. Serendipity might help too.

JUAN-R. MALAGELADA
Digestive System Research Unit
Hospital General Vall d'Hebron
Autonomous University of Barcelona
Barcelona, Spain

References

1. Tack J, Piessevaux H, Coulie B, Caenepeel P, Janssens J. Role of impaired gastric accommodation to a meal in functional dyspepsia. Gastroenterology 1998;115:1346–1352.
2. Piessevaux H, Tack J, Coulie B, Genbel A, Janssens J. Influence of erythromycin on the perception of gastric distension (abstr). Gastroenterology 1998;112:A806.
3. Jain NK, Boivin M, Zinsmeister AR, Brown ML, Malagelada J-R, DiMagno EP. Effect of ileal perfusion of carbohydrates and amylase inhibitor on gastrointestinal hormones and emptying. Gastroenterology, 1989;96:377–387.
4. Feinle C, D'Amato M, Read NW. Cholecystokinin A receptors modulate gastric sensory and motor responses to gastric distension and duodenal lipid. Gastroenterology 1996;110:1379–1385.
5. Read NW, MacFarlane A, Kinsman RI. Effect of infusion of nutrient solutions into the ileum on gastrointestinal transit and plasma levels of neurotensin and enteroglucagon. Gastroenterology 1984; 86:274–280.
6. Houghton LA, Fowler P, Keene ON, Read NW. Effect of sumatriptan, a new selective 5HT1-like agonist, on liquid gastric emptying in man. Aliment Pharmacol Ther 1992;6:685–691.
7. Thumshirn M, Burton DD, Zinsmeister AR, Camilleri M. Modulation of gastric sensory and motor functions by nitrergic and α_2-adrenergic agents (abstr). Gastroenterology 1997;112:A837.
8. Troncon LE, Thompson DG, Ahluwalia NK, Barlow J, Heggie L. Relations between upper abdominal symptoms and gastric distension abnormalities in dysmotility like functional dyspepsia after vagotomy. Gut 1995;37:17–22.
9. Notivol R, Coffin B, Azpiroz F, Mearin F, Serra J, Malagelada J-R. Gastric tone determines the sensitivity of the stomach to distension. Gastroenterology 1995;108:330–336.
10. Talley NJ, Colin-Jones D, Koch KL, Nyren O, Stanghellini V. Functional dyspepsia: a classification with guidelines for diagnosis and management. Gastroenterol Int 1990;3:159–172.

Address requests for reprints to: Juan-R. Malagelada, M.D., Digestive System Research Unit, Hospital General Vall d'Hebron, Pg. Vall d'Hebron, 119-129, 08035 Barcelona, Spain. Fax: (34) 93-209-6205.

© 1998 by the American Gastroenterological Association
0016-5085/98/$3.00

Anatomy of T-Cell Development in the Intestine

See article on page 1414.

The possibility that the intestine can act as a primary lymphoid organ has a long history in immunology.[1] It is known that the intestinal mucosa is involved in B-lymphocyte production as a component of hematopoiesis, at least in some species. The bursa of Fabricius in chickens and the ileal Peyer's patches in sheep are examples of intestinal mucosal sites responsible for primary B-cell generation.[2] The question in recent years, fueled by the advent of tools for analysis of T-cell subsets and molecular aspects of T-cell receptor biogenesis, has become whether a mucosal counterpart of the bursa exists for T-cell development.[3] An evolutionary argument can be made that gut-associated lymphoid tissue developed before the appearance of more organized primary lymphoid tissues,[4] and so the development of parallel pathways of mucosal T- and B-cell development may also have occurred.

In the mouse, extrathymic development of intestinal intraepithelial T lymphocytes (IELs) has been studied

extensively.[5] IELs in most species are made up of T-cell receptor (TCR) αβ T cells and a significant complement of TCRγδ T cells,[6] unlike most other secondary lymphoid tissues in which TCRγδ cells make up only a minor population of total T cells. The most recent data suggest that extrathymic T-cell development of mouse and perhaps human TCRγδ IELs is possible,[7,8] whereas certain subsets of TCRαβ IELs ($CD4^+$ and $CD8\beta^+$) are exclusively thymus-derived under normal circumstances.[7,9] If ontogeny recapitulates phylogeny in this case, because TCRγδ cells develop first embryonically,[10] then perhaps at least a subset of TCRγδ cells are vestiges of primitive components of the innate immune system. Indeed, their development and function within the intestine could have been preserved during evolution as a consequence of the conservation of the gut microenvironment. In addition, under experimental conditions such as when irradiation is used to generate mouse bone marrow chimeras, extrathymic maturation of TCRαβ IEL development is also induced.[11–14] The question then becomes whether extrathymic development can supplant thymic TCRαβ cell production during times of stress, thymic involution, aging, etc.

To generate T cells outside of the thymus, certain molecular constraints need to be considered. These include the functional expression of genes involved in TCR rearrangement such as the recombinase activating genes (RAG-1,2) and terminal deoxynucleotide transferase (TdT).[15,16] Certain cytokines such as interleukin (IL)-7 and stem cell factor are also requisite for normal T-cell development.[17] With regard to TCRαβ T cells, major histocompatibility molecules are required for positive selection whether the cells are made in the thymus or elsewhere.[18,19] Thus, without these essential factors, T-cell development will not occur; any model of extrathymic T-cell development at any site must take these issues into account.

The intestinal epithelium has been proposed as a potential site of extrathymic T-cell development for several reasons. By analogy with the thymus, epithelial cell–T cell precursor interactions may be required for extrathymic T-cell development and selection. In addition, intestinal epithelial cells (IECs) produce stem cell factor and IL-7,[20,21] two cytokines intimately involved in early T-cell development; in theory, IECs could therefore direct T lymphopoiesis.

In this issue of GASTROENTEROLOGY, Moghaddami et al.[22] describe an anatomic structure in the human intestinal mucosa they termed "lymphocyte-filled villi (LFV)." This group previously identified a similar structure in the rat intestine.[23] However, the cellular contents of these structures in the two species are remarkably different. LFV become detectable at ~2 weeks after birth in the rat and at this time contain $CD3^-$, $B220^-$ lymphoid cells. After ~3 weeks of life, a subset of cells in the LFV are TCRαβ $CD4^+$ cells. Proliferating cells in the LFV are TCR^- and located in the base of the villi, suggesting that perhaps such cells could be precursors to TCR^+ cells. In contrast, human LFV apparently contain only mature T and B cells, the latter not usually being organized into follicular structures. LFV are characterized by a lamina propria packed with lymphocytes and an increased number of IELs in the overlying epithelium, primarily of the CD4 type.

These results suggest that human LFV are not sites of extrathymic T-cell development. One potential problem with the analysis of human intestine in this study is that only adult human tissue was examined. Therefore, if some early extrathymic development occurs in specialized structures, these may not be present in adult. Indeed, there is evidence that extrathymic T-cell development may occur in fetal and neonatal human intestinal mucosa.[24,25] The lack of potential precursors in LFV or in the other lymphoid aggregations described suggests that if extrathymic T-cell development occurs in the human intestine, then it does not occur in organized tissue and the necessary precursors reside elsewhere. It should be kept in mind that extrathymic development of intestinal T-cell precursors could occur at sites distal to the intestine, such as the bone marrow, where B-cell development takes place and where all of the known required stromal factors are expressed. LFV epithelium may be akin to the follicle-associated epithelium of Peyer's patches and, as such, should contain M cells, although this has yet to be tested. Because LFV contain no clear follicles, their possible function as a site of antigen presentation, at least to naive B cells, is unlikely. Whether primary T-cell activation occurs here or LFV are formed in response to some as yet uncharacterized pathogenic stimuli remains unclear, although the latter is not supported by the data, as discussed by the investigators. LFV contain scattered large major histocompatibility class II–positive cells and could therefore be sites of T-cell activation in the mucosa.

The study by Moghaddami et al. may be of more interest for what is not detected in the human intestine than for the thorough analysis of the detectable structures. No obvious structures that contained hematopoietic precursors were identified. A novel anatomic structure recently identified in the mouse intestinal mucosa was apparently not found in the human mucosa in the current study by Moghaddami et al. These structures, termed cryptopatches (CPs), are located in the lamina propria of the intestinal crypt.[26,27] Each CP contains

~1000 lymphoid cells that express c-*Kit* and IL-7 receptor and are not mature T or B cells. There are ~1500 CPs per intestine, and they are found in small and large intestine but not in stomach. Of interest with regard to lymphocyte development is the finding that CPs are present in nude mice and RAG-deficient mice, indicating that the lymphoid cells present in CPs do not require a thymus or antigen-receptor gene rearrangement for their development.[26] However, CPs are greatly decreased in number and size in IL-7 receptor α–deficient mice. Such mice are severely immunodeficient because IL-7 is required during the early stages of T- and B-cell development. This result suggests that IL-7 is needed for either the generation of the lymphoid CP cells and/or for the formation of the CP structure.

Are CPs the site of extrathymic T-cell development? CP cells do not express RAG[26]; if CP cells are T-cell precursors, then they must complete their maturation elsewhere or are maturing at a very slow rate, undetectable by histological examination. Similarly, cells in rat LFV also do not express RAG, again indicating that TCR rearrangement may occur elsewhere if LFV are T-cell generative sites. The question of whether CP cells are T-cell precursors was addressed either by grafting CP-containing tissue or by purification of CP cells and transfer to irradiated severe combined immunodeficient disease recipients.[27] Both TCRγδ and TCRαβ IELs were generated from CP cells 3–4 weeks after CP cell transfer. Curiously, mesenteric lymph node TCRαβ cells were also generated. A small number of $CD3^+$ cells were present in spleen and thymus. One potential problem with these studies is that the recipient mice were not thymectomized, therefore not allowing an unequivocal assessment of the role of the thymus in development of T cells from CP cells. Nevertheless, if the CP is a site where T-cell precursors destined for the extrathymic pathway reside, why is there no similar structure in humans? As discussed above, one answer may lie in the time points examined in the present human study. It is possible that two waves of intestinal T-cell development occur: one early in ontogeny that is extrathymic followed by a switch to primarily thymus-dependent development. Another possibility is that extrathymic T-cell development is species specific or is only observed under certain experimental conditions, such as pathogen-free conditions, which are not possible to achieve in human studies. Although putative precursors expressing RAG and TdT have been isolated from intestinal lymphoid tissue from mice and humans, the critical missing link in the story is the identification of the site and the delineation of the temporal sequence of events leading to bona fide extrathymic T-cell generation.

The continued description of novel anatomic structures in the intestinal mucosa is perhaps surprising to anatomists and mucosal immunologists alike. It has been more than three centuries since the description by Peyer of his patches,[28] yet the structural definition of intestinal tissue continues. These findings are testaments to the meticulous care needed to perform detailed histological studies and to improved microscopic detection systems. Perhaps more importantly, the results are indicative of the complexity of a mucosal immune system that has been driven by millennia of evolutionary pressures. Continued analysis of the anatomy, development, and function of the mucosal immune system can only lead to better understanding of normal as well as disease processes.

LEO LEFRANÇOIS
LYNN PUDDINGTON
Division of Rheumatic Diseases
Department of Medicine
University of Connecticut Health Center
Farmington, Connecticut

References

1. Fichtelius KE. The gut epithelium—a first-level lymphoid organ? Exp Cell Res 1968;49:87–104.
2. Greibel PJ, Hein WR. Expanding the role of Peyer's patches in B-cell ontogeny. Immunol Today 1996;17:30–39.
3. Lefrançois L, Puddington L. Extrathymic intestinal T-cell development: virtual reality? Immunol Today 1995;16:16–21.
4. Du Pasquier L. Evolution of the immune system. In: Paul WE, ed. Fundamental Immunology. 3rd ed. New York: Raven, 1993:199–233.
5. Lefrançois L, Fuller B, Olson S, Puddington L. Development of intestinal intraepithelial lymphocytes. In: Kagnoff MF, Kiyono H, eds. Essentials of mucosal immunology. San Diego: Academic 1996:183–193.
6. Goodman T, Lefrançois L. Intraepithelial lymphocytes. Anatomical site, not T cell receptor form, dictates phenotype and function. J Exp Med 1989;170:1569–1581.
7. Lefrançois L, Olson S. Reconstitution of the extrathymic intestinal T cell compartment in the absence of irradiation. J Immunol 1997;159:538–541.
8. Lundqvist C, Baranov V, Hammarstrom S, Athlin L, Hammarstrom ML. Intra-epithelial lymphocytes. Evidence for regional specialization and extrathymic T cell maturation in the human gut epithelium. Int Immunol 1995;7:1473–1487.
9. Rocha B, Vassalli P, Guy-Grand D. Thymic and extrathymic origins of gut intraepithelial lymphocyte populations in mice. J Exp Med 1994;180:681–686.
10. Havran WL, Allison JP. Developmentally ordered appearance of thymocytes expressing different T-cell antigen receptors. Nature 1988;335:443–445.
11. Lefrançois L, Mayo J, Goodman T. Ontogeny of T cell receptor (TCR) α,β^+ and γ,δ^+ intraepithelial lymphocytes (IEL). In: Lotze MT, Finn OJ, eds. Cellular immunity and the immunotherapy of cancer. New York: Wiley–Liss, 1990:31–40.
12. Lefrançois L, LeCorre R, Mayo J, Bluestone JA, Goodman T. Extrathymic selection of $TCR\gamma/\delta^+$ T cells by class II major histocompatibility complex molecules. Cell 1990;63:333–340.

13. Guy-Grand D, Cerf-Bensussan N, Malissen B, Malassis-Seris M, Briottet C, Vassalli P. Two gut intraepithelial CD8+ lymphocyte populations with different T cell receptors: a role for the gut epithelium in T cell differentiation. J Exp Med 1991;173:471–481.
14. Bandeira A, Itohara S, Bonneville M, Burlen-Defranoux O, Mota-Santos T, Coutinho A, Tonegawa S. Extrathymic origin of intestinal intraepithelial lymphocytes bearing T-cell antigen receptor γδ. Proc Natl Acad Sci USA 1991;88:43–47.
15. Shinkai Y, Rathbun G, Lam K-P, Oltz EM, Stewart V, Mendelsohn M, Charron J, Datta M, Young F, Stall AM, Alt FW. RAG-2 deficient mice lack mature lymphocytes owing to inability to initiate V(D)J rearrangement. Cell 1992;68:855–867.
16. Mombaerts P, Iacomini J, Johnson RS, Herrup K, Tonegawa S, Papaioannou VE. RAG-1-deficient mice have no mature B and T lymphocytes. Cell 1992;68:869–877.
17. Di Santo JP, Rodewald H-R. In vivo roles of receptor tyrosine kinases and cytokine receptors in early thymocyte development. Curr Opin Immunol 1998;10:197–207.
18. Zijlstra M, Bix M, Simister NE, Loring JM, Raulet DH, Jaenisch R. β_2-Microglobulin deficient mice lack $CD4^-8^+$ cytolytic T cells. Nature 1990;344:742–746.
19. Fuller B, Lefrançois L. Requirement for extrathymic class I histocompatibility antigens for positive selection of thymus-derived T lymphocytes. J Immunol 1995;155:2808–2811.
20. Puddington L, Olson S, Lefrançois L. Interactions between stem cell factor and c-Kit are required for intestinal immune system homeostasis. Immunity 1994;1:733–739.
21. Watanabe M, Ueno Y, Yajima T, Iwao Y, Tsuchiya M, Ishikawa H, Aiso S, Hibi T, Ishii H. Interleukin 7 is produced by human intestinal epithelial cells and regulates the proliferation of intestinal mucosal lymphocytes. J Clin Invest 1995;95:2945–2953.
22. Moghaddami M, Cummins A, Mayrhofer G. Lymphocyte-filled villi: comparison with other lymphoid aggregations in the mucosa of the human small intestine. Gastroenterology 1998;115:1414–1425.
23. Mayrhofer G, Brooks A. Lymphopoiesis in lymphocyte-filled villi in the small intestine of the rat (abstr). Clin Immunol Immunopathol 1995;76:S55.
24. Latthe M, Terry L, Macdonald TT. High frequency of CD8αα homodimer-bearing T cells in human fetal intestine. Eur J Immunol 1994;24:1703–1705.
25. Macdonald TT, Spencer J. Ontogeny of the gut-associated lymphoid system in man. Acta Paediatr Suppl 1994;83:3–5.
26. Kanamori Y, Ishimaru K, Nanno M, Maki K, Ikuta K, Nariuchi H, Ishikawa H. Identification of novel lymphoid tissues in murine intestinal mucosa where clusters of c-kit+ IL-7R+ Thy1+ lymphohemopoietic progenitors develop. J Exp Med 1996;184:1449–1459.
27. Saito H, Kanayama Y, Takemori T, Nariuchi H, Kubota E, Takahashi-Iwanaga H, Iwanaga T, Ishikawa H. Generation of intestinal T cells from progenitors residing in gut cryptopatches. Science 1998;280:275–278.
28. Peyer JC. Excercitatio Anatomico-Medica de Glandulis Intestinorum, Schaffhausen 1677.

Address requests for reprints to: Leo Lefrançois, Ph.D., Division of Rheumatic Diseases, Department of Medicine, University of Connecticut Health Center, Farmington, Connecticut 06030. e-mail: llefranc@panda.uchc.edu; fax: (860) 679-1287

© 1998 by the American Gastroenterological Association

0016-5085/98/$3.00

Stenting the Pancreas: Is This the Solution to Post-ERCP Pancreatitis?

See article on page 1518.

Pancreatitis is the primary complication after diagnostic or therapeutic endoscopic retrograde cholangiopancreatography (ERCP). This dilemma has plagued endoscopists and a sizable minority of their patients since inception of ERCP techniques. A substantially higher incidence of pancreatitis accompanies ERCP manometry and endoscopic treatment of patients with sphincter of Oddi (SO) dysfunction (SOD).[1] Although a number of innovative treatments have been tried in attempts to reduce or eliminate post-ERCP pancreatitis, only prolonged infusion of a costly potent protease inhibitor has shown success.[2]

In this month's GASTROENTEROLOGY, Tarnasky et al.[3] report their success in significantly lowering the incidence of post-ERCP pancreatitis by stenting the pancreatic duct after biliary sphincterotomy in a select group of patients with SOD and pancreatic sphincter hypertension (PSH). This prospective randomized, controlled trial by the South Carolina group resulted in reduction of the risk of pancreatitis after ERCP, biliary sphincterotomy, and SO manometry from 26% (no stent group) to 7% (stent group). Based on these results, Tarnasky et al. recommend consideration of pancreatic duct stent placement when SOD and PSH are present and biliary sphincterotomy is performed.

Although the investigators emphasize that pancreatic stenting was performed on a carefully selected group of patients, this report will spark renewed interest and debate concerning pancreatic stenting as a method of reducing post-ERCP pancreatitis. Additionally, this study raises several important issues relating to both postprocedural and recurrent pancreatitis and pancreaticobiliary pain, i.e., the efficacy and safety of pancreatic stenting